

PDF hosted at the Radboud Repository of the Radboud University Nijmegen

The following full text is a publisher's version.

For additional information about this publication click this link.

<http://hdl.handle.net/2066/162522>

Please be advised that this information was generated on 2021-12-13 and may be subject to change.



CHRONIC CENTRAL SEROUS CHORIORETINOPATHY

STUDIES ON THE CLINICAL AND
GENETIC CHARACTERISTICS

Myrte B. Breukink

Chronic central serous chorioretinopathy

Studies on the clinical and genetic characteristics

Myrte B. Breukink

Research described in this thesis was funded by Macula Vision Research Foundation, Landelijke Stichting voor Blinden en Slechtienden, MD Fonds, Oogfonds, JANIVO Stichting, Stichting Nederlands Oogheelkundig Onderzoek, and the Gelderse Blindenstichting.

Financial contribution to the publication of this thesis from Radboud University Nijmegen, Alcon, Allergan, Ursapharm, Santen Pharmaceutical Co., ZEISS, Rockmed, Chipsoft B.V., Théa Pharma B.V., Landelijke Stichting voor Blinden en Slechtienden, Stichting Leids Oogheelkundig Ondersteuningsfonds, Stichting Blindenhulp, HJ Breukink Holding B.V., Lameris Ootech BV, Bayer, Rotterdamse Stichting Blindenbelangen and Novartis is gratefully acknowledged.

None of the above-mentioned organizations or companies could influence or bias the content of this thesis.

Cover image: The central image is a fluorescein angiography of a patient suffering from chronic central serous chorioretinopathy. The overlay represents the contour map of the subretinal fluid accumulation.

Copyright © 2016, M.B.Breukink, Nijmegen, the Netherlands

Design: ProefschriftOntwerp.nl

Cover art: ProefschriftOntwerp.nl

Printed by: Gilde Print

ISBN: 978-94-6233-472-4

No part of this thesis may be reproduced in any form without written permission from the author.

Chronic central serous chorioretinopathy

Studies on the clinical and genetic characteristics

Proefschrift

ter verkrijging van de graad van doctor

aan de Radboud Universiteit Nijmegen

op gezag van de rector magnificus prof. dr. J.H.J.M. van Krieken,

volgens besluit van het college van decanen

in het openbaar te verdedigen op vrijdag 27 januari 2017

om 10.30 uur precies

door

Myrte Bernke Breukink

geboren op 1 januari 1986

te Enschede

Promotoren: Prof. dr. C.B. Hoyng
Prof. dr. J.E.E. Keunen

Copromotoren: Prof. dr. C.J.F. Boon
Prof. dr. A.I. den Hollander

Manuscriptcommissie: Prof. dr. C.J.J. Tack (voorzitter)
Prof. dr. G.S.E.Fernández
Dr. S. Yzer (Het Oogziekenhuis Rotterdam)

Het is niet nodig te hopen om te ondernemen, noch te slagen om te volharden
(Willem van Oranje)

Contents

Chapter 1:	General introduction	p. 10-53
Chapter 2:	Genetic studies in chronic central serous chorioretinopathy	p. 54-93
2.1	Chronic central serous chorioretinopathy is associated with genetic variants implicated in age-related macular degeneration <i>Ophthalmology. 2015;122(3):562-70</i>	p. 54-77
2.2	Genomic copy number variations of the complement component C4B Gene are associated with chronic central serous chorioretinopathy <i>Invest Ophthalmol Vis Sci. 2015;56(9):5608-13</i>	p. 78-93
Chapter 3:	Clinical characteristics of chronic central serous chorioretinopathy	p. 94-145
3.1	Chronic central serous chorioretinopathy: follow-up and vision-related quality of life <i>Clinical Ophthalmology; accepted</i>	p. 94-109
3.2	Correlations between SD-OCT characteristics and response to half-dose photodynamic therapy in chronic central serous chorioretinopathy <i>Manuscript in preparation</i>	p. 110-123
3.3	OCT angiography compared to fluorescein and indocyanine green angiography in chronic central serous chorioretinopathy <i>Invest Ophthalmol Vis Sci. 2015;56(9):5229-37</i>	p.124-145


Chapter 4: Studies on the treatment of chronic central serous chorioretinopathy	p. 146-231
4.1 Half-dose photodynamic therapy followed by diode micropulse laser therapy as treatment for chronic central serous chorioretinopathy: evaluation of a prospective treatment protocol. <i>Acta Ophthalmol. 2016;94(2):187-97</i>	p. 146-171
4.2 Efficacy of photodynamic therapy in steroid-associated chronic central serous chorioretinopathy: a case-control study <i>Acta Ophthalmol. 2016;94(6):565-72</i>	p. 172-191
4.3 Half-dose photodynamic therapy followed by diode micropulse laser therapy as treatment for chronic central serous chorioretinopathy: evaluation of a prospective treatment protocol. <i>Trials. 2015;21;16:419</i>	p. 192-225
4.4 The use of eplerenone in therapy-resistant chronic central serous chorioretinopathy. <i>Acta Ophthalmol. 2014;92(6):e488-90</i>	p. 226-231
Chapter 5: General discussion	p. 232-257
Chapter 6: Summary / Samenvatting	p. 258-267
Chapter 7: Dankwoord	p. 268-275
Chapter 8: Curriculum vitae / List of publications	p. 276-281

List of abbreviations

ACTH	Adrenocorticotropic hormone	DRPE	Diffuse retinal pigment epitheliopathy
AE	Adverse event	EDI	Enhanced-depth imaging
AF	Autofluorescence	ETDRS	Early Treatment Diabetic Retinopathy Study
AMD	Age-related macular degeneration	EUGENDA	European Genetic Database
ANSM	Agence Nationale de Sécurité du Médicament et des Produits de Santé	F	Female
AP	Alternative complement pathway	FA	Fluorescein angiography
AR	Adverse reaction	FAF	Fundus autofluorescence
ARMS2	Age-related maculopathy susceptibility 2	FT-OCTA	Full thickness optical coherence tomography angiography
BCVA	Best-corrected visual acuity	GCN	Genomic copy number
C4	Complement component 4	GP	General practitioner
CCMO	Centrale commissie mensgebonden onderzoek	GR	Glucocorticoid receptor
cCSC	Chronic central serous chorioretinopathy	HF	Haplotype frequency
CFF	Color fundus photograph	HPA	Hypothalamic-pituitary-adrenal
CFH	<i>Complement factor H</i>	HSML	High-density subthreshold diode micropulse laser
CFT	Central foveal thickness	ICG	Indocyanine green
CHD	Coronary heart disease	ICGA	Indocyanine green angiography
CI	Confidence interval	IMP	Investigational medicinal product
CMO	Commissie mensgebonden onderzoek	JI	Jacard index
CNV	Choroidal neovascularisation	KI	Kurtosis
CRF	Case report form	LE	Left eye
CRT	Central retinal thickness	LMD	Leeftijdsgebonden maculadegeneratie
CSC	Central serous chorioretinopathy	Log MAR	Logarithm of the minimum angle of resolution
DMC	Data monitoring committee	M	Male
		MA	Minor allele
		MAF	Minor allele frequency
		MedI	Median intensity

MEK	Mitogen-activated protein kinase	SNP	Single nucleotide polymorphism
MHC	Major histocompatibility complex	SOP	Standard operating procedure
MI	Mean intensity	SRF	Subretinal fluid
MP	Micropulse laser therapy	SSADA	Split-spectrum amplitude decorrelation angiography
MR	Mineralcorticoid receptor	stdl	Standard deviation of the intensity
NEI-VFQ	National eye institute visual function questionnaire	SUSAR	Suspected unexpected serious adverse reaction
NRES	National Research Ethics Service	TV	Total volume
OCT	Optical coherence tomography	VA	Visual acuity
OCTA	Optical coherence tomography angiography	UK	United Kingdom
OR	Odds ratio	VEGF	Vascular endothelial growth factor
PCD	Posterior cystoid retinal degeneration		
PCV	Polypoidal choroidal vasculopathy		
PDT	Photodynamic therapy		
PI	Principal investigator		
RCCX	RP-C4-CYP21-TNX		
RE	Right eye		
REC	Research ethics committee		
ROI	Region-of-interest		
RPE	Retinal pigment epithelium		
SAE	Serious adverse event		
SAR	Serious adverse reaction		
SD	Standard deviation		
SD-OCT	Spectral domain optical coherence tomography		
SI	Skewness		
SLE	Systemic lupus erythematosus		





CHAPTER 1

General introduction

1.1 Anatomy of the human eye

Visual pathway

The reflectance of light on objects makes those objects visible to the human eye. Reflected light waves enter the eye through the cornea, followed by the anterior chamber, lens and the vitreous to be finally focussed on and absorbed by the photosensitive cells of the retina: the photoreceptors (**Figure 1**). From here a cascade of processes - the phototransduction cascade - is initiated, finally resulting in an electrical signal. This electrical signal is conducted by the optic nerve via the optic chiasm and further converted to an image in the visual cortex.

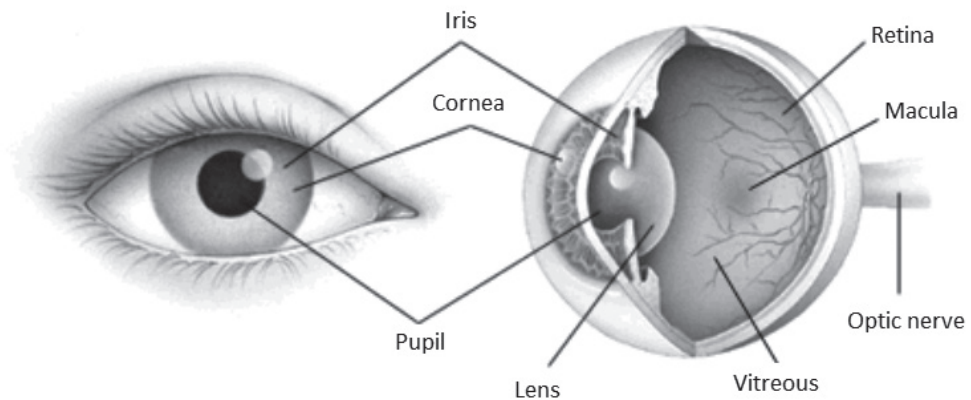


Figure 1.

Anatomy of the human eye (<http://www.eyesightresearch.org/background.htm>)

Retina

During embryonic development, the eyes can be first recognized as optic vesicles as early as the 25th post-ovulatory day.^{1,2} During further development the retina arises from the region of the neural tube.¹ The retina covers the inner lining of the eye, and is histologically composed of ten different cell layers (**Figure 2**).³

The inner seven layers of the retina are referred to as neuroretina. These transparent layers are linked to each other by synaptic connections between axons and dendrites, and to the ganglion cells that are also part of the neuroretina.⁴ Until recently, two different kinds of photoreceptors were differentiated in the neuroretina: cones and rods. More recent, the ganglion cells have been identified as a third photosensitive cell in the retina.³ The 100 million rods, that account for 95% of all photoreceptors, are responsible for vision at lower light intensities, and for sensing contrast. Rods are approximately 500 times more sensitive

to light than cones. The cones are responsible for detailed vision and colour perception at bright light conditions. Three classes of cones exist: red, green and blue. These are maximally sensitive to 561, 530 and 430 nm light respectively. In contrast to the rods, which are more densely found in the peripheral retina, the 5 million cones are mostly concentrated in the macula. The macula provides the central vision with the highest visual acuity and colour vision as a result of the highest cone density in the centre of the macula, the fovea.⁵

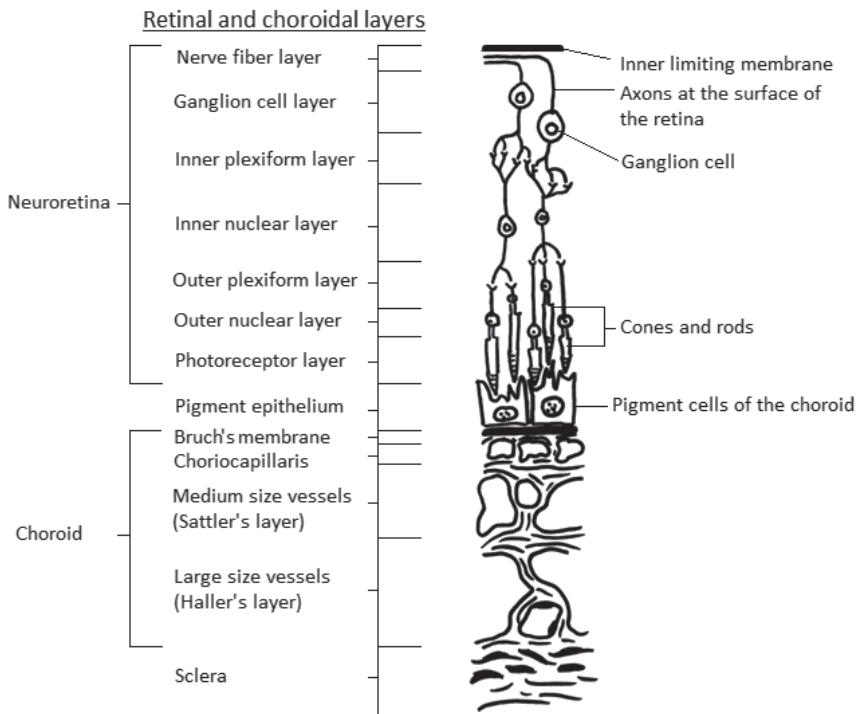


Figure 2.

Simplified schematic overview of the retinal and choroidal anatomy

The monolayer of retinal pigment epithelium (RPE) cells is the outermost part of the retina, located beneath the neuroretina. The RPE contains melanin granules that reduce the light scattering and block light absorption via the sclera, resulting in a better image received by the retina.¹ Tight junctions, complex structures that are dynamically regulated,⁶ between adjacent RPE cells form the outer blood-retinal barrier.^{1, 6} The RPE actively regulates the movement of solutes between the underlying permeable choriocapillaris and the overlying

photoreceptors.⁶ In addition, the RPE is involved in many other physiological processes, such as the phagocytosis of shed photoreceptor outer segments, the retinol metabolism (also known as the visual cycle), coordination of the immune response, and the maintenance of the extracellular matrix.^{1,7} Especially the phagocytosis and processing of the outer segment discs of the photoreceptors, that are subject to constant renewal and replacement, requires a high energy supply. To provide this energy, the avascular outer retina is dependent on the support provided by the adjacent choroid.⁸

Choroid

At birth the choroid is approximately $329 \pm 66 \mu\text{m}$ thick,⁹ but the mean choroidal thickness decreases gradually to about $80 \mu\text{m}$ by age 90.¹⁰ In addition, a correlation between the thickness of the choroid and the refractive error of eyes exists. Change in choroidal thickness can move the retina towards the plane of focus, therefore, it is thought that the choroid may play a role in the modulation of ocular elongation in response to defocus. In myopic individuals a thinner choroid, and in hyperopic individuals a thicker choroid is seen as compared to emmetropic individuals.¹¹ The choroid consists of blood vessels, melanocytes, fibroblasts, resident immune competent cells and supporting tissue. With the highest rate of blood flow of all body tissues, the primary function of the choroid is to supply oxygen and nutrition to the outer retina and to eliminate waste products. In addition, the choroid has at least 2 other functions: thermoregulation, and secretion of growth factors.¹¹

The choroid runs from the borders of the optic nerve up to the pars plana, where it becomes the ciliary body.¹¹

Histologically, five different choroidal layers can be distinguished. Starting with innermost structure, underlying the RPE, is the Bruch's membrane, followed by the choriocapillaris, two vascular layers, and the suprachoroid (**Figure 2**).¹¹

The Bruch's membrane is a thin ($2 \mu\text{m}$) layer that thickens slightly with age. This thin membrane is a pentalaminar structure consisting of the basement membrane of the RPE, an inner collagenous zone, an elastic layer, an outer collagenous zone, and the basement membrane of the choriocapillaris. Bruch's membrane is involved in the exchange of biomolecules, oxygen, nutrients and waste products between the RPE and choriocapillaris.¹² The age-related thickening of Bruch's membrane and built-up of material in the inner collagenous layer can result in a decreased permeability. In addition, changes in the integrity of Bruch's membrane have been found in individuals with age-related macular degeneration (AMD) as compared to controls.¹³ Underlying Bruch's membrane is the highly anastomosed network of capillaries of the choriocapillaris, forming a thin vascular sheet. The choriocapillary thickness is about $7 \mu\text{m}$ in the periphery and increases up to $10 \mu\text{m}$ at the foveal region, which harbours the greatest density of capillaries. The fenestrated capillaries are relatively

large in diameter (20-40 μm).¹⁴ Unlike the other choroidal vasculature, the choriocapillaris is fenestrated and therefore permeable.

Two additional vascular layers of the choroid are the inner layer (Sattler's layer) with medium and small arteries as well as arterioles that feed the capillary network, and an outer layer of larger blood vessels (Haller's layer).¹¹

The fifth and outermost layer of the choroid, the suprachoroid, forms the transitional zone between choroid and sclera. The suprachoroid contains collagen fibers, fibroblasts and melanocytes.

Similar to the retina, the composition of the choroid shows variability from the centre of the posterior pole towards the periphery. The maximal choroidal thickness is reached in the macula, and the choroid thins gradually towards the periphery. Simultaneously, the composition of the choriocapillary vasculature changes from a lobular pattern in the macular area, to a more ladder-like appearance in the periphery. This change in structure may also explain the difference in choroidal blood flow, being the highest beneath the macula, as the lobular structure provides a more efficient flow.

Blood-retinal barrier and subretinal space

During embryonic development, the central neuro-ectoderm of the optic vesicle invaginates to finally form the sensory retina (**Figure 3**). Due to this invagination the neuroretina and the RPE become apposed, being separated by a potential subretinal space which can fill with fluid resulting in a detachment of the neuroretina.¹⁵ The RPE is among the most metabolically active tissues in the human body, and plays an important role in controlling the chemical environment of this subretinal space.⁶

Similar to the blood-brain barrier, the retina is protected by a blood-retinal barrier with an inner and outer component. Both barriers consist of tight junctions, the inner barrier within the retinal blood vessels and the outer barrier being formed by the RPE layer. The blood-retinal barrier enables the highly selective diffusion of molecules and is essential for maintaining retinal homeostasis. Conditions of the surrounding tissue can influence autoregulation by local factors. For example, local autoregulation can be altered by changes in hydrostatic pressure, osmotic force, and capillary permeability, and in response to metabolic fluctuations. Interestingly, the choroidal circulation is strongly controlled by central sympathetic innervation, with little or no autoregulation, whereas the retinal circulation lacks sympathetic innervations and is dependent on autoregulation.⁸ In addition to forming the outer blood-retinal barrier the RPE provides active transport mechanisms, which maintain the finely balanced extracellular environment of the outer retina. Furthermore, the RPE possesses a pump function that actively dehydrates the subretinal space, thus maintaining the normal apposition of the neuroretina to the RPE. There is no firm attachment between the RPE and the photoreceptors. Therefore, the active pump function of the RPE is essential

to maintain this attachment. The retinal adhesive force across this subretinal space is energy-dependent and decreases within minutes in case of ischemia.^{8,16}

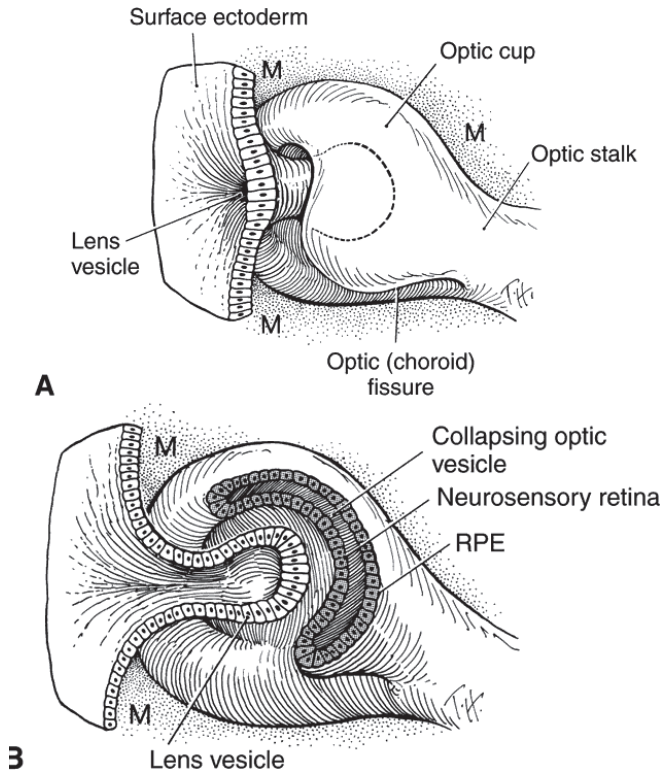


Figure 3.

Embryological development of the eye. Illustration of the invagination in the optic cup and stalk resulting in the formation of the subretinal space between the neurosensory retina and retinal pigment epithelium (RPE). (<http://www.oculist.net/downat0502/prof/ebook/duanes/pages/v7/v7c002.html#len>)

1.2 Retinal imaging

Fluorescein angiography (FA) uses sodium fluorescein dye which can be given either intravenously or orally. The dye is transported by the bloodstream and consequently fills all vessels, including those of the retina. Light waves with a stimulating wavelength for sodium fluorescein (490 nm) are used to visualize the dye. In healthy eyes, the sodium fluorescein dye that diffuses from the large fenestrated choriocapillaris cannot pass the outer blood-retinal barrier which is formed by tight junctions between RPE cells, and also remains inside the retinal blood vessels which form an inner blood-retinal barrier (**Figure 4A**).²

Indocyanine green angiography (ICGA) is another dye-enhanced imaging technique, using relatively large ICG molecules of which 95% bind to blood albumin after intravenous injection. The ICG molecule normally does not pass the outer blood-retinal barrier due to its large molecular size and due to its lipophilic and hydrophilic properties it easily binds to proteins. It was thought that this protein-binding capacity limits the travel of ICG within the choroid vessel wall. However, it has been demonstrated that ICG diffuses through the choroidal stroma during angiography and accumulates within the RPE.¹ In contrast to FA, ICGA uses a wavelength of 790-805 nm that penetrates the RPE,¹ enabling imaging of the deeper choroidal vasculature (**Figure 4B**).

Fundus autofluorescence (FAF) imaging provides non-invasive images by capturing the emission of light from endogenous fluorophores, after stimulation with 488 nm wavelength light.¹⁷ The phagocytosis and processing of outer photoreceptor segments through lysosome-derived organelles by the RPE results in degradation products. These products, that are stored and referred to as lipofuscin granules, are composed partially of bisretinoids, which have broad fluorescence absorption and emission spectra that can be detected by FAF. Lipofuscin accumulation is associated with increasing age, but is also found in various patterns in both acquired and inherited degenerative disease of the retina (**Figure 4C**).^{18, 19}

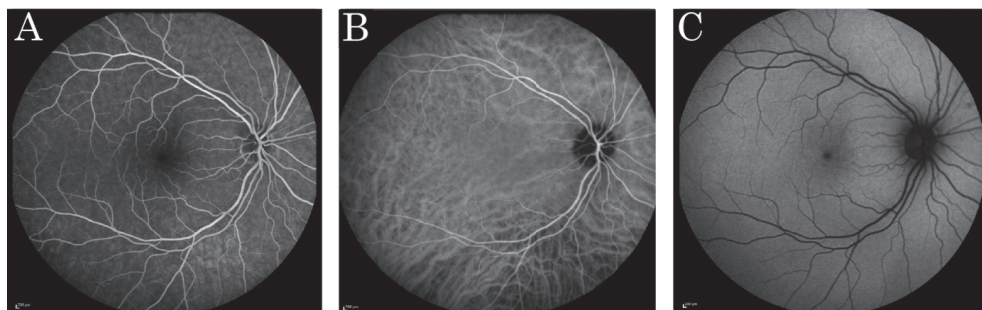


Figure 4.

Examples of fluorescein angiography (A), indocyanine green angiography (B) and fundus autofluorescence (C) images of the retina of the right eye in a healthy individual.

Optical coherence tomography (OCT) is a non-invasive imaging technique that can provide high-resolution, cross-sectional images of the retina, retinal nerve fibre layer and the optic nerve head using low-coherence reflectometry.²⁰ In low-coherence reflectometry, the coherence property of light reflected from a sample provides information on the time-to-flight delay from the reflective boundaries and backscattering internal microstructures in the eye.²¹ Multiple longitudinal scans are made, and the information gathered is used to create a two- or three-dimensional image (**Figure 5**).

Enhanced-depth imaging (EDI) and swept-source OCT imaging enable a better visualisation of the choroid. In EDI imaging the objective lens of the OCT-device is positioned closer to the eye, thereby approximating the choroid to the zero-delay line (the area where the resolution of the OCT is known to be sharpest). Consequently, more detailed images of the choroid can be obtained. The second method uses a higher scanning speed based on the swept-source technology. In addition, a longer wavelength is introduced that aids in preventing scattering by the RPE, resulting in a deeper penetration into the choroid (**Figure 5**).²²⁻²⁴

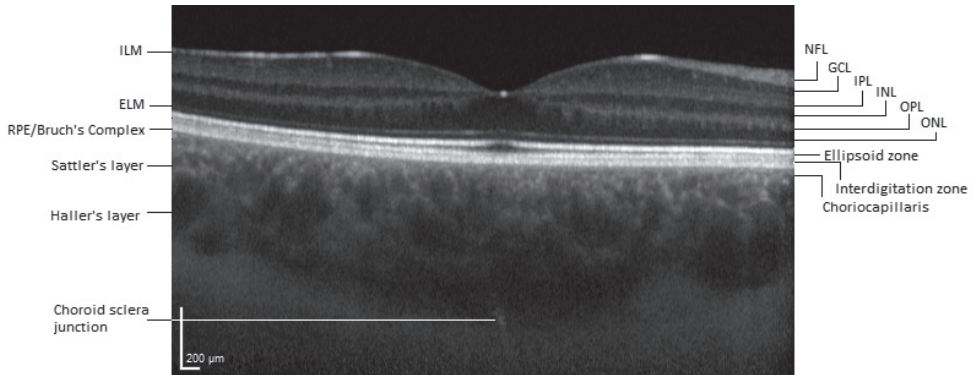


Figure 5.

Enhanced-depth optical coherence tomography of a right eye of a healthy individual illustrating the different layers of the retina and choroid.

ELM: External limiting membrane, GCL: Ganglion cell layer, ILM: Internal limiting membrane, INL: Internal nuclear layer, IPL: Inner plexiform layer, NFL: Nerve fibre layer, ONL: Outer nuclear layer, OPL: Outer plexiform layer, RPE: Retinal pigment epithelium.

Optical coherence tomography angiography (OCTA) is a novel non-invasive technique that uses motion contrast to visualize capillary blood flow, but without determination of the flow direction.²⁵ Stationary tissue produces a nearly constant reflection or scattering whereas moving tissue produces OCT signals that change over time.²⁶ OCTA is based on the oversimplified assumption that the only movement in the retina is the blood flow. Repeated scanning of the same region of tissue enables a comparison of OCT-pixels between different time points. Those pixels that show changes are displayed brightly, whereas pixels from areas with little or no change are displayed as black. For detection of motion contrast many different algorithms and/or methods exist. In addition, there are different statistical methods to assess changes. Essentially, all of these techniques use the detection of motion to visualize the retinal vasculature.²⁶ As a result, OCTA is able to visualize the inner vascular plexus, the deep retinal vascular plexus, and the choriocapillaris separately (**Figure 6**).

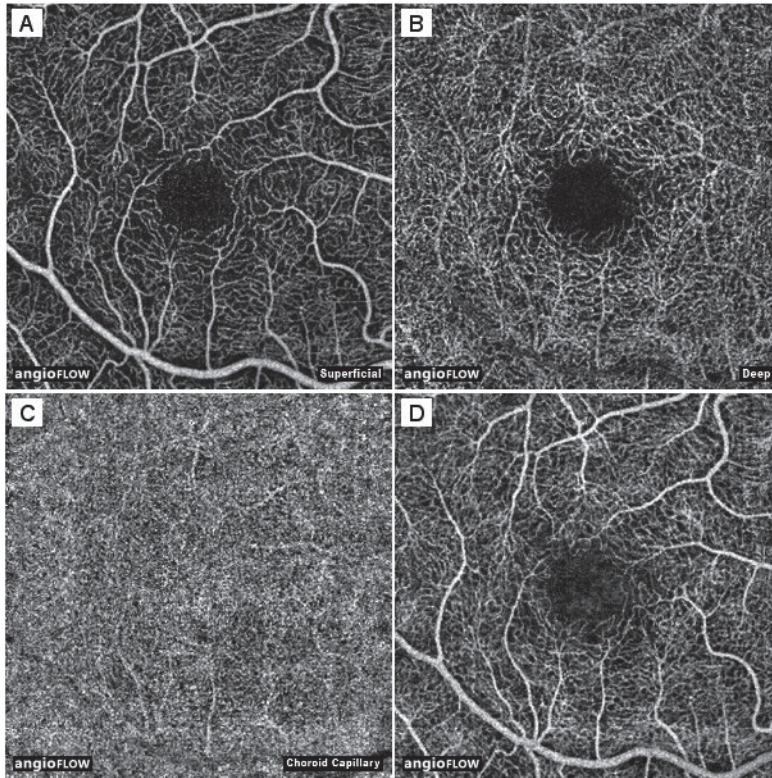


Figure 6.

Optical coherence tomography (OCT) angiography of a right eye of a healthy subject (25-year-old female). **(A)** The inner (“superficial”) vascular plexus. **(B)** The deep retinal vascular plexus. **(C)** The choriocapillaris. **(D)** Full-thickness OCT angiogram, a superposition of all previous layers.

1.3 Central serous chorioretinopathy

Central serous chorioretinopathy (CSC) was first described in 1866 by the German ophthalmologist Von Graefe.²⁷ Due to the diagnostic limitations, only limited phenotypical features of the disease could be noted and documented at that time. Therefore, Von Graefe was convinced of CSC being a retinal disturbance and described the pathology as ‘relapsing central luetic retinitis’.²⁷ Other names for CSC in the earlier 20th century have included terms such as ‘capillarospastic central retinitis’ and ‘central angiospastic retinopathy’, illustrating the belief that vasospasm was underlying the pathophysiological mechanism.²⁸ It took over 100 years after Von Graefe’s first description before Maumenee described FA findings in CSC, and discovered that the detachment of the macula resulted from leakage at the level of the RPE.²⁹ The nomenclature at that time had already changed to ‘central serous retinopathy’. Gass introduced the term ‘idiopathic central serous choroidopathy’, which over time has been adjusted to ‘central serous chorioretinopathy’ based on the observation that underlying choroidal hyperpermeability is an important feature of CSC that ultimately affects the integrity of the RPE outer blood-retinal barrier, eventually causing a serous neuroretinal detachment.^{30, 31} This forms the basis of the current ideas concerning the etiology and definition of CSC.³²

CSC is an eye disease that generally only becomes symptomatic when it affects the central part of the retina. It is thought that especially the central part of the eye is more vulnerable to the disease, due to the different lobular structure and accompanying higher flow rate of the underlying choroid as compared to the peripheral area.³³ With an estimated annual incidence of at least 9.9 cases per 100.000 men and 1.7 per 100.000 women,³⁴ CSC is considered the fourth most common macular disease.³⁵ Men are more frequently affected than women, with reported male-to-female ratios up to approximately 8:1,³¹ and the age at onset can range from 30 to 80 years.³⁶

Various risk factors have been described in CSC, of which the use of corticosteroids is the most prominent, with described odds ratios of up to 37 (**Table 1**).³⁷ All forms of corticosteroid treatment have been described in association with CSC, ranging from systemic administration,³⁸ nasal spray,³⁷ eye drops,³⁹ skin cream,⁴⁰ inhalers,⁴¹ or illegal corticosteroid injection for professional body building.^{37, 40} In addition to exogenous corticosteroids, elevated levels of endogenous corticosteroids, as in patients with Cushing’s disease,⁴²⁻⁴⁴ have also been described as risk factors for CSC.⁴⁵

Other potential risk factors that have been reported are cardiovascular disease and hypertension, type A personality,⁴⁶ pregnancy,^{47, 48} stress,⁴⁹ the use of sildenafil,⁵⁰ and infection with *Helicobacter pylori*.⁵¹

Furthermore, a hereditary predisposition may exist for CSC. Familial occurrence has been described, and racial differences in prevalence have been reported.^{52, 53} Relatively high rates

of CSC are seen in the Caucasian and Hispanic population, and even higher rates have been reported in the Asian population, whereas the incidence appears to be lower in African Americans. Recent studies have shown significant differences in the genetic profile of patients with chronic CSC as compared to healthy controls.^{54, 55}

Table 1. Overview of reported risk factors for central serous chorioretinopathy

Genetic predisposition	Familial occurrence ^{52, 53}	
	<i>Complement factor H</i> gene ^{54, 56} <i>Cadherin 5</i> gene ⁵⁵	Asian and Greek population Significant in males
Cardiovascular disease	Hypertension ⁵⁷	OR: 2.25
	Coronary hearts disease (CHD) ⁵⁸	HR: 1.72
	Ischemic stroke ⁵⁹	HR: 1.56; 95% CI, 1.11-2.18
	Organic and psychogenic erectile dysfunction ⁶⁰	HR: 2.14; 95% CI, 1.34-3.44
Corticosteroids	Systemic ^{37, 44, 57}	
	Ocular ⁶¹	
	Topical dermal ^{62, 63}	
	Intranasal ^{64, 65} Intra-articular ^{66, 67}	
Endocrine changes	Pregnancy ³⁷	OR: 7.1; 95% CI, 1.0-50.7
	Cushing's disease ^{68, 69}	
Psychopathology	Type A personality ⁷⁰	
	Stress ⁵⁷	OR: 2.6; 95% CI, 1.33-9.23
Gastro-esophageal disorders	Gastro-esophageal reflux ⁷¹	OR: 6.05; 95% CI, 2.14-17.11
	Peptic ulcer ⁵⁸	OR: 1.39; 95%CI, 1.14-1.70 (Taiwan)
	<i>Helicobacter pylori</i> infection ⁷²	Elevated incidence in CSC
Drug-induced	Adrenergic receptor antagonists ^{73, 74}	
	Phosphodiesterase-5 inhibitors ^{50, 75}	
Sleep disturbances	Obstructive sleep apnea ⁷⁶	Elevated incidence in CSC

CI: Confidence interval, HR: Hazard ratio, OR: Odds ratio

Acute versus chronic central serous chorioretinopathy

Two main subtypes of CSC can be distinguished: acute CSC and chronic CSC. A strict delineation between these subtypes can be difficult. In general, two main definitions have been proposed to differentiate acute CSC from chronic CSC.

The first definition is purely based on the period of time during which subretinal fluid (SRF) is present. If the SRF resolves spontaneously within a few (generally 2-4) months,⁷⁷ one can speak of acute CSC. In case the SRF is still present after 2-4 months (some authors propose 6 months) the nomenclature used arbitrarily changes to chronic CSC.^{35, 78, 79}

However, this thesis adheres to literature that differentiates acute and chronic CSC not only based on the duration of the disease, but chiefly based on distinctive phenotypical characteristics that indicate chronicity. These phenotypical characteristics, which are discussed below, can be identified with multimodal imaging techniques.

Acute CSC

Patients suffering from acute CSC most commonly present with a sudden onset of central vision loss.⁸⁰ Symptoms are usually confined to the central visual field, with or without a decline in best-corrected visual acuity. As a result of leakage of SRF in CSC, complaints such as metamorphopsia,⁸¹ micropsia and hypermetropisation may occur. In addition, patients can experience a relative scotoma, dyschromatopsia,⁸² and reduced contrast sensitivity.³⁵ The male predisposition appears to be more prominent in acute CSC, and the age at onset usually ranges from 25-60 years.³⁶

In acute CSC it is believed that a sudden focal disruption of the RPE leads to high-flow leakage beneath the overlying neurosensory retina. This focal leakage can be confirmed by FA imaging, which in some cases shows the typical sign of acute CSC, the smoke-stack leakage phenomenon (**Figure 7I-J**).³⁵ ICGA reveals focal or sometimes more extensive alterations of the choroidal vasculature throughout the different angiographic phases (**Figure 7F**). During the early phase of ICGA, a delay in the filling of the choriocapillaris located at the sites of leakage, results in hypofluorescent areas.^{83, 84} Midphase ICGA shows dilation of the large choroidal vessels, and choroidal vascular hyperpermeability as evidenced by typical hyperfluorescent areas with blurred contours (**Figure 7D**).⁸⁵⁻⁸⁷ Punctate hyperfluorescent spots can also be seen in mid- and late-phase ICGA, in the macular area, outside the vascular arcade, or around the optic disc. These punctate spots seem to be located in the inner choroid, and often appear as clusters of small distinct spots. These hyperfluorescent spots on ICGA are present in 95% of eyes affected with CSC and 78% in unaffected fellow eyes.⁸⁸ Late-phase ICGA is characterized by either persistence of hyperfluorescence, as seen in the midphase, wash-out of ICG dye, or centrifugal displacement of hyperfluorescence, forming hyperfluorescent rings.^{36, 88} OCT in acute CSC shows the SRF accumulation in the macula, causing a neuroretinal detachment. OCT can also visualize RPE abnormalities such as associated RPE detachments.⁸⁹⁻⁹¹

An overlap may exist between the location of the RPE detachment and the areas of dilated, large choroidal vessels and thickened choroid on OCT, and with hyperfluorescent area(s) of vascular hyperpermeability on ICGA.^{91, 92}

In inactive disease, after the SRF is completely reabsorbed, the retinal anatomy often remains slightly abnormal. These abnormalities can range from very mild RPE changes or photoreceptor irregularities, to retinal atrophy. After resolution of SRF, with or without treatment, many patients with acute CSC show a gradual restoration of outer retinal structures on OCT, mostly on the outer photoreceptor level such as the external limiting membrane, ellipsoid, and the RPE. CSC patients typically have a thicker choroid as compared to healthy controls.^{91, 93-95} Such a thickened choroid is not only seen in eyes with active SRF leakage, but also in fellow eyes without SRF leakage.^{96, 97} In addition, an abnormally thin choriocapillary layer can be found in CSC patients on EDI-OCT.⁹¹

Patients with acute CSC can show a spectrum of FAF abnormalities (**Figure 7B**). Typical early FAF findings in acute CSC consist of diffuse hypo-autofluorescent areas that often correspond with the leakage points as seen on FA, and hypo-autofluorescence corresponding to the areas of SRF accumulation possibly by blockage of RPE autofluorescence by the overlying SRF.⁹⁸ After resolution of the episode of acute CSC, hypofluorescence with significant granular appearance corresponding to the areas of former retinal detachment can be observed.⁹⁸

Chronic CSC

In contrast to acute CSC, chronic CSC patients often present at an older age, with a disease onset that is generally experienced as less sudden.⁹⁹ Bilateral disease is more common in chronic CSC as compared to acute CSC.⁹⁹ A history of acute CSC and/or an episode of acute vision loss compatible with acute CSC is present in only approximately 16% of chronic CSC patients.^{35, 77, 99} This indicates that there may be a pathogenetic distinction between acute and chronic CSC, although they may be similar disease expressions within a spectrum of CSC.

Abnormalities on FA and ICGA resemble those of acute CSC but are often more extensive in chronic CSC. In addition, more diffuse and sometimes multifocal leakage can be seen on FA and ICGA, with irregularly distributed and more or less widespread RPE changes associated with varying degrees of low-grade leakage (**Figure 7K-L**).^{28, 35, 77-79, 99-103} In longstanding chronic CSC, a 'gravitational tract' can be seen on funduscopy, fundus autofluorescence, and fluorescein angiography (**Figure 7M**). This area of RPE atrophy from the macula is considered to be the result of prolonged subretinal fluid accumulation extending inferiorly as a result of gravity.⁹⁹ Abnormalities on ICGA in chronic CSC consist of more widespread, hyperfluorescent areas of hyperpermeability of the choroidal vasculature and congestion as compared to acute CSC (**Figure 7D & 7L**).^{35, 79, 83, 86, 88, 104} Besides choroidal leakage, choroidal venous dilation can also be seen. In active disease punctate hyperfluorescent spots, that appear to arise from the inner choroid/choriocapillaris, have been detected during mid- and late phase ICGA. These hyperfluorescent spots are

associated with increased choroidal thickness and may be a manifestation of the increased choroidal hyperpermeability and intrachoroidal hydrostatic pressure^{36, 88, 105} Interestingly, additional focal and diffuse areas of ICG hyperfluorescence are often found in areas that appear unaffected on FA.^{79, 104} The observation that choroidal changes on ICGA and EDI-OCT are often more extensive than retinal changes on FA and OCT may indicate that the primary inciting abnormality in CSC is situated in the choroid, which is discussed further in the next section (*1.4 Pathogenesis*).

The SRF on OCT in chronic CSC is often more shallow as compared to acute CSC. In contrast to acute CSC the SRF tends to persist in chronic CSC, although it can wax and wane multiple times.^{28, 102, 103} Outer retinal changes are seen in longstanding neuroretinal detachments, and are thought to be abnormal outer segments of the photoreceptor layer. Due to the lack of apposition between the photoreceptors and the RPE, the photoreceptor outer segments cannot be properly phagocytosed. It is thought that these accumulating outer segments, which eventually contain precursors of the toxic hyperautofluorescent fluorophore N-retinylidene-N-retinylethanolamine, can gravitate downwards within the pocket of SRF accumulation.^{89, 106} These autofluorescent waste products in the subretinal space and RPE can be clearly seen on FAF (**Figure 7J & 7M**), also after resolution of the SRF. RPE detachments are invariably present in chronic CSC.³⁶ In addition to more extensive RPE and outer photoreceptor abnormalities, variable degrees of photoreceptor and RPE atrophy can be present in longstanding chronic CSC. Also, intraretinal edema known as 'posterior cystoid degeneration' can be seen on OCT in longstanding chronic CSC, which can be difficult to distinguish from beginning choroidal neovascularisation (**Figure 7P**).^{107, 108} FAF in chronic CSC shows variably-shaped areas of speckled hyperautofluorescent and hypoautofluorescent spots (**Figure 7J**). These granules correspond to hyper-reflectivity at the outer photoreceptor layer and the RPE as confirmed on OCT.^{18, 98} A 'descending tract' is also frequently seen on FAF as a result of atrophic RPE changes due to prolonged SRF leakage that gravitates downward (**Figure 7M**).¹⁰⁹ In addition, RPE atrophy can be seen characterised by a decreased autofluorescence.¹⁰⁹⁻¹¹¹ Generally, it is thought that the autofluorescence mainly arises from the lipofuscin in the RPE.^{18, 112} However, in CSC the hyperautofluorescent dots within the SRF pocket in active CSC may at least partly correspond to macrophages engorged with phagocytosed outer segments.¹⁸ This would be in accordance with the findings as seen on OCT.

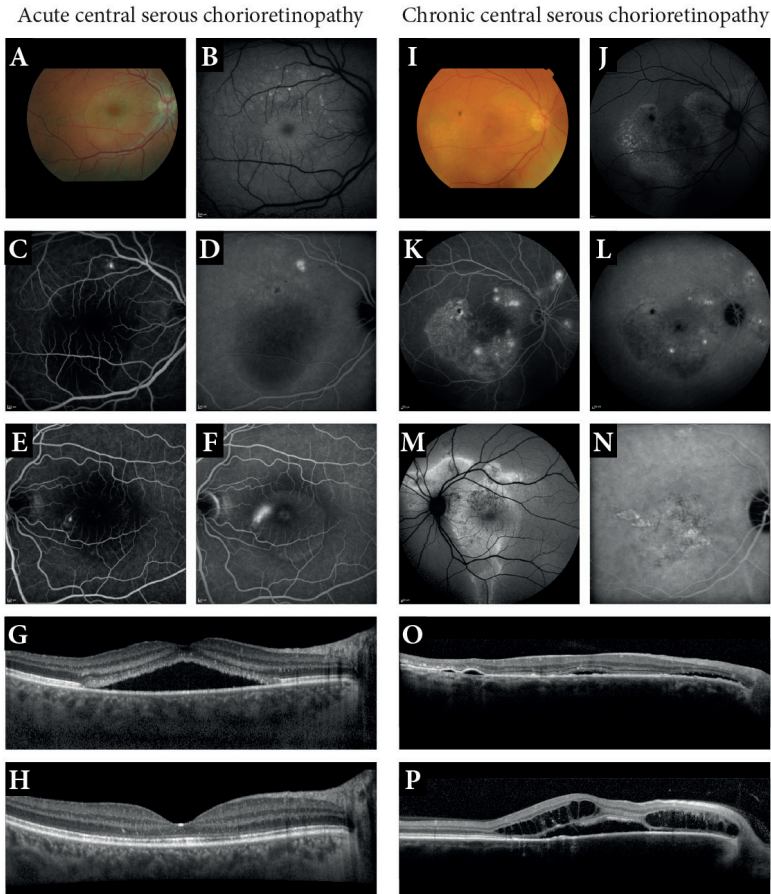


Figure 7.

(A-P) An overview of clinical characteristics that can be seen in acute (A-H) and chronic (I-P) central serous chorioretinopathy (CSC). (A-D) The right eye of a 46-year old man with acute CSC. (A) Color fundus photograph (CFF) showing a well-demarcated round subretinal fluid (SRF) collection in the macula. (B) Fundus autofluorescence (FAF) with hyperfluorescent spots along the superior vascular arcade, and very mild hypofluorescence at the side of the SRF pocket (white arrow). (C) Fluorescein angiography (FA) with a single hyperfluorescent ‘hot spot’ of leakage at the level of the retinal pigment epithelium (RPE). (D) Indocyanine green angiography (ICGA) showing a larger hyperfluorescent spot as compared to FA. Also, central blockage of background fluorescence below the SRF pocket is seen. (E-F) An example of an early FA image with a single hot spot (E) that develops to a classical ‘smoke stack’ appearance (F) in the later phase of FA. (G) Dome-shaped SRF accumulation on optical coherence tomography (OCT) during the active phase of an acute CSC patient. (H) Complete spontaneous resolution of SRF on OCT in the same patient. (I-L) The right eye of a 63-year old man with chronic CSC. (I) CFF with several areas of depigmentation of the retina, and a hyperpigmentation temporal superior of the fovea. (J) FAF showing a pattern of mottled hyper- and hypopigmentation. (K) Multiple hyperfluorescent ‘hot spots’ as well as diffuse leakage on FA, corresponding to diffuse hyperfluorescence and partial hypofluorescence on ICGA (L). A classic gravitational tract with hyper- and hypofluorescence on FAF (M). An example of ICGA (N) showing small punctiform hyperfluorescent areas in addition to diffuse hyperfluorescence. (O) OCT shows a shallow SRF accumulation and typical RPE detachments that can be seen in most chronic CSC cases. (P) OCT shows not only serous SRF, but also central posterior cystoid degeneration, indicative of long-standing disease.

1.4 Pathogenesis of central serous chorioretinopathy

The precise pathophysiological mechanisms of CSC are still largely unclear. Based on studies investigating the clinical characteristics in CSC with multimodal imaging, several theories have been proposed the past decades. Most of these theories are closely related and show an overlap that includes the choroid and the RPE as primarily abnormal structures, with a possible role for hormonal receptors and pathways.²⁸

Before the idea of choroidal involvement was introduced, the RPE was considered to be the primarily abnormal structure in CSC. The lesions that are seen on FA correspond to a disruption on the level of the RPE. The monolayer of RPE has an active pump function that regulates the transport of fluid and solutes from the retina to the choriocapillaris. It is thought that an impairment in the pump function of the RPE could result in a reverse fluid movement, causing an accumulation of SRF.

Gass suggested that a focal increase in the permeability of the choriocapillaris is a pivotal and possibly primary event in the pathogenesis of CSC.^{30, 101} This hypothesis is supported by findings on OCT and ICGA. Multimodal imaging has not only shown a thickened choroid on EDI-OCT, but also extensive abnormalities of the choroid on ICGA clearly indicating choroidal involvement.^{83, 87} It is postulated that alterations in the choroidal circulation may result in ischemia.^{101, 113}

Hyperpermeable choroidal vessels are thought to cause an increased hydrostatic pressure.^{28, 36} This increase in choroidal hydrostatic pressure induces stress to the overlying RPE cells, which promotes the development of RPE detachments.²⁸ Smaller or larger RPE detachments are seen in at least 45% of the patients with active CSC.³⁵ When the RPE outer blood-retinal barrier is damaged and a small rupture in the RPE develops, the hydrostatic pressure from the choroid results in the typical leakage into the subretinal space.

Interestingly, studies have shown that choroidal abnormalities are not only found in the affected eyes, but are also often seen in the fellow eyes that seem unaffected by SRF leakage.^{96, 97} Furthermore, the clinical observation that the size of the leakage area and extent of hyperfluorescent abnormalities are often more pronounced on ICGA as compared to FA imaging, suggests an important and primary role for the choroid in CSC. Not only an increase in choroidal hyperpermeability may be found, but alterations in the choroidal circulation may also cause choroidal ischaemia.^{28, 101}

Therefore a combination of the choroidal and RPE dysfunction causing active SRF leakage in CSC may actually be the most plausible explanation, in which the increased hydrostatic pressure from the choroid overwhelms the RPE and results in a SRF accumulation through a dysfunctional outer blood-retinal barrier. It is possible that the RPE in these patients is more vulnerable and more easily damaged by the underlying choroidal abnormalities, resulting in further dysfunction.

Similar to the choroidal abnormalities, abnormalities of the RPE are not only seen in the symptomatic CSC eyes, but also in the fellow eyes.¹¹⁴ It is therefore possible that such changes of the RPE are rather early/subclinical signs of eyes at risk of active CSC than late sequelae of previous CSC. However, the question remains why changes appear to occur primarily in the choroid. A possible explanation may lie within the regulatory mechanisms of the choroid. Tittl et al. found that CSC patients may have an impaired subfoveal choroidal blood flow regulation in response to exercise that induces a considerable stimulation of the parasympathetic and sympathetic nervous system.¹¹⁵ This abnormal choroidal blood flow regulation may be an important pathogenetic factor, since abnormal sympathetic activity of the autonomic nervous system is compatible with the association of CSC and stress.¹¹⁵

Finally, there are strong indications that there is an important role for hormonal factors in CSC pathogenesis. Two of the strongest associations reported thus far in CSC are the use of corticosteroids and male gender.^{37, 49} Interestingly, both risk factors exert physiological effects at the level of the hypothalamic-pituitary-adrenal axis (HPA-axis). The interconnected nature of the HPA-axis and the autonomic nervous system suggests a number of possible explanations involving influences on the choroid, Bruch's membrane, and the RPE.²⁸ Various relatively small studies have studied cortisol levels in chronic CSC patients. Although 24h urine samples showed elevated cortisol levels in chronic CSC patients in certain studies,^{116, 117} these results were not observed in single serum measurements during set times in other studies.^{118, 119} These discrepancies could be explained by variable cortisol fluctuations between individuals during the day, and therefore changes in endogenous cortisol level cannot be ruled out as an important factor in chronic CSC. It is also possible that patients with chronic CSC generally have normal cortisol levels, but respond differently to stimulation of the HPA-axis. Stress, which also appears to be associated with chronic CSC,^{120, 121} stimulates the HPA-axis and could lead to temporarily elevated cortisol levels in patients as compared to healthy individuals. It is currently unclear how high levels of cortisol or corticosteroids can be linked to SRF accumulation. A study in rats suggested that the disease mechanism could be mediated by binding of corticosteroids to the mineralocorticoid receptor located in the choroidal vasculature.¹²² In that study, activation of the mineralocorticoid receptor caused vascular effects similar to those observed in chronic CSC.¹²² In addition, relative endogenous hypercortisolism can lead to an increased platelet aggregation, and consequently create the condition for increased microthrombus formation and increased blood viscosity.³³ Caccavale et al. combined these events in a pathogenic model in which they postulate that a reduction of the vascular bed due to the vasoconstriction and capillary occlusion, combined with higher resistance and increased blood viscosity, results in a sectorial hypoperfusion and an increase in endoluminal pressure in the surrounding healthy vascular bed.³³ Although this model is plausible and corresponds with the clinical findings, the exact underlying pathways still remain to be elucidated.

1.5 Treatment options in central serous chorioretinopathy

There is no 'gold standard' treatment for acute and/or chronic CSC due to a remarkable lack of prospective randomized controlled trials. Therefore, a wide spectrum of treatments has been and is still being used. A significant problem in the interpretation of possible treatment effects in CSC is the observation that many cases of acute and, to a lesser degree, chronic CSC may resolve spontaneously. As a consequence, the observed 'treatment effect' in retrospective and/or uncontrolled treatment studies may actually be spontaneous resolution.

In acute CSC, SRF resolves without treatment within 2-3 months in most cases with minimal visual sequelae.^{36, 101, 123} Therefore, many ophthalmologists adopt a conservative approach in acute CSC cases. However, treatments such as photodynamic therapy (PDT) with reduced settings, and other laser treatments such as selective retina therapy and micropulse laser treatment have been advocated.¹²⁴⁻¹²⁷ In steroid-associated cases, cessation of the steroids can also lead to spontaneous recovery.⁶⁴

Many ophthalmologists would consider to treat chronic CSC cases in which persistent SRF leakage involves the fovea. However, there is considerable controversy on the optimal timing and treatment in chronic CSC. In chronic CSC cases in which SRF is present in the macula for more than 4 months, irreversible atrophic retinal changes may develop.¹²⁸ Therefore, many ophthalmologists would consider to treat chronic CSC within 4 months in an attempt to achieve resolution of SRF, and thereby reduce the likelihood of clinically significant irreversible damage to the retina due to chronic SRF leakage. A recent Cochrane review compared the relative effectiveness of interventions for CSC. The review concludes that of the interventions studied to date, PDT or micropulse laser treatment appear the most promising to pursue in further studies in chronic CSC.¹²⁹ Nevertheless, a broad range of treatments has been and still is being used in CSC, which is discussed in the following section.

Conventional thermal laser treatment

The aim of conventional thermal laser treatment is to coagulate involved parts of the retinal tissue to achieve a therapeutic effect. This treatment depends on the selective absorption spectrum in specific tissues in the eye. Melanin is highly present in the RPE cells and has a high absorption coefficient in the spectral range of the conventional thermal laser.¹

In CSC, conventional thermal laser treatment can be used to coagulate the hot spot(s) of leakage as seen on FA. The proposed treatment goal is resolution of SRF through the laser-mediated formation of scar tissue which subsequently 'plugs' the RPE leak, restoring the RPE barrier and preventing further leakage. The healthy surrounding RPE cells are then able to pump the remaining SRF back into the choriocapillaris. However, Negi and Marmor have advocated that the SRF in CSC is not caused simply by a passive "leak" through the RPE barrier,

and the effects of photocoagulation in this disease cannot be explained simply as sealing such a leak.¹³⁰ They demonstrated that focal RPE damage actually promotes the flow of SRF towards the choroid.¹³⁰ Therefore the exact role of the RPE in CSC remains incompletely understood. Conventional laser treatment in CSC appears to have limited efficacy, and has several disadvantages. Most of the studies on conventional laser treatment in CSC have been carried out many years ago, before the advent of modern imaging techniques such as OCT, and these studies often did not clearly distinguish phenotypically between acute and chronic CSC. Although some studies suggest that conventional laser treatment reduces the duration of SRF accumulation, this treatment appeared to have no significant effect on the visual acuity.^{101, 131-133} The retinal tissue damage may result in a clinically significant scotoma when applied too centrally in the macula. Therefore, treatment of the (peri)foveal area should be avoided. This excludes thermal laser treatment as an option for patients with CSC who have a relatively central focus of SRF leakage. Conventional thermal laser is mainly effective in CSC phenotypes in which obvious focal leakage is observed on FA.¹⁰¹ Patients with chronic CSC can have multiple and/or large actively leaking areas in which case thermal laser treatment is also unwanted due to an increase of the possible side-effects. Side-effects that one should consider are the possibility of enlargement of the laser scar (creeping) with time and an increased risk of iatrogenic choroidal neovascularisation (CNV).^{36, 134, 135} Although conventional laser treatment has been used in CSC patients for decades, it is generally no longer the treatment of choice due to its limited efficacy and possible side-effects.¹⁰⁰

Photodynamic therapy

PDT is a laser technique that uses the light-sensitive substance verteporfin, which is intravenously administered and circulated during 10 minutes. The preferential concentration of verteporfin in the choroidal tissue is then reached after approximately 15 minutes. At this time point, the verteporfin is activated by a spot of laser light of a wavelength of 689-693nm, which presumably results in a release of free radicals leading to endothelial vascular damage and vessel occlusion.^{36, 136} The precise mechanisms of the PDT-induced cell and tissue effects are complex and not fully understood.¹ It is thought that selective damage, with minimal damage to the surrounding tissue, causes short-term choriocapillaris hypoperfusion and long-term choroidal restructuring, thus reducing choroidal congestion, hyperpermeability, and extravascular leakage in CSC.^{36, 137, 138} There is an ongoing debate about whether the area of PDT treatment should be guided by the abnormalities on FA and/or ICGA. The abnormalities on ICGA that often outweigh the abnormalities on FA suggest a strong involvement of the choroid. Therefore, choosing the laser spotsize of PDT based on the extent of the hyperfluorescent ICGA abnormalities is often considered a more appropriate approach than FA-guided treatment.

PDT was originally introduced and approved to treat certain subtypes of CNV in neovascular age-related macular degeneration (AMD). The original PDT settings in this disease used a verteporfin dose of 6 mg/m², a laser fluency of 50 J/cm², and a treatment time of 83

seconds. A study using these settings in chronic CSC, found that the treatment appears to be safe and effective.¹³⁹ A significant improvement of anatomy and visual acuity in the long-term (after 4-years follow-up) was seen, with no signs of laser-induced retinal atrophy or systemic adverse effects. However, in other studies in a minority of cases these unadjusted PDT settings showed long-term complications including choriocapillaris non-perfusion, secondary CNV and/or RPE atrophy and subsequent vision loss especially after repeated treatment.^{36, 140} To minimize the risk of such complications in CSC patients - who often still have a fairly good visual acuity - PDT settings were adjusted by reducing either the dose of the verteporfin (half-dose: 3 mg/m²), the laser fluency (half-fluency: 25 J/cm²), or the treatment time (half-time: 42 seconds).¹⁴¹⁻¹⁴⁷ These approaches further reduced the risk of PDT-associated complications while still showing a similar effect on the resolution of SRF as compared to full-settings PDT as well in acute as in chronic CSC, with reported success rates of SRF resolution of 81-100%.^{94, 141, 143, 144, 147-149} A further reduction of the verteporfin dose (to one third) may result in less efficacy in terms of SRF resolution.¹⁵⁰ Ma et al. performed a meta-analysis of 9 studies with a total of 319 patients (63 acute CSC cases and 256 chronic CSC cases).¹⁵¹ The study design of these studies varied from retrospective comparative studies (3 studies), to prospective comparative studies (3 studies), nonrandomized controlled trial (1 study), and randomized controlled trials (2 studies).¹⁵¹ Ma et al. concluded that PDT was effective in the treatment of CSC with improving visual acuity, a decrease in central macular thickness, and resolution of SRF. They also demonstrated that PDT was superior in SRF absorption as compared to laser photocoagulation or intravitreal injection of anti-vascular endothelial growth factor (VEGF), which resulted in a promising trend towards the use of half-dose PDT.¹⁵¹ In addition, a study comparing half-dose PDT to half-fluency PDT found that half-dose PDT induced a more rapid SRF reabsorption that lasted longer as compared to the half-fluency group.¹⁴⁸ However, another study comparing half-fluency PDT with half-dose PDT in chronic CSC patients did not find any significant differences in outcome when looking at the visual or anatomical results.¹⁵² Although some advocate the use of half-dose PDT, it is currently unclear if one of the reduced-settings protocols (half-dose, half-fluency, or half-time) is truly superior. Taken together, PDT treatment appears to be the most promising treatment for chronic CSC based on the currently available body of scientific evidence. However, there is a striking lack of large, multicenter prospective randomised controlled treatment trials in acute and chronic CSC, and there are no long-term follow-up and natural history studies evaluating the visual function, rate of recurrence and overall benefit of treatment in CSC.^{148, 152, 153}

High-density subthreshold micropulse laser treatment

High-density subthreshold micropulse laser treatment is a laser technique that targets the RPE, in contrast to PDT which targets the choroid. This laser technique uses a sequence of multiple ultrashort laser pulses with relative long intervals in between these laser pulses that allows the RPE to 'cool down' to avoid suprathreshold tissue-damaging thermal effects.^{127, 154-156} Using this technique, the level of photothermal effect on the RPE cells is

closely monitored, with no evident thermal tissue damage occurring in the retina, in contrast to conventional continuous-pulse thermal laser treatment. The mechanisms of action of micropulse laser treatment are largely unknown, but effects on the RPE have been postulated. It is hypothesized that the benefits may derive from altered regulation of factors mediated by the biological reaction of the RPE cells, for instance a therapeutic modulation of cytokine production. This is more likely to occur in RPE cells that have been only sub-lethally treated by a lower thermal effect, than RPE cells that have been lethally treated at ophthalmoscopically visible end-points.^{156, 157} The aim of the treatment in CSC is to stimulate the RPE cell functions such as the pumping function, to accelerate the resolution of the SRF. A variety of wavelengths have been used for micropulse laser treatment, including 810 nm,¹⁵⁵ 577nm,¹⁵⁸ and 527nm,¹⁵⁴ and studies have shown a positive effect on the resolution of SRF ranging in 41% to 58% of the chronic CSC patients.^{127, 154, 156, 158-160} The laser settings for each wavelength to achieve non-damaging subthreshold yet clinically effective results are still subject of debate.

Anti (VEGF)-vascular endothelial growth factor treatment

Anti-VEGF agents are commonly used for intraocular diseases with intraretinal oedema and SRF accumulation related to the production of VEGF, such as diabetic macular oedema, exudative AMD, and retinal venous occlusions. Despite the fact that uncomplicated CSC does not show CNV, and the observation that VEGF levels are not significantly elevated in aqueous samples from patients with CSC,^{161, 162} the intravitreal injection of anti-VEGFs has been investigated as a treatment CSC in numerous small studies. It was hypothesized that hypoxic conditions in the choroid and/or RPE result in compartmentalized local VEGF expression, which is not detectable in the aqueous. Others have postulated that the effect of anti-VEGFs may be based on their anti-permeability properties that have been described previously.¹⁶³⁻¹⁶⁵ The scientific proof for a treatment effect of anti-VEGF medication in CSC remains poor, as the publications reporting favourable results regarding improvement of visual acuity and reduction of SRF are uncontrolled studies.³⁶ The only randomized study comparing ranibizumab to observation in acute CSC showed no difference between both groups with regard to the visual acuity, central retinal thickness or duration of SRF.¹⁶⁶ In addition, patients included in these studies often suffer from their first CSC episode with a mean duration of SRF presence of approximately 4 months. Therefore, spontaneous resolution interpreted as a positive treatment effect is possible. A recent meta-analysis that include acute and chronic cases demonstrated that neither visual acuity nor central macular thickness were significantly improved 6 months after intravitreal bevacizumab as compared to observation, PDT or thermal laser therapy.¹⁶³ Also, Koss et al. compared micropulse laser treatment to intravitreal injection with bevacizumab and observation.¹⁶⁰ In the bevacizumab group persistent leakage was seen in 60% compared to 12.5% in the micropulse laser group and 92% in the observational group.¹⁶⁰ Bearing in mind that the precise pathogenetic mechanism of CSC remains unclear and does not seem to involve an important role for VEGF and neovascularisation, and the evidence

from current studies results is weak, the use of intravitreal anti-VEGF medication is not considered as primary treatment in CSC.²⁸ However, in CSC cases that become complicated by CNV¹⁶⁷, intravitreal anti-VEGF injections have shown beneficial results.¹⁶⁸

Systemic treatment

Based on the different postulated pathophysiological pathways, a broad range of oral medication belonging to the following therapeutic classes has been evaluated in CSC: carbonic anhydrase inhibitors, beta-blockers, antibiotics and proton pump inhibitors for the treatment of *Helicobacter pylori*, glucocorticoid-receptor antagonists, anti-platelet aggregation medication,¹⁶⁹ antimetabolites, 5 α -reductase inhibitors, diarylheptanoids, and aldosteron/mineralocorticoid receptor antagonists.^{36, 170} In these therapeutic groups, when looking at a positive effect on the resolution of the SRF, promising results were reported for acetazolamide,¹⁷¹ antibiotic treatment in *Helicobacter pylori* infection,^{51, 172} and mineralocorticoid receptor antagonist treatment.^{173, 174} As discussed above, especially the mineralocorticoid receptor antagonists could be of interest, as supported by several small studies. These studies showed a significant reduction in foveal SRF after 3 months as compared to baseline. This reduction in SRF corresponded with an increase of visual acuity.^{36, 173} However, the level of evidence to support the use of these systemic therapies is generally very low, mainly due to the inclusion of patients suffering from the acute form of CSC who are very likely to show spontaneous resolution anyway. Also, the number of included patients in these often retrospective and uncontrolled studies was low.^{28, 36} For acetazolamide, a carbonic anhydrase inhibitor, it has been suggested to cause acidification of the subretinal space, a decrease in standing potential, and an increase in retinal adhesiveness.¹⁷¹ This acidification of the subretinal space may be responsible for increased fluid resorption from the RPE to the choroid. Also, an improvement of the polarization and the pump function of the RPE is thought to occur. Finally, an anti-inflammatory effect is observed that may aid to facilitate the adhesion by inhibition of γ -glutamyl transpeptidase activity in the ocular tissue.¹⁷¹ Positive findings were described in an acute CSC cohort, but the current scientific level of evidence is again very low.¹⁷¹

The eradication of a possible *Helicobacter pylori* infection has been investigated with variable results in acute CSC. Rahbani-Nobar et al. found a positive effect on SRF,⁵¹ but Dang et al. were not able to confirm these findings and only found a positive effect on the retinal sensitivity.¹⁷² It is thought that a *Helicobacter pylori* infection could lead to a low-grade inflammatory stimulus. It has been documented that anti-cagA antibodies may cross-react with vascular wall antigens, triggering an immunological cascade that damages vascular endothelial cells. Also, it has been suggested that an interaction between *Helicobacter pylori* infection and diseases with a vascular endothelial disorder is mediated by variations in serum interleukin levels.⁵¹ All of these mechanisms may be involved in the pathophysiological pathway of CSC, but none of them have been proven based on solid scientific evidence.

1.6 Differential diagnosis of central serous chorioretinopathy

Although several typical characteristics can be seen on multimodal imaging in CSC (**Figure 7**), there are no pathognomonic clinical findings. For example, the presence of SRF is a hallmark feature of active CSC, but can also be seen in other macular diseases. Focal leakage through an RPE defect on FA associated with hyperfluorescent areas on ICGA is also a non-specific sign. Inactive and/or chronic CSC can be characterized by RPE alterations, which again are frequently seen in many other macular diseases. The most important differential diagnostic entities will be described below. Awareness of the most common differential diagnoses is of clinical relevance as a correct diagnosis determines the clinical prognosis and therapeutic decision-making.

AMD is a multifactorial disease that is the leading cause of irreversible blindness in the elderly population in the Western world. Generally, two different phenotypes can be distinguished: an atrophic and neovascular form. In both forms the diagnosis of 'typical' AMD is thought to require the presence of drusen, or the assumption that drusen were present but have disappeared with the development of CNV or RPE atrophy.³⁵ Drusen are focal subretinal deposits that consist of amorphous extracellular material between Bruch's membrane and the RPE that appear like yellowish spots on the fundus.¹⁷⁵ AMD should be considered especially in the differential diagnoses of chronic CSC because these patients are older and have more RPE changes than patients with acute CSC. Also, chronic CSC can be complicated by CNV and/or polypoidal choroidal vasculopathy,^{99, 176, 177} causing further clinical overlap with neovascular AMD. Compared to chronic CSC patients, neovascular AMD patients usually have an older age at onset and the prevalence of AMD is approximately equal in men and women. Drusen are not typically present in chronic CSC, and the presence of drusen in the (fellow) eye of an older patient with serous SRF should raise suspicion of AMD with (occult) CNV and/or polypoidal choroidal vasculopathy mimicking chronic CSC. Signs that can point clinicians towards the correct diagnosis, are the possible presence of hard exudates, grayish subretinal fibrosis or blood on fundoscopy, which are highly indicative for CNV. Most cases of CNV in AMD deteriorate quite rapidly, but some cases of small smouldering occult CNV and associated serous SRF in AMD can remain fairly stable for weeks to months. On OCT, signs indicative of (occult) CNV in AMD include: a relatively broad RPE detachment that is separated from the underlying Bruch's membrane ('double layer sign') with a certain degree of hyperreflective sub-RPE changes; an irregular RPE defect due to neovascular subretinal ingrowth; and intraretinal edema different from posterior cystoid degeneration. In typical AMD, the macula in the fellow eye shows drusen if unaffected by CNV and/or profound RPE atrophy. On FA, signs indicative of neovascular AMD include indistinct leakage (no 'hot spot') and hyperfluorescent drusen. In the case of occult CNV in AMD, ICGA shows a well-circumscribed neovascular membrane (**Figure 8A-D**) of variable fluorescence, without the indistinct predominantly hyperfluorescent choroidal

areas typical of CSC. Neovascular AMD is treated with intravitreal anti-VEGF injections.^{178, 179}

Polypoidal choroidal vasculopathy (PCV) is a specific form of subretinal neovascularisation,¹⁸⁰ that can be seen as an isolated clinical picture, but also as a complication of other macular diseases such as drusenoid neovascular AMD and chronic CSC.^{181, 182} Although PCV and chronic CSC are two different entities, and chronic CSC can be complicated by PCV, cases of isolated PCV may present with similar clinical findings on OCT and FA, with smaller or larger RPE detachments and serous SRF accumulation. Polyps in PCV can be seen in fundoscopy as small or larger pink-colored subretinal structures, sometimes associated with haemorrhages, hard exudate leakage and/or subretinal fibrosis. Especially in the early phase of the disease and in Caucasian patients the polyp(s) in PCV may still be small and can be easily overlooked (**Figure 8E-H**). Like in occult CNV in neovascular AMD, PCV tends to deteriorate quite rapidly, but some cases of small smouldering polyps with or without small occult CNV can remain fairly stable for weeks to months. Yannuzzi et al. illustrated that ICGA is an important imaging modality to establish the correct diagnosis.¹⁸⁰ One or more hyperfluorescent polyps, often surrounded by a hypofluorescent halo, and often associated with occult CNV, can be confirmed on early and midphase ICGA.¹⁸⁰ Like in chronic CSC, ICGA in a subgroup of patients presenting primarily with PCV can reveal indistinct choroidal hyperpermeability besides the polypoidal lesion(s),^{36, 183} and distinctive hyperfluorescent punctate lesions.¹⁰⁵ This indicates that a subgroup of PCV is part of the CSC/pachychoroid spectrum, which is also suggested by the finding of a thickened choroid in a subgroup of PCV patients.¹⁸⁴ Furthermore, several OCT signs are indicative of a polypoidal process, such as a focal RPE detachment that often corresponds to the polypoidal lesions seen on ICGA. These lesions contain more highly reflective material on OCT compared to the adjacent RPE detachment (**Figure 8H**).¹⁸⁵ PCV is more frequently associated with intraretinal cystoid edema, the presence of intraretinal lipid deposits, and hemorrhagic RPE detachments as compared to CSC.^{36, 186} Similar to some forms of occult CNV and some chronic CSC cases, a 'double layer sign' on OCT can be seen in PCV. In PCV the double layer sign is typically seen in the area of branching vascular network of the CNV, with an adjacent smaller or larger dome-shaped RPE detachment with underlying polyp, and may reflect a fluid accumulation together with neovascular and/or polypoidal tissue between the RPE en Bruch's membrane.¹⁸⁷

In contrast to half-dose PDT treatment, which is advocated for chronic CSC, for PCV a combination of full-dose PDT with or without intravitreal anti-VEGF injections are generally considered as first choice of treatment.¹⁸⁸⁻¹⁹⁰

The clinical spectrum of *dome-shaped macula* and *tilted disc with inferior staphyloma* presents mostly with a central SRF accumulation and an inward or anterior deviation of the macula (**Figure 8P-S**).¹⁹¹ This bulge affects the retina, the RPE, and the inner choroid. In contrast to classical chronic CSC, which is more commonly seen in hyperopic patients, dome-shaped macula is more common in (highly) myopic patients. Multimodal imaging

may reveal hyperfluorescent areas and spots on FA and ICGA. On OCT imaging small RPE detachments can be present, and a greater subfoveal choroidal thickness as compared to eyes without SRF can be seen on enhanced depth imaging.¹⁹¹ The presence of an inward or anterior deviation of the macula and myopia, is especially suggestive of dome-shaped macula. In the case of tilted disc with inferior staphyloma, a tilted optic disc with an oblique insertion into the globe, an inferonasal crescent of the optic disc, and in some cases situs inversus of the retinal vessels is seen.¹⁹² The inferior staphyloma is generally invisible on the horizontal OCT scan, and can best be recognized on a vertical OCT scan which shows an unusual convexity within the general concavity of the staphyloma (**Figure 8S**).¹⁹³ Macular serous SRF accumulation in the dome-shaped maculopathy and tilted disc/inferior staphyloma spectrum responds poorly to treatment such as PDT and intravitreal anti-VEGF injections. Occasionally, SRF may resolve spontaneously.^{36, 194}

Pachychoroid pigment epitheliopathy is a condition in which patients show an increased choroidal thickness on EDI-OCT, nonspecific pigment epithelial changes at the fovea, and RPE changes and/or small RPE detachments directly overlying localized areas of thickened choroid and/or dilated choroidal vessels that may be visible on funduscopy.^{195, 196} Also, findings on FA and ICGA resemble milder variants of the hyperfluorescent patterns that can be found in chronic CSC patients. In contrast to chronic CSC, these patients do not have a history of vision loss due to SRF accumulation.¹⁹⁵ However, due to the apparent clinical overlap, pachychoroid pigment epitheliopathy is thought to be a 'forme fruste' or precursor of CSC.¹⁹⁵

Choroidal tumors can also be associated with serous SRF accumulation that may mimic CSC (**Figure 8L-O**). A benign vascular tumor such as circumscribed choroidal hemangioma presents with a deep orange-red lesion on funduscopy, in contrast to chronic CSC. The tumor itself can appear fairly flat on retinal OCT, but increased vascular calibres may be present on enhanced depth or swept-source OCT imaging. During FA a similar pattern of hyperfluorescent RPE changes can be seen as in chronic CSC, although often without a clear 'hot spot' of leakage. However, on ICGA the filling of intratumoral vessels is clearly seen during the arterial phase on the hypofluorescent background. During the venous phase the tumour shows maximum hyperfluorescence. During the late phase the ICGA shows a typical 'wash-out' image with residual hyperfluorescent caverns (**Figure 8N**).¹⁹⁷ Therefore, ICGA helps to differentiate a choroidal hemangioma from chronic CSC. Ultrasonography enables additional distinction between a tumor and chronic CSC, identifying a high reflective choroidal swelling. Circumscribed choroidal hemangiomas generally respond favourably to full-dose PDT treatment.¹⁹⁸ Choroidal naevi or melanoma may also be associated with serous SRF accumulation but are generally easy to distinguish from CSC on funduscopy and ultrasonography.

Optic disc pit is a developmental anomaly of the optic disc that can be associated with a serous retinal detachment in the macula, with or without associated schisis-like intraretinal edema, that can occur at any age, but most frequently in early adulthood. Signs of an optic pit on funduscopy include a slightly larger than normal optic disc that contains a round or oval pit, usually gray, yellow, or black in appearance, of variable size (**Figure 8I**). The pit is usually located temporally in the optic disc.² The fluid in optic disc pit can be localized under the neuroretina, causing a serous neuroretinal detachment, and/or between the inner and outer layers of the retina, producing a schisis-like appearance, thus mimicking (chronic) CSC. The origin of intra- and/or subretinal fluid in this condition is unclear. The optic disc pit can also be associated to peripapillary chorioretinal atrophy and RPE changes. In contrast to CSC, patients with an optic pit do not have hyperfluorescent areas with hot spots of leakage on FA and ICGA that are typical of CSC. OCT imaging of the optic disc can give additional diagnostic support for differentiation in addition to the characteristic fundoscopic aspect of an optic pit (**Figure 8I-K**).^{1, 199} As the natural course of SRF and intraretinal changes in optic disc pit is unfavourable, various types of surgical intervention have been proposed.^{200, 201}

Serous retinopathy associated with mitogen-activated protein kinase kinase (MEK) inhibition, is a side effect described in patients treated with MEK inhibitors for metastatic neoplastic disease.²⁰² Van Dijk et al. found that in this specific patient group a serous SRF accumulation can mimic CSC.²⁰³ However, additional imaging using FA hardly shows any hyperfluorescent leakage, and OCT does not show RPE changes or a thickened choroid in contrast to chronic CSC, and lesions are often multifocal. The SRF accumulation in this retinopathy was shown to be time-dependent and reversible. Resolution occurred either spontaneously or soon after cessation or dose tapering of the MEK inhibitor (**Figure 8T-V**).²⁰³

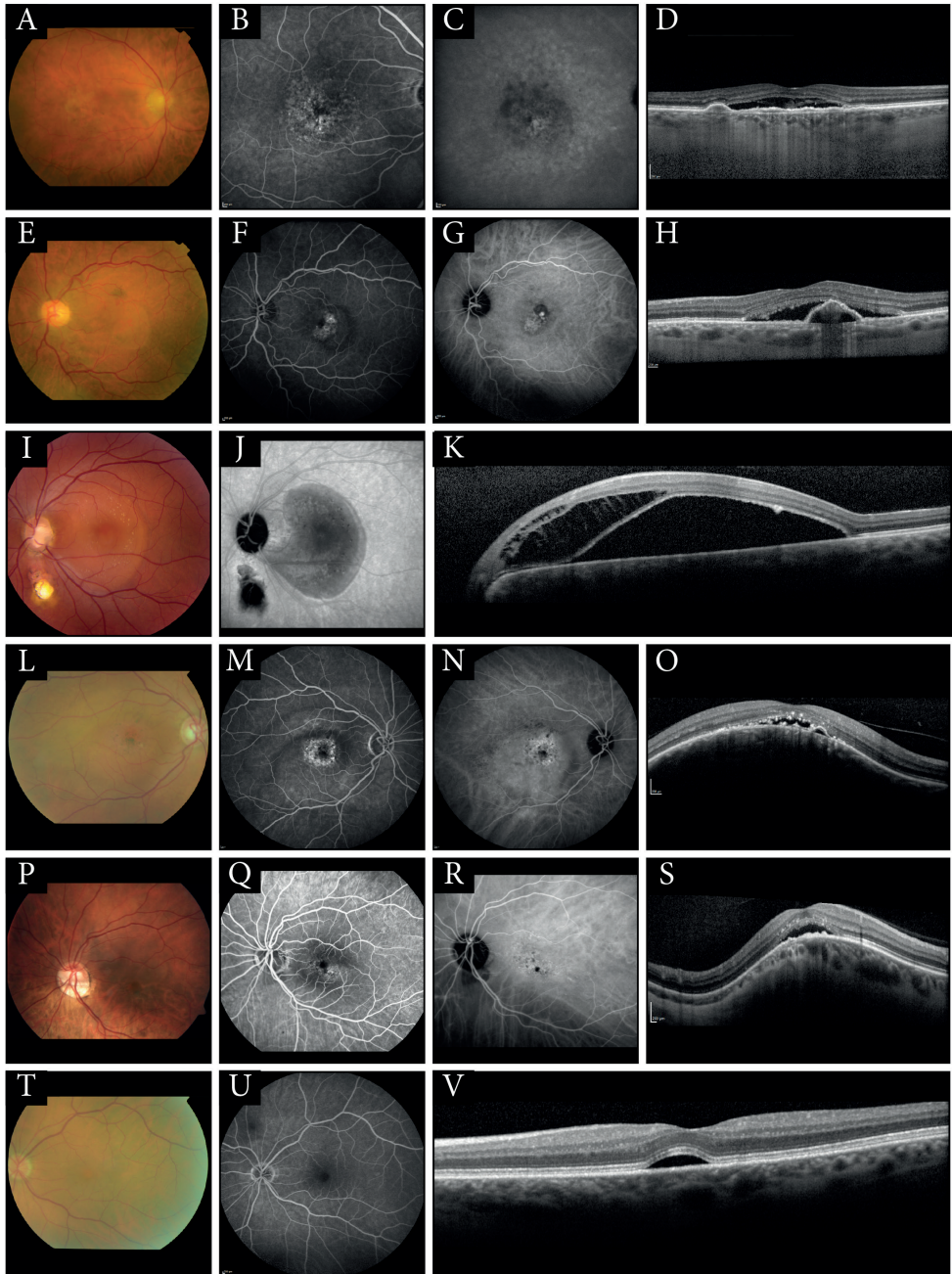


Figure 8.

(**A-D**) Images of an example of age-related macular degeneration (AMD). (**A**) Color fundus photograph (CFF) showing a few small yellowish drusen in the center of the macula. (**B**) Fluorescein angiography (FA) illustrates central punctiform staining without a clear ‘hot spot’ of leakage. On indocyanine green angiography (ICGA) (**C**) irregular hypofluorescence and hyperfluorescence are visible. On optical coherence tomography (OCT) (**D**) a shallow subretinal fluid (SRF) accumulation can be identified with a retinal pigment epithelium (RPE) detachment. Also, a relatively thin choroid is seen. (**E-H**) An example of a polypoidal choroidal vasulopathy (PCV), in combination with a branching vascular network of neovascularisation. (**E**) The CFF image shows a mild hypopigmentation of the macula indicating the presence of SRF as evidenced on OCT (**H**) and a small pink polyp. FA (**F**) shows hyperfluorescent staining inferior of the foveal area, and superior of the foveal area a hyperfluorescent hot spot is seen with some diffuse leakage. On ICGA (**G**), a relatively well-delineated hyperfluorescent branching vascular network is visible, with the hyperfluorescent polyp at the superotemporal edge of this neovascular network, surrounded by a hypofluorescent zone. The OCT-scan (**H**) demonstrates the SRF and an RPE detachment with some underlying hyperreflective changes that correspond to the neovascular polypoidal tissue. (**I-K**) CFF (**I**), late-phase ICGA (**J**), and OCT-scan of an optic pit. (**I**) The CFF image illustrates the slightly depigmented serous SRF collection in the macula. In addition, this patient had a microcoloboma below the optic disc. ICGA (**J**) did not show any hyperfluorescent zones, which is in contrast to CSC. (**K**) OCT-scan shows intraretinal fluid that bears resemblance to retinoschisis, especially between the fovea and the optic disc, in combination with SRF that seems to have a shallow connection to the optic disc. (**L-O**) Submacular choroidal haemangioma. The CFF (**L**) shows an orange circumscribed hemangioma with hyperpigmentation centrally in the macula. FA (**M**) reveals a hyperfluorescent structure without clear hot spots of leakage. This hyperfluorescent structure on FA corresponds to the hyperfluorescent choroidal abnormalities of the hemangioma on ICGA (**N**). On OCT (**O**), a choroidal mass with SRF and a small PED is seen. (**P-S**) Multimodal imaging of a patient with serous maculopathy associated with tilted disk/inferior staphyloma. The CFF (**P**) shows an optic disc tilted inferiorly. Hyperfluorescent abnormalities are seen on FA (**Q**) and ICGA (**R**), without clear ‘hot spots’ of leakage. A vertical OCT-scan (**S**) demonstrating the typical dome-shaped macula, with the serous SRF and RPE changes typically localized at the transition zone of thicker and thinner choroid of the inferior staphyloma. (**T-V**) A CFF, FA, and OCT-scan of a patient with serous retinopathy associated with mitogen-activated protein kinase kinase inhibitor treatment (in this case binimetinib) for metastatic cancer, in this case cutaneous melanoma. CFF (**T**) illustrates a almost invisible yellowish subfoveal lesion, and FA (**U**) shows hardly any abnormalities in contrast to CSC. A SRF collection in the macula is seen on OCT (**V**).

1.7 Aims and outlines of this thesis

CSC often affects relatively young (middle-aged) patients who are still professionally active. Especially in chronic CSC, the prolonged disease course can have significant visual impact. Despite the fact that CSC is among the most common forms of maculopathy, relatively little is known about the pathogenesis, clinical characteristics, and optimal treatment of CSC. This thesis aims to provide new insights into the pathogenesis, clinical characteristics, long-term outcome, vision-related quality of life, and treatment of chronic CSC. Genetic influences are studied and possible pathophysiological mechanisms are discussed. Also, the overall clinical course and current clinical practice is evaluated, working towards a better treatment of chronic CSC through evidence-based treatment guidelines.

Chapter 2.1 describes one of the first genetic studies in a large chronic CSC cohort. A significant association was found between specific single nucleotide polymorphisms (SNPs) in the *CFH* gene, as well as a SNP in the *ARMS2* gene. The frequencies of these SNPs are compared to an AMD population in which these SNPs were originally found to be important.

Chapter 2.2 investigates the possible involvement of the complement system in the pathogenesis of CSC, through an analysis of the *C4* gene. This gene plays an important role in the classic and the lectin pathway and was previously described in association with several autoimmune diseases with ocular involvement.

Chapter 3.1 evaluates the long-term clinical outcome of patients with chronic CSC. In addition, the vision-related quality of life is assessed using a validated questionnaire.

Chapter 3.2 describes the characteristics and variability of SRF in chronic CSC on spectral domain OCT, using a novel semi-automated analysis technique. Differences in these OCT characteristics may predict differences in treatment response of chronic CSC patients.

Chapter 3.3 describes the first results of a novel OCT imaging technique, OCT angiography, in chronic CSC patients. This technique visualizes the blood flow in the retina and the underlying choroid using a non-invasive OCT analysis technique. The findings are compared to the invasive imaging techniques that are currently used for evaluation of vascular abnormalities in chronic CSC: FA and ICGA.

Chapter 4.1 presents the results of a prospective treatment protocol in chronic CSC. Patients treated according to this protocol first received half-dose PDT treatment followed by high-density subthreshold micropulse laser therapy if needed.

Chapter 4.2 describes the response to PDT treatment in a specific subgroup of chronic CSC patients who developed the disease in association with corticosteroid use as a possible exogenic factor. We retrospectively evaluated if half-dose PDT shows similar efficacy as compared to a control group who had chronic CSC without associated corticosteroid use.

Chapter 4.3 presents the protocol of the first prospective, randomized controlled multicentre treatment trial for chronic CSC, the PLACE trial. In this study, half-dose PDT is compared to high-density subthreshold micropulse laser treatment in patients with chronic CSC.

Chapter 4.4 reports a pilot study that tested the oral use of the mineralocorticoid antagonist eplerenone as a treatment option in patients with typical chronic CSC who did not respond to previous treatments that are commonly used, such as PDT and micropulse laser therapy.

Chapter 5 summarizes and integrates the major findings of this thesis, discussing their implications and future perspectives.

References

1. Agarwal A. Gass' atlas of macular diseases: Elsevier; 2012:6-8
2. Kanski JJ, Bowling B. Clinical ophthalmology a systemic approach, 7th edition, Elsevier; 2011:593-646
3. Gupta MP, Herzlich AA, Sauer T, Chan CC. Retinal anatomy and pathology. *Dev Ophthalmol* 2016;55:7-17.
4. Yannuzzi LA. The retinal atlas: Elsevier; 2010:2-6
5. Mannu GS. Retinal phototransduction. *Neurosciences (Riyadh)* 2014;19(4):275-80.
6. Rizzolo LJ, Peng S, Luo Y, Xiao W. Integration of tight junctions and claudins with the barrier functions of the retinal pigment epithelium. *Prog Retin Eye Res* 2011;30(5):296-323.
7. Strauss O. The retinal pigment epithelium in visual function. *Physiol Rev* 2005;85(3):845-81.
8. Reynolds J, Olisky S. Pediatric Retina; Chapter 2 Anatomy and physiology of the retina: Springer-Verlag Berlin Heidelberg; 2011:39-65
9. Moreno TA, O'Connell RV, Chiu SJ, et al. Choroid development and feasibility of choroidal imaging in the preterm and term infants utilizing SD-OCT. *Invest Ophthalmol Vis Sci* 2013;54(6):4140-7.
10. Ramrattan RS, van der Schaft TL, Mooy CM, et al. Morphometric analysis of Bruch's membrane, the choriocapillaris, and the choroid in aging. *Invest Ophthalmol Vis Sci* 1994;35(6):2857-64.
11. Nickla DL, Wallman J. The multifunctional choroid. *Prog Retin Eye Res* 2010;29(2):144-68.
12. Booi J, Baas DC, Beisekeeva J, et al. The dynamic nature of Bruch's membrane. *Prog Retin Eye Res* 2010;29(1):1-18.
13. Chong NH, Keonin J, Luthert PJ, et al. Decreased thickness and integrity of the macular elastic layer of Bruch's membrane correspond to the distribution of lesions associated with age-related macular degeneration. *Am J Pathol* 2005;166(1):241-51.
14. Bill A, Sperber G, Ujii K. Physiology of the choroidal vascular bed. *Int Ophthalmol* 1983;6(2):101-7.
15. Barishak YR. Embryology of the eye and its adnexae. *Dev Ophthalmol* 1992;24:1-142.
16. Kaur C, Foulds WS, Ling EA. Blood-retinal barrier in hypoxic ischaemic conditions: basic concepts, clinical features and management. *Prog Retin Eye Res* 2008;27(6):622-47.
17. Roisman L, Lavinsky D, Magalhaes F, et al. Fundus autofluorescence and spectral domain OCT in central serous chorioretinopathy. *J Ophthalmol* 2011;2011:706849.
18. Spaide RF, Klancnik JM, Jr. Fundus autofluorescence and central serous chorioretinopathy. *Ophthalmology* 2005;112(5):825-33.
19. Armenti ST, Greenberg JP, Smith RT. Quantitative Fundus autofluorescence for the evaluation of retinal diseases. *J Vis Exp* 2016(109).
20. Adhi M, Duker JS. Optical coherence tomography--current and future applications. *Curr Opin Ophthalmol* 2013;24(3):213-21.
21. Huang D, Swanson EA, Lin CP, et al. Optical coherence tomography. *Science* (80-) 1991;254(5035):1178-81.

22. Hamzah F, Shinojima A, Mori R, Yuzawa M. Choroidal thickness measurement by enhanced depth imaging and swept-source optical coherence tomography in central serous chorioretinopathy. *BMC Ophthalmol* 2014;14:145.
23. Spaide RF, Koizumi H, Pozzoni MC. Enhanced depth imaging spectral-domain optical coherence tomography. *Am J Ophthalmol* 2008;146(4):496-500.
24. Yasuno Y, Hong Y, Makita S, et al. In vivo high-contrast imaging of deep posterior eye by 1-microm swept source optical coherence tomography and scattering optical coherence angiography. *Opt Express* 2007;15(10):6121-39.
25. Jia Y, Tan O, Tokayer J, et al. Split-spectrum amplitude-decorrelation angiography with optical coherence tomography. *Opt Express* 2012;20(4):4710-25.
26. Spaide RF, Fujimoto JG, Waheed NK. Optical coherence tomography angiography. *Retina* 2015;35(11):2161-2.
27. Von Graefe A. Kurzere abhandlungen, notizen und casaistische mittheilungen vermischten inhalts: VI. Ueber zentrale recidivirende retinitis. *Graefes Arch Clin Ophthalmol* 1866;12:211-215
28. Nicholson B, Noble J, Forooghian F, Meyerle C. Central serous chorioretinopathy: update on pathophysiology and treatment. *Surv Ophthalmol* 2013;58(2):103-26.
29. Maumenee AE. Macular diseases: clinical manifestations. *Trans Am Acad Ophthalmol Otolaryngol* 1965;69:605-13.
30. Gass JD. Pathogenesis of disciform detachment of the neuroepithelium. *Am J Ophthalmol* 1967;63(3):Suppl:1-139.
31. Liegl R, Ulbig MW. Central serous chorioretinopathy. *Ophthalmologica* 2014;232(2):65-76.
32. Colucciello M. Choroidal neovascularization complicating photodynamic therapy for central serous retinopathy. *Retina* 2006;26(2):239-42.
33. Caccavale A, Romanazzi F, Imperato M, et al. Central serous chorioretinopathy: a pathogenetic model. *Clin Ophthalmol* 2011;5:239-43.
34. Kitzmann AS, Pulido JS, Diehl NN, et al. The incidence of central serous chorioretinopathy in Olmsted County, Minnesota, 1980-2002. *Ophthalmology* 2008;115(1):169-73.
35. Wang M, Munch IC, Hasler PW, et al. Central serous chorioretinopathy. *Acta Ophthalmol* 2008;86(2):126-45.
36. Daruich A, Matet A, Dirani A, et al. Central serous chorioretinopathy: Recent findings and new physiopathology hypothesis. *Prog Retin Eye Res* 2015.
37. Haimovici R, Koh S, Gagnon DR, et al. Risk factors for central serous chorioretinopathy: a case-control study. *Ophthalmology* 2004;111(2):244-9.
38. Khairallah M, Kahloun R, Tugal-Tutkun I. Central serous chorioretinopathy, corticosteroids, and uveitis. *Ocul Immunol Inflamm* 2012;20(2):76-85.
39. Chang YS, Weng SF, Chang C, et al. Associations between topical ophthalmic corticosteroids and central serous chorioretinopathy: a taiwanese population-based study. *Invest Ophthalmol Vis Sci* 2015;56(6):4083-9.
40. Bouzas EA, Karadimas P, Pournaras CJ. Central serous chorioretinopathy and glucocorticoids. *Surv Ophthalmol* 2002;47(5):431-48.

41. Fardin B, Weissgold DJ. Central serous chorioretinopathy after inhaled steroid use for post-mycoplasmal bronchospasm. *Br J Ophthalmol* 2002;86(9):1065-6.
42. Giovansili I, Belange G, Affortit A. Cushing disease revealed by bilateral atypical central serous chorioretinopathy: case report. *Endocr Pract* 2013;19(5):e129-33.
43. Wakakura M, Ishikawa S. Central serous chorioretinopathy complicating systemic corticosteroid treatment. *Br J Ophthalmol* 1984;68(5):329-31.
44. Wakakura M, Song E, Ishikawa S. Corticosteroid-induced central serous chorioretinopathy. *Jpn J Ophthalmol* 1997;41(3):180-5.
45. van Dijk EH, Dijkman G, Biermasz NR, et al. Chronic central serous chorioretinopathy as a presenting symptom of Cushing syndrome. *Eur J Ophthalmol* 2016:0.
46. Yannuzzi LA. Type A behavior and central serous chorioretinopathy. *Retina* 2012;32 Suppl 1:709.
47. Chakraborti C, Samanta SK, Faiduddin K, et al. Bilateral central serous chorio-retinopathy in pregnancy presenting with severe visual loss. *Nepal J Ophthalmol* 2014;6(2):220-3.
48. Sunness JS, Haller JA, Fine SL. Central serous chorioretinopathy and pregnancy. *Arch Ophthalmol* 1993;111(3):360-4.
49. Bujarborua D, Borooah S, Dhillon B. Getting serious with retinopathy: approaching an integrated hypothesis for central serous chorioretinopathy. *Med Hypotheses* 2013;81(2):268-73.
50. Fraunfelder FW, Fraunfelder FT. Central serous chorioretinopathy associated with sildenafil. *Retina* 2008;28(4):606-9.
51. Rahbani-Nobar MB, Javadzadeh A, Ghojazadeh L, et al. The effect of *Helicobacter pylori* treatment on remission of idiopathic central serous chorioretinopathy. *Mol Vis* 2011;17:99-103.
52. Weenink AC, Borsje RA, Oosterhuis JA. Familial chronic central serous chorioretinopathy. *Ophthalmologica* 2001;215(3):183-7.
53. Oosterhuis JA. Familial central serous retinopathy. *Graefes Arch Clin Exp Ophthalmol* 1996;234(5):337-41.
54. Miki A, Kondo N, Yanagisawa S, et al. Common variants in the complement factor H gene confer genetic susceptibility to central serous chorioretinopathy. *Ophthalmology* 2014;121(5):1067-72.
55. Schubert C, Pryds A, Zeng S, et al. Cadherin 5 is regulated by corticosteroids and associated with central serous chorioretinopathy. *Hum Mutat* 2014;35(7):859-67.
56. Moschos MM, Gazouli M, Gatziofias Z, et al. Prevalence of the complement factor H and Gstm1 genes polymorphisms in patients with central serous chorioretinopathy. *Retina* 2016;36(2):402-7.
57. Tittl MK, Spaide RF, Wong D, et al. Systemic findings associated with central serous chorioretinopathy. *Am J Ophthalmol* 1999;128(1):63-8.
58. Chen SN, Lian I. Increased risk of coronary heart disease in male patients with central serous chorioretinopathy: results of a population-based cohort study. *Br J Ophthalmol* 2014;98(7):997.
59. Tsai DC, Huang CC, Chen SJ, et al. Central serous chorioretinopathy and risk of ischaemic stroke: a population-based cohort study. *Br J Ophthalmol* 2012;96(12):1484-8.
60. Tsai DC, Huang CC, Chen SJ, et al. Increased risk of erectile dysfunction among males with central serous chorioretinopathy -- a retrospective cohort study. *Acta Ophthalmol* 2013;91(7):666-71.

61. Bauml CR, Martidis A, Truong SN. Central serous chorioretinopathy associated with periocular corticosteroid injection treatment for HLA-B27-associated iritis. *Arch Ophthalmol* 2004;122(6):926-8.
62. Ezra N, Taban M, Behroozan D. Central serous chorioretinopathy associated with topical corticosteroids in a patient with psoriasis. *J Drugs Dermatol* 2011;10(8):918-21.
63. Fernandez CF, Mendoza AJ, Arevalo JF. Central serous chorioretinopathy associated with topical dermal corticosteroids. *Retina* 2004;24(3):471-4.
64. Kleinberger AJ, Patel C, Lieberman RM, Malkin BD. Bilateral central serous chorioretinopathy caused by intranasal corticosteroids: a case report and review of the literature. *Laryngoscope* 2011;121(9):2034-7.
65. Haimovici R, Gragoudas ES, Duker JS, et al. Central serous chorioretinopathy associated with inhaled or intranasal corticosteroids. *Ophthalmology* 1997;104(10):1653-60.
66. Hurvitz AP, Hodapp KL, Jadgchew J, et al. Central serous chorioretinopathy resulting in altered vision and color perception after glenohumeral corticosteroid injection. *Orthopedics* 2009;32(8).
67. Kassam AA, White W, Ling RH, Kitson JB. Loss of visual acuity due to central serous retinopathy after steroid injection into the shoulder bursa. *J Shoulder Elbow Surg* 2011;20(4):e5-6.
68. Carvalho-Recchia CA, Yannuzzi LA, Negrao S, et al. Corticosteroids and central serous chorioretinopathy. *Ophthalmology* 2002;109(10):1834-7.
69. Bouzas EA, Scott MH, Mastorakos G, et al. Central serous chorioretinopathy in endogenous hypercortisolism. *Arch Ophthalmol* 1993;111(9):1229-33.
70. Yannuzzi LA. Type A behavior and central serous chorioretinopathy. *Trans Am Ophthalmol Soc* 1986;84:799-845.
71. Mansueta CC, Mason JO, 3rd, Swanner J, et al. An association between central serous chorioretinopathy and gastroesophageal reflux disease. *Am J Ophthalmol* 2004;137(6):1096-100.
72. Cotticelli L, Borrelli M, D'Alessio AC, et al. Central serous chorioretinopathy and *Helicobacter pylori*. *Eur J Ophthalmol* 2006;16(2):274-8.
73. Michael JC, Pak J, Pulido J, de Venecia G. Central serous chorioretinopathy associated with administration of sympathomimetic agents. *Am J Ophthalmol* 2003;136(1):182-5.
74. Pierce KK, Lane RG. Central serous chorioretinopathy associated with the use of ephedra. *Retin Cases Brief Rep* 2009;3(4):376-8.
75. Aliferis K, Petropoulos IK, Farpour B, et al. Should central serous chorioretinopathy be added to the list of ocular side effects of phosphodiesterase 5 inhibitors? *Ophthalmologica* 2012;227(2):85-9.
76. Brodie FL, Charlson ES, Aleman TS, et al. Obstructive sleep apnea and central serous chorioretinopathy. *Retina* 2015;35(2):238-43.
77. Liew G, Quin G, Gillies M, Fraser-Bell S. Central serous chorioretinopathy: a review of epidemiology and pathophysiology. *Clin Experiment Ophthalmol* 2013;41(2):201-14.
78. Yannuzzi LA. Central serous chorioretinopathy: a personal perspective. *Am J Ophthalmol* 2010;149(3):361-3.
79. Eandi CM, Ober M, Iranmanesh R, et al. Acute central serous chorioretinopathy and fundus autofluorescence. *Retina* 2005;25(8):989-93.

80. Pare JR, Guo Y, Schechter-Perkins EM. The evaluation of acute vision loss: central serous chorioretinopathy. *Am J Emerg Med* 2014;32(4):396 e3-4.
81. Bae SW, Chae JB. Assessment of metamorphopsia in patients with central serous chorioretinopathy. *Indian J Ophthalmol* 2013;61(4):172-5.
82. Baran NV, Gurlu VP, Esgin H. Long-term macular function in eyes with central serous chorioretinopathy. *Clin Experiment Ophthalmol* 2005;33(4):369-72.
83. Prunte C, Flammer J. Choroidal capillary and venous congestion in central serous chorioretinopathy. *Am J Ophthalmol* 1996;121(1):26-34.
84. Kitaya N, Nagaoka T, Hikichi T, et al. Features of abnormal choroidal circulation in central serous chorioretinopathy. *Br J Ophthalmol* 2003;87(6):709-12.
85. Giovannini A, Scassellati-Sforzolini B, D'Altoibrando E, et al. Choroidal findings in the course of idiopathic serous pigment epithelium detachment detected by indocyanine green videoangiography. *Retina* 1997;17(4):286-93.
86. Piccolino FC, Borgia L. Central serous chorioretinopathy and indocyanine green angiography. *Retina* 1994;14(3):231-42.
87. Spaide RF, Hall L, Haas A, et al. Indocyanine green videoangiography of older patients with central serous chorioretinopathy. *Retina* 1996;16(3):203-13.
88. Tsujikawa A, Ojima Y, Yamashiro K, et al. Punctate hyperfluorescent spots associated with central serous chorioretinopathy as seen on indocyanine green angiography. *Retina* 2010;30(5):801-9.
89. Fujimoto H, Gomi F, Wakabayashi T, et al. Morphologic changes in acute central serous chorioretinopathy evaluated by fourier-domain optical coherence tomography. *Ophthalmology* 2008;115(9):1494-500, 500 e1-2.
90. Ahlers C, Geitzenauer W, Stock G, et al. Alterations of intraretinal layers in acute central serous chorioretinopathy. *Acta Ophthalmol* 2009;87(5):511-6.
91. Yang L, Jonas JB, Wei W. Optical coherence tomography-assisted enhanced depth imaging of central serous chorioretinopathy. *Invest Ophthalmol Vis Sci* 2013;54(7):4659-65.
92. Hirami Y, Tsujikawa A, Sasahara M, et al. Alterations of retinal pigment epithelium in central serous chorioretinopathy. *Clin Experiment Ophthalmol* 2007;35(3):225-30.
93. Imamura Y, Fujiwara T, Margolis R, Spaide RF. Enhanced depth imaging optical coherence tomography of the choroid in central serous chorioretinopathy. *Retina* 2009;29(10):1469-73.
94. Jirarattanasopa P, Ooto S, Tsujikawa A, et al. Assessment of macular choroidal thickness by optical coherence tomography and angiographic changes in central serous chorioretinopathy. *Ophthalmology* 2012;119(8):1666-78.
95. Kim YT, Kang SW, Bai KH. Choroidal thickness in both eyes of patients with unilaterally active central serous chorioretinopathy. *Eye (Lond)* 2011;25(12):1635-40.
96. Goktas A. Correlation of subretinal fluid volume with choroidal thickness and macular volume in acute central serous chorioretinopathy. *Eye (Lond)* 2014;28(12):1431-6.
97. Maruko I, Iida T, Sugano Y, et al. Subfoveal choroidal thickness in fellow eyes of patients with central serous chorioretinopathy. *Retina* 2011;31(8):1603-8.

98. Dinc UA, Tatlipinar S, Yenerel M, et al. Fundus autofluorescence in acute and chronic central serous chorioretinopathy. *Clin Exp Optom* 2011;94(5):452-7.
99. Spaide RF, Campeas L, Haas A, et al. Central serous chorioretinopathy in younger and older adults. *Ophthalmology* 1996;103(12):2070-9; discussion 9-80.
100. Quin G, Liew G, Ho IV, et al. Diagnosis and interventions for central serous chorioretinopathy: review and update. *Clin Experiment Ophthalmol* 2013;41(2):187-200.
101. Gemenetzi M, De Salvo G, Lotery AJ. Central serous chorioretinopathy: an update on pathogenesis and treatment. *Eye (Lond)* 2010;24(12):1743-56.
102. Polak BC, Baarsma GS, Snyers B. Diffuse retinal pigment epitheliopathy complicating systemic corticosteroid treatment. *Br J Ophthalmol* 1995;79(10):922-5.
103. von Winning CH, Oosterhuis JA, Renger-van Dijk AH, et al. Diffuse retinal pigment epitheliopathy. *Ophthalmologica* 1982;185(1):7-14.
104. Guyer DR, Yannuzzi LA, Slakter JS, et al. Digital indocyanine green videoangiography of central serous chorioretinopathy. *Arch Ophthalmol* 1994;112(8):1057-62.
105. Park SJ, Kim BH, Park KH, Woo SJ. Punctate hyperfluorescence spot as a common choroidopathy of central serous chorioretinopathy and polypoidal choroidal vasculopathy. *Am J Ophthalmol* 2014.
106. Wang M, Sander B, la Cour M, Larsen M. Clinical characteristics of subretinal deposits in central serous chorioretinopathy. *Acta Ophthalmol Scand* 2005;83(6):691-6.
107. Song IS, Shin YU, Lee BR. Time-periodic characteristics in the morphology of idiopathic central serous chorioretinopathy evaluated by volume scan using spectral-domain optical coherence tomography. *Am J Ophthalmol* 2012;154(2):366-75 e4.
108. Iida T, Yannuzzi LA, Spaide RF, et al. Cystoid macular degeneration in chronic central serous chorioretinopathy. *Retina* 2003;23(1):1-7; quiz 137-8.
109. Imamura Y, Fujiwara T, Spaide RF. Fundus autofluorescence and visual acuity in central serous chorioretinopathy. *Ophthalmology* 2011;118(4):700-5.
110. Teke MY, Elgin U, Nalcacioglu-Yuksekkaya P, et al. Comparison of autofluorescence and optical coherence tomography findings in acute and chronic central serous chorioretinopathy. *International journal of ophthalmology* 2014;7(2):350-4.
111. Yannuzzi LA, Shakin JL, Fisher YL, Altomonte MA. Peripheral retinal detachments and retinal pigment epithelial atrophic tracts secondary to central serous pigment epitheliopathy. *Ophthalmology* 1984;91(12):1554-72.
112. Delori FC, Dorey CK, Staurengi G, et al. In vivo fluorescence of the ocular fundus exhibits retinal pigment epithelium lipofuscin characteristics. *Invest Ophthalmol Vis Sci* 1995;36(3):718-29.
113. Hayashi K, Hasegawa Y, Tokoro T. Indocyanine green angiography of central serous chorioretinopathy. *Int Ophthalmol* 1986;9(1):37-41.
114. Gupta P, Gupta V, Dogra MR, et al. Morphological changes in the retinal pigment epithelium on spectral-domain OCT in the unaffected eyes with idiopathic central serous chorioretinopathy. *Int Ophthalmol* 2010;30(2):175-81.

115. Tittl M, Maar N, Polska E, et al. Choroidal hemodynamic changes during isometric exercise in patients with inactive central serous chorioretinopathy. *Invest Ophthalmol Vis Sci* 2005;46(12):4717-21.
116. Haimovici R, Rumelt S, Melby J. Endocrine abnormalities in patients with central serous chorioretinopathy. *Ophthalmology* 2003;110(4):698-703.
117. Shang Q, Liu C, Wei S, et al. [Determination of cortisol in plasma and 24-hour urine of patients with central serous chorioretinopathy]. *Zhonghua Yan Ke Za Zhi* 1999;35(4):297-9.
118. Tufan HA, Gencer B, Comez AT. Serum cortisol and testosterone levels in chronic central chorioretinopathy. *Graefes Arch Clin Exp Ophthalmol* 2013;251(3):677-80.
119. Zakir SM, Shukla M, Simi ZU, et al. Serum cortisol and testosterone levels in idiopathic central serous chorioretinopathy. *Indian J Ophthalmol* 2009;57(6):419-22.
120. Yannuzzi LA. Type A behavior and central serous chorioretinopathy. *Trans Am Ophthalmol Soc* 1986;84:799-845.
121. Gemenetzi M, De Salvo G, Lotery AJ. Central serous chorioretinopathy: an update on pathogenesis and treatment. *Eye (Lond)* 2010;24(12):1743-56.
122. Zhao M, Celerier I, Bousquet E, et al. Mineralocorticoid receptor is involved in rat and human ocular chorioretinopathy. *J Clin Invest* 2012;122(7):2672-9.
123. Klein ML, Van Buskirk EM, Friedman E, et al. Experience with nontreatment of central serous choroidopathy. *Arch Ophthalmol* 1974;91(4):247-50.
124. Hagen S, Ansari-Shahrezaei S, Smretschmig E, et al. The effect of photodynamic therapy on macular sensitivity in eyes with acute central serous chorioretinopathy. *Graefes Arch Clin Exp Ophthalmol* 2013;251(4):1081-9.
125. Chan WM, Lai TY, Lai RY, et al. Half-dose verteporfin photodynamic therapy for acute central serous chorioretinopathy: one-year results of a randomized controlled trial. *Ophthalmology* 2008;115(10):1756-65.
126. Smretschmig E, Ansari-Shahrezaei S, Moussa S, et al. Half-fluence photodynamic therapy in acute central serous chorioretinopathy. *Retina* 2012;32(10):2014-9.
127. Klatt C, Saeger M, Oppermann T, et al. Selective retina therapy for acute central serous chorioretinopathy. *Br J Ophthalmol* 2011;95(1):83-8.
128. Wang MS, Sander B, Larsen M. Retinal atrophy in idiopathic central serous chorioretinopathy. *Am J Ophthalmol* 2002;133(6):787-93.
129. Salehi M, Wenick AS, Law HA, et al. Interventions for central serous chorioretinopathy: a network meta-analysis. *Cochrane Database Syst Rev* 2015;12:CD011841.
130. Negi A, Marmor MF. Experimental serous retinal detachment and focal pigment epithelial damage. *Arch Ophthalmol* 1984;102(3):445-9.
131. Leaver P, Williams C. Argon laser photocoagulation in the treatment of central serous retinopathy. *Br J Ophthalmol* 1979;63(10):674-7.
132. Watzke RC, Burton TC, Leaverton PE. Ruby laser photocoagulation therapy of central serous retinopathy. I. A controlled clinical study. II. Factors affecting prognosis. *Trans Am Acad Ophthalmol Otolaryngol* 1974;78(2):OP205-11.

133. Robertson DM, Ilstrup D. Direct, indirect, and sham laser photocoagulation in the management of central serous chorioretinopathy. *Am J Ophthalmol* 1983;95(4):457-66.
134. Schatz H, Yannuzzi LA, Gitter KA. Subretinal neovascularization following argon laser photocoagulation treatment for central serous chorioretinopathy: complication or misdiagnosis? *Trans Sect Ophthalmol Am Acad Ophthalmol Otolaryngol* 1977;83(5):893-906.
135. Gilbert CM, Owens SL, Smith PD, Fine SL. Long-term follow-up of central serous chorioretinopathy. *Br J Ophthalmol* 1984;68(11):815-20.
136. Schmidt-Erfurth U, Laqua H, Schlotzer-Schrehard U, et al. Histopathological changes following photodynamic therapy in human eyes. *Arch Ophthalmol* 2002;120(6):835-44.
137. Schlotzer-Schrehard U, Viestenz A, Naumann GO, et al. Dose-related structural effects of photodynamic therapy on choroidal and retinal structures of human eyes. *Graefes Arch Clin Exp Ophthalmol* 2002;240(9):748-57.
138. Chan WM, Lam DS, Lai TY, et al. Choroidal vascular remodelling in central serous chorioretinopathy after indocyanine green guided photodynamic therapy with verteporfin: a novel treatment at the primary disease level. *Br J Ophthalmol* 2003;87(12):1453-8.
139. Silva RM, Ruiz-Moreno JM, Gomez-Ulla F, et al. Photodynamic therapy for chronic central serous chorioretinopathy: a 4-year follow-up study. *Retina* 2013;33(2):309-15.
140. Lim JJ, Glassman AR, Aiello LP, et al. Collaborative retrospective macula society study of photodynamic therapy for chronic central serous chorioretinopathy. *Ophthalmology* 2014;121(5):1073-8.
141. Rouvas A, Stavarakas P, Theodossiadis PG, et al. Long-term results of half-fluence photodynamic therapy for chronic central serous chorioretinopathy. *Eur J Ophthalmol* 2012;22(3):417-22.
142. Chan WM, Lim TH, Pece A, et al. Verteporfin PDT for non-standard indications--a review of current literature. *Graefes Arch Clin Exp Ophthalmol* 2010;248(5):613-26.
143. Chan WM, Lai TY, Lai RY, et al. Safety enhanced photodynamic therapy for chronic central serous chorioretinopathy: one-year results of a prospective study. *Retina* 2008;28(1):85-93.
144. Valmaggia C, Haueter I, Niederberger H. Photodynamic therapy in the treatment of persistent central serous chorioretinopathy: a two-year follow-up. *Klin Monbl Augenheilkd* 2012;229(4):323-6.
145. Fujita K, Imamura Y, Shinoda K, et al. One-year outcomes with half-dose verteporfin photodynamic therapy for chronic central serous chorioretinopathy. *Ophthalmology* 2015;122(3):555-61.
146. Reibaldi M, Cardascia N, Longo A, et al. Standard-fluence versus low-fluence photodynamic therapy in chronic central serous chorioretinopathy: a nonrandomized clinical trial. *Am J Ophthalmol* 2010;149(2):307-15 e2.
147. Lai TY, Chan WM, Li H, et al. Safety enhanced photodynamic therapy with half dose verteporfin for chronic central serous chorioretinopathy: a short term pilot study. *Br J Ophthalmol* 2006;90(7):869-74.
148. Nicolo M, Eandi CM, Alovisi C, et al. Half-fluence versus half-dose photodynamic therapy in chronic central serous chorioretinopathy. *Am J Ophthalmol* 2014;157(5):1033-7.
149. Boni C, Kloos P, Valmaggia C, Department of Ophthalmology CHSGSGS. New guidelines in the treatment of persistent central serous chorioretinopathy: PDT with half-dose verteporfin. *Klin Monbl Augenheilkd* 2012;229(4):327-30.

150. Uetani R, Ito Y, Oiwa K, et al. Half-dose vs one-third-dose photodynamic therapy for chronic central serous chorioretinopathy. *Eye (Lond)* 2012;26(5):640-9.
151. Ma J, Meng N, Xu X, et al. System review and meta-analysis on photodynamic therapy in central serous chorioretinopathy. *Acta Ophthalmol* 2014;92(8):e594-601.
152. Kim YK, Ryoo NK, Woo SJ, Park KH. Comparison of visual and anatomical outcomes of half-fluence and half-dose photodynamic therapy in eyes with chronic central serous chorioretinopathy. *Graefes Arch Clin Exp Ophthalmol* 2015.
153. Shiode Y, Morizane Y, Kimura S, et al. Comparison of halving the irradiation time or the verteporfin dose in photodynamic therapy for chronic central serous chorioretinopathy. *Retina* 2015;35(12):2498-504.
154. Elsner H, Porksen E, Klatt C, et al. Selective retina therapy in patients with central serous chorioretinopathy. *Graefes Arch Clin Exp Ophthalmol* 2006;244(12):1638-45.
155. Malik KJ, Sampat KM, Mansouri A, et al. Low-intensity/high-density subthreshold microPulse diode laser for chronic central serous chorioretinopathy. *Retina* 2015;35(3):532-6.
156. Sivaprasad S, Elagouz M, McHugh D, et al. Micropulsed diode laser therapy: evolution and clinical applications. *Surv Ophthalmol* 2010;55(6):516-30.
157. Luttrull JK, Dorin G. Subthreshold diode micropulse laser photocoagulation (SDM) as invisible retinal phototherapy for diabetic macular edema: a review. *Curr Diabetes Rev* 2012;8(4):274-84.
158. Scholz P, Ersoy L, Boon CJ, Fauser S. Subthreshold Micropulse Laser (577 nm) Treatment in Chronic Central Serous Chorioretinopathy. *Ophthalmologica* 2015;234(4):189-94.
159. Lanzetta P, Furlan F, Morgante L, et al. Nonvisible subthreshold micropulse diode laser (810 nm) treatment of central serous chorioretinopathy. A pilot study. *Eur J Ophthalmol* 2008;18(6):934-40.
160. Koss MJ, Beger I, Koch FH. Subthreshold diode laser micropulse photocoagulation versus intravitreal injections of bevacizumab in the treatment of central serous chorioretinopathy. *Eye (Lond)* 2012;26(2):307-14.
161. Shin MC, Lim JW. Concentration of cytokines in the aqueous humor of patients with central serous chorioretinopathy. *Retina* 2011;31(9):1937-43.
162. Lim JW, Kim MU, Shin MC. Aqueous humor and plasma levels of vascular endothelial growth factor and interleukin-8 in patients with central serous chorioretinopathy. *Retina* 2010;30(9):1465-71.
163. Chung YR, Seo EJ, Lew HM, Lee KH. Lack of positive effect of intravitreal bevacizumab in central serous chorioretinopathy: meta-analysis and review. *Eye (Lond)* 2013;27(12):1339-46.
164. Semeraro F, Romano MR, Danzi P, et al. Intravitreal bevacizumab versus low-fluence photodynamic therapy for treatment of chronic central serous chorioretinopathy. *Jpn J Ophthalmol* 2012;56(6):608-12.
165. Huang WC, Chen WL, Tsai YY, et al. Intravitreal bevacizumab for treatment of chronic central serous chorioretinopathy. *Eye (Lond)* 2009;23(2):488-9.
166. Lim JW, Ryu SJ, Shin MC. The effect of intravitreal bevacizumab in patients with acute central serous chorioretinopathy. *Korean J Ophthalmol* 2010;24(3):155-8.
167. Peiretti E, Ferrara DC, Caminiti G, Mura M, Hughes J. Choroidal neovascularization in caucasian patients with longstanding central serous chorioretinopathy. *Retina* 2015;35(7):1360-7


168. Konstantinidis L, Mantel I, Zografos L, Ambresin A. Intravitreal ranibizumab in the treatment of choroidal neovascularization associated with idiopathic central serous chorioretinopathy. *Eur J Ophthalmol* 2010;20(5):955-8.
169. Caccavale A, Romanazzi F, Imparato M, et al. Low-dose aspirin as treatment for central serous chorioretinopathy. *Clin Ophthalmol* 2010;4:899-903.
170. Nielsen JS, Jampol LM. Oral mifepristone for chronic central serous chorioretinopathy. *Retina* 2011;31(9):1928-36.
171. Pikkell J, Beiran I, Ophir A, Miller B. Acetazolamide for central serous retinopathy. *Ophthalmology* 2002;109(9):1723-5.
172. Dang Y, Mu Y, Zhao M, et al. The effect of eradicating *Helicobacter pylori* on idiopathic central serous chorioretinopathy patients. *Ther Clin Risk Manag* 2013;9:355-60.
173. Bousquet E, Beydoun T, Zhao M, et al. Mineralocorticoid receptor antagonism in the treatment of chronic central serous chorioretinopathy: a pilot study. *Retina* 2013;33(10):2096-102.
174. Zhao M, Celerier I, Bousquet E, et al. Mineralocorticoid receptor is involved in rat and human ocular chorioretinopathy. *J Clin Invest* 2012;122(7):2672-9.
175. Green WR, Enger C. Age-related macular degeneration histopathologic studies. The 1992 Lorenz E. Zimmerman Lecture. *Ophthalmology* 1993;100(10):1519-35.
176. Loo RH, Scott IU, Flynn HW, Jr., et al. Factors associated with reduced visual acuity during long-term follow-up of patients with idiopathic central serous chorioretinopathy. *Retina* 2002;22(1):19-24.
177. Park HS, Kim IT. Clinical characteristics of polypoidal choroidal vasculopathy associated with chronic central serous chorioretinopathy. *Korean J Ophthalmol* 2012;26(1):15-20.
178. Evans JR, Henshaw K. Antioxidant vitamin and mineral supplements for preventing age-related macular degeneration. *Cochrane Database Syst Rev* 2008(1):CD000253.
179. Lally DR, Gerstenblith AT, Regillo CD. Preferred therapies for neovascular age-related macular degeneration. *Curr Opin Ophthalmol* 2012;23(3):182-8.
180. Yannuzzi LA, Freund KB, Goldbaum M, et al. Polypoidal choroidal vasculopathy masquerading as central serous chorioretinopathy. *Ophthalmology* 2000;107(4):767-77.
181. Coscas G, Lupidi M, Coscas F, et al. Toward a specific classification of polypoidal choroidal vasculopathy: idiopathic disease or subtype of age-related macular degeneration. *Invest Ophthalmol Vis Sci* 2015;56(5):3187-95.
182. Laude A, Cackett PD, Vithana EN, et al. Polypoidal choroidal vasculopathy and neovascular age-related macular degeneration: same or different disease? *Prog Retin Eye Res* 2010;29(1):19-29.
183. Sasahara M, Tsujikawa A, Musashi K, et al. Polypoidal choroidal vasculopathy with choroidal vascular hyperpermeability. *Am J Ophthalmol* 2006;142(4):601-7.
184. Balaratnasingam C, Lee WK, Koizumi H, et al. Polypoidal choroidal vasculopathy: a distinct disease or manifestation of many? *Retina* 2016;36(1):1-8.
185. Alasil T, Ferrara D, Adhi M, et al. En face imaging of the choroid in polypoidal choroidal vasculopathy using swept-source optical coherence tomography. *Am J Ophthalmol* 2015;159(4):634-43.
186. Ooto S, Tsujikawa A, Mori S, et al. Retinal microstructural abnormalities in central serous chorioretinopathy and polypoidal choroidal vasculopathy. *Retina* 2011;31(3):527-34.

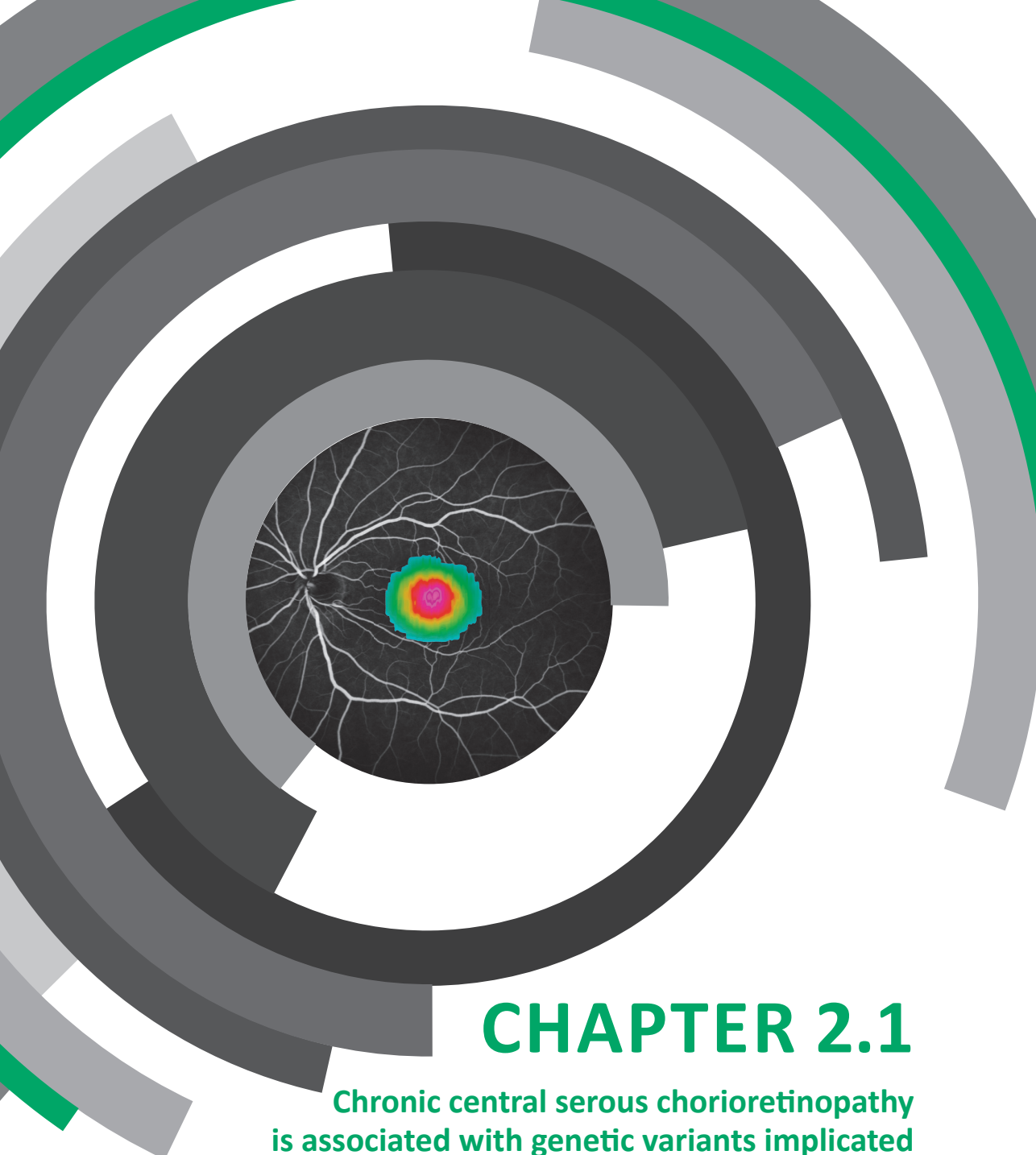
187. Sato T, Kishi S, Watanabe G, et al. Tomographic features of branching vascular networks in polypoidal choroidal vasculopathy. *Retina* 2007;27(5):589-94.
188. Gomi F, Oshima Y, Mori R, et al. Initial versus delayed photodynamic therapy in combination with ranibizumab for treatment of polypoidal choroidal vasculopathy: the fujisan study. *Retina* 2015;35(8):1569-76.
189. Wong cw, cheung cm, mathur r, et al. Three-year results of polypoidal choroidal vasculopathy treated with photodynamic therapy: retrospective study and systematic review. *Retina* 2015;35(8):1577-93.
190. Koh A, Lee WK, Chen LJ, et al. EVEREST study: efficacy and safety of verteporfin photodynamic therapy in combination with ranibizumab or alone versus ranibizumab monotherapy in patients with symptomatic macular polypoidal choroidal vasculopathy. *Retina* 2012;32(8):1453-64.
191. Errera MH, Michaelides M, Keane PA, et al. The extended clinical phenotype of dome-shaped macula. *Graefes Arch Clin Exp Ophthalmol* 2014;252(3):499-508.
192. Nakanishi H, Tsujikawa A, Gotoh N, et al. Macular complications on the border of an inferior staphyloma associated with tilted disc syndrome. *Retina* 2008;28(10):1493-501.
193. Gaucher D, Erginay A, Leclaire-Collet A, et al. Dome-shaped macula in eyes with myopic posterior staphyloma. *Am J Ophthalmol* 2008;145(5):909-14.
194. Chinskey ND, Johnson MW. Treatment of subretinal fluid associated with dome-shaped macula. *Ophthalmic surgery, lasers & imaging retina* 2013;44(6):593-5.
195. Dansingani KK, Balaratnasingam C, Naysan J, Freund KB. En Face Imaging of pachychoroid spectrum disorders with swept-source optical coherence tomography. *Retina* 2015.
196. Pang CE, Freund KB. Pachychoroid neovascularization. *Retina* 2015;35(1):1-9.
197. Shields CL, Honavar SG, Shields JA, et al. Circumscribed choroidal hemangioma: clinical manifestations and factors predictive of visual outcome in 200 consecutive cases. *Ophthalmology* 2001;108(12):2237-48.
198. Karimi S, Nourinia R, Mashayekhi A. Circumscribed choroidal hemangioma. *Journal of ophthalmic & vision research* 2015;10(3):320-8.
199. Photodynamic therapy of subfoveal choroidal neovascularization in age-related macular degeneration with verteporfin: one-year results of 2 randomized clinical trials--TAP report. Treatment of age-related macular degeneration with photodynamic therapy (TAP) Study Group. *Arch Ophthalmol* 1999;117(10):1329-45.
200. Talli PM, Fantaguzzi PM, Bendo E, Pazzaglia A. Vitrectomy without laser treatment for macular serous detachment associated with optic disc pit: long-term outcomes. *Eur J Ophthalmol* 2015:0.
201. Ooto S, Mittra RA, Ridley ME, Spaide RF. Vitrectomy with inner retinal fenestration for optic disc pit maculopathy. *Ophthalmology* 2014;121(9):1727-33.
202. Schoenberger SD, Kim SJ. Bilateral multifocal central serous-like chorioretinopathy due to MEK inhibition for metastatic cutaneous melanoma. *Case reports in ophthalmological medicine* 2013;2013:673796.

203. van Dijk EH, van Herpen CM, Marinkovic M, et al. Serous retinopathy associated with mitogen-activated protein kinase kinase inhibition (binimetinib) for metastatic cutaneous and uveal Melanoma. *Ophthalmology* 2015;122(9):1907-16.

CHAPTER 2

Genetic studies in chronic central serous chorioretinopathy





CHAPTER 2.1

Chronic central serous chorioretinopathy is associated with genetic variants implicated in age-related macular degeneration

Eiko K. de Jong*, Myrte B. Breukink*, Rosa L. Schellevis, Bjorn Bakker, Jacqueline K. Mohr-Karsenberg,
Sascha Fauser, Jan E.E. Keunen, Carel B. Hoyng, Anneke I. den Hollander & Camiel J.F. Boon

Published in: *Ophthalmology*. 2015;122(3):562-70
(*joint first author)

Purpose:

In this study, single nucleotide polymorphisms (SNPs) at 19 loci, previously associated with age-related macular degeneration (AMD), were systematically tested for association in patients with chronic central serous chorioretinopathy (CSC). In addition, we evaluated the effect of detailed phenotyping on these genetic associations.

Methods:

A case-control study with 292 chronic CSC patients, 1147 AMD patients, and 1311 control individuals. SNPs at 19 AMD-associated loci and six additional SNPs at the *Complement Factor H (CFH)* locus were genotyped. Phenotyping of all patients was based on funduscopy, spectral-domain optical coherence tomography, fluorescein angiography (FA) and indocyanine green angiography.

Results:

One SNP in *ARMS2* (rs10490924) was significant after Bonferroni correction ($P_{\text{unadjusted}} = 0.002$, OR = 0.64). SNPs at three other AMD loci (*CFH*, *TNFRSF10A*, *ADAMTS9*) showed a trend towards association with typical chronic CSC. Further analysis of the *CFH* locus identified two SNPs that significantly conferred increased risk for chronic CSC and one that was protective. The *CFH*-H3 haplotype was also found to be protective ($P = 0.01$, OR = 0.54). Using multimodal imaging, 197 patients were classified as typical chronic CSC, 52 patients had unilateral abnormalities on FA that were otherwise typical of chronic CSC, and 43 patients had a clinical picture that could be compatible with chronic CSC, but with features that could also indicate other macular diseases. Significant differences of the minor allele frequencies of the tested SNPs were observed between these three phenotypic subgroups.

Conclusions:

Chronic CSC is associated with genetic variants in *ARMS2* and *CFH*, indicating a genetic and pathophysiologic overlap between chronic CSC and AMD. Intriguingly, alleles in *ARMS2* and *CFH* that confer risk of AMD may be protective for chronic CSC, while alleles in *CFH* that are protective for AMD confer risk for chronic CSC. Significant differences in allele frequencies were seen among the phenotypic subgroups for several SNPs, illustrating the importance of correct clinical classification.

Introduction

Central serous chorioretinopathy (CSC) is one of the most common forms of macular disease in the Western world.^{1, 2} It is characterized by a serous detachment of the neuroretina from the underlying retinal pigment epithelium (RPE) in the macula, due to fluid leakage through a dysfunctional RPE. Clinical evidence from multimodal imaging, such as choroidal congestion, thickening and hyperpermeability of the choroid, implies an important role for choroidal abnormalities as an underlying cause for RPE dysfunction and subretinal fluid leakage in CSC.¹⁻³

Two main subtypes of CSC can be distinguished. Patients with acute CSC present with sudden and marked central vision loss. Acute CSC is characterized by a focal leakage spot on fluorescein angiography (FA), beneath a macular neurosensory retinal detachment.¹⁻⁹ This so called ‘hot spot’ indicates leakage at the level of the RPE.^{1, 4, 10} The acute form of CSC generally has a favorable prognosis because the accumulated subretinal fluid often subsides spontaneously within 2-3 months, with (near-)normal recovery of vision (**Figure 1A-C**).¹ In contrast, chronic CSC is typically not self-limiting and subretinal fluid remains present longer than 3 months.^{2, 4, 10} Patients have more diffuse multifocal leakage on FA and indocyanine green (ICG) angiography, and often irregularly distributed widespread RPE changes associated with various degrees of low-grade leakage (**Figure 1D-F**).¹⁻¹⁰ Because of persistent serous neuroretinal detachments with progressive and irreversible photoreceptor damage, chronic CSC has a poorer visual prognosis than acute CSC.^{2, 6, 11, 12}

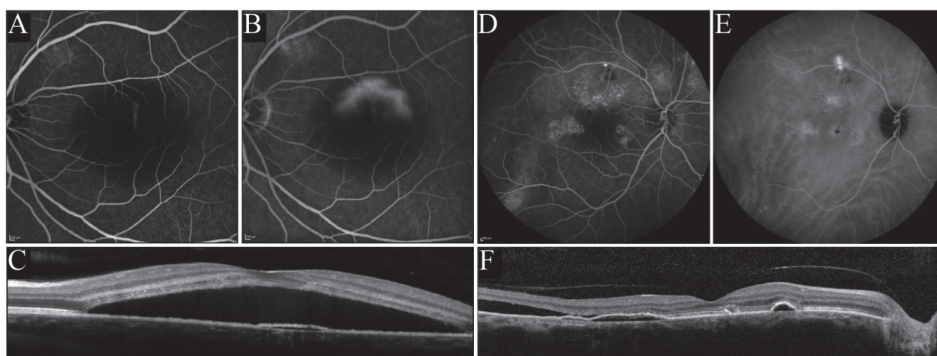


Figure 1.

Examples of fluorescein angiography (FA), indocyanine green (ICG) angiography and spectral-domain optical coherence tomography (SD-OCT) in acute and chronic central serous chorioretinopathy (CSC). (**A-C**) The left eye of a patient with classical acute CSC, showing a small focal leak in the early phase of FA, and a typical smokestack fluorescein leak on late-phase FA (**A-B**) and the corresponding SD-OCT image showed a large central subretinal fluid (SRF) accumulation associated with a focal shallow retinal pigment epithelial (RPE) detachment(**C**). (**D-E**) The right eye of a patient with chronic CSC with more widespread leakage on FA (**D**), and diffuse hyperfluorescent areas on ICG angiography (**E**), as well as SRF and multiple RPE detachments on SD-OCT (**F**).

Although the etiology of CSC is largely obscure, clinical observations point towards an association with the use of corticosteroids, hypercortisolism, stress and type A personality.^{1-10,13} The incidence of CSC is approximately six times higher in men than in women,¹ although this male-to-female proportion seems to be less pronounced in chronic CSC and steroid-related CSC.

Interracial differences in the prevalence of chronic CSC and the familial occurrence of chronic CSC suggest a strong genetic involvement.^{2,14-16} However, only a limited number of possible genetic associations have been reported so far.^{17,18} Certain phenotypic features of chronic CSC such as serous RPE detachments, neurosensory retinal detachment and patchy atrophy of the RPE are also observed in other macular diseases, like age-related macular degeneration (AMD) and polypoidal choroidal vasculopathy.¹⁹ This phenotypic overlap suggests that a genetic overlap may also exist.

AMD is known to be a multifactorial and genetically complex disorder, and 19 genetic loci have been identified to be associated with the disease.²⁰⁻²²

In order to assess the degree of phenotypic and genotypic overlap between chronic CSC and AMD, this study used a combination of detailed phenotyping based on multimodal imaging and systematic analyses of SNPs at the known 19 AMD-associated loci in chronic CSC patients. Furthermore, a detailed analysis of *CFH* haplotypes in chronic CSC patients was performed. Finally, the effect of phenotypic differentiation on these genetic associations was evaluated.

Methods

Participants

In this study, we included 292 patients with chronic CSC who visited the outpatient clinic of the Department of Ophthalmology at the Radboud University Medical Center, Nijmegen, the Netherlands (**Table 1**). The diagnosis chronic CSC and phenotyping with multimodal imaging was based on an extensive ophthalmological examination including fundoscopy, spectral-domain optical coherence tomography (SD-OCT), FA and ICG angiography. The definition of chronic CSC used in this study was based on the currently available literature, taking the following characteristics into account that all had to be present: serous subretinal fluid on OCT, one or more areas of multifocal diffuse leakage on FA, and corresponding hyperfluorescence on ICG angiography in at least one eye.¹⁻¹⁰ Patients suffering from acute CSC as recognized by a focal leakage spot or a smokestack pattern on FA, and patients with a disease period under three months, were excluded.¹⁻¹⁰ A total of 1311 control subjects were recruited from the blood bank of the Radboud University Medical Center, Nijmegen, The Netherlands (n = 177), and the European Genetic Database (EUGENDA, www.eugenda.org) (n = 1134). For control subjects recruited from EUGENDA ophthalmological grading was performed excluding signs of AMD. In addition, 1147 AMD patients from the European Genetic Database (EUGENDA, www.eugenda.org) were used for calculation of the minor allele frequencies of SNPs at AMD-associated loci (**Table 1**). The diagnosis of AMD was defined as described previously.²³ Informed consent for the use of DNA for genetic studies was obtained from all subjects. The study adhered to the tenets of the Declaration of Helsinki. Institutional review board/ethics committee approval was obtained.

Table 1. Demographics of the study population

	Subgroup 1	Subgroup 2	Subgroup 3	Controls	AMD
Number of subjects	197	52	43	1311	1147
Sex (male/female)	(154/43)	(38/14)	(26/17)	(629/682)	(448/699)
Mean age \pm SD (years)	53 \pm 10	55 \pm 12	57 \pm 13	66 \pm 12	76 \pm 9
Age range (years)	29-74	32-78	30-78	19-97	55-101

AMD = age-related macular degeneration; SD = standard deviation

SNP genotyping

Genomic DNA was extracted from peripheral blood samples using standard procedures. Nineteen SNPs at loci previously associated with AMD (rs10490924 (*ARMS2*), rs12144939 (*CFH*), rs429608 (*C2-CFB*), rs2230199 (*C3*), rs9621532 (*TIMP3*), rs4420638 (*APOE*), rs3764261 (*CETP*), rs943080 (*VEGFA*), rs13278062 (*TNFRSF10A*), rs493258 (*LIPC*), rs10033900 (*CFI*), rs3812111 (*COL10A1*), rs13081855 (*COL8A1-FILIP1L*), rs3130783 (*IER3-DDR1*), rs8135665 (*SLC16A8*), rs334353 (*TGFBR1*), rs8017304 (*RAD51B*), rs6795735 (*ADAMTS9*)) and rs9542236 (*B3GALT1*)) were genotyped in 292 chronic CSC patients and 1311 controls by outsourcing to the genotyping service of LGC genomics (©LGC Limited, United Kingdom).²⁰⁻²²

Genotyping of six *CFH* SNPs (rs1061170, rs3753394, rs800292, rs2284664, rs1329428, rs1065489) was performed with KASP™ genotyping assays (LGC Genomics) in 292 chronic CSC patients and 881 controls. SNP-specific KASP primer mix and KASP master mix were added to 10ng DNA according to the manufacturer's instructions. PCR amplification was performed (Veriti 384 thermal cycler, Applied Biosystems). Fluorescent FAM and HEX signals were read out with the 7900HT Fast Real-Time PCR System (Applied Biosystems) and converted to genotype information with the SDS program (version 2.3 Applied Biosystems).

Statistical Analysis

Differences in allele frequencies were calculated using the Fisher's Exact test (two sided for the 19 AMD-loci and one-sided for *CFH* SNPs based on previous reports), and a Bonferroni correction was performed. The individual tests for the 19 AMD-loci were considered significant for P-values less than 0.0026, corrected for 19 tests. The significance threshold for the six *CFH* variants was set at $P < 0.0083$, correcting for six tests.

Haplotypes were generated with R (version 3.0.2) and R Studio (version 0.98.501), using the haplo.stats package (version 1.6.8). For each SNP, information for both alleles was inserted into R and the haplo.cc command was used to determine associations between haplotype frequencies and chronic CSC. The most frequent haplotypes (frequency in controls > 5%) were named H1-H5 according to the nomenclature described by Hageman et al.²⁴ Haplotypes were considered to be significantly associated to CSC if $P < 0.01$, correcting for five tests. Minor allele frequencies of significantly associated SNPs were compared between subgroups of CSC using a Fisher's exact test, and were considered significant if $P < 0.0125$, correcting for four test.

Results

Phenotyping and classification of chronic CSC patients

All chronic CSC patients were classified into three subgroups based on their phenotypic characteristics on multimodal imaging. Patients in phenotypic subgroup 1 (n = 197) showed the most typical clinical picture of chronic CSC. This typical picture was defined as the presence of chronic serous subretinal fluid in at least one eye on SD-OCT, bilateral irregular RPE window defects on FA with at least one “hot spot” of leakage in the affected eye(s), and corresponding hyperfluorescent zones on ICG angiography (**Figure 2A-B**). No evidence of choroidal neovascularization, polypoidal choroidal vasculopathy, or other atypical findings were seen in this subgroup.

Phenotypic subgroup 2 (n = 52) included patients with unilateral (instead of bilateral) abnormalities on FA that were otherwise typical for chronic CSC. Additionally, subgroup 2 included patients with no clear “hot spot” and/or more focal leakage on FA, with an absence of subretinal fluid on SD-OCT but otherwise typical FA features of chronic CSC. Also, patients in whom ICG angiography imaging did not show clear hyperfluorescence corresponding to FA abnormalities were included in subgroup 2 (**Figure 2C-D**). Furthermore, these patients showed no evidence of choroidal neovascularization, polypoidal choroidal vasculopathy, or other atypical findings.

For patients in phenotypic subgroup 3 (n = 43), the clinical picture was primarily compatible with chronic CSC, but with more atypical features suggestive of other macular diseases, or possibly constituted a combination of chronic CSC and another diagnosis. For instance, atypical clinical features in patients in subgroup 3 included evidence of choroidal neovascularisation, the presence of drusen, or (highly) myopic fundus changes (**Figure 2E-F**).

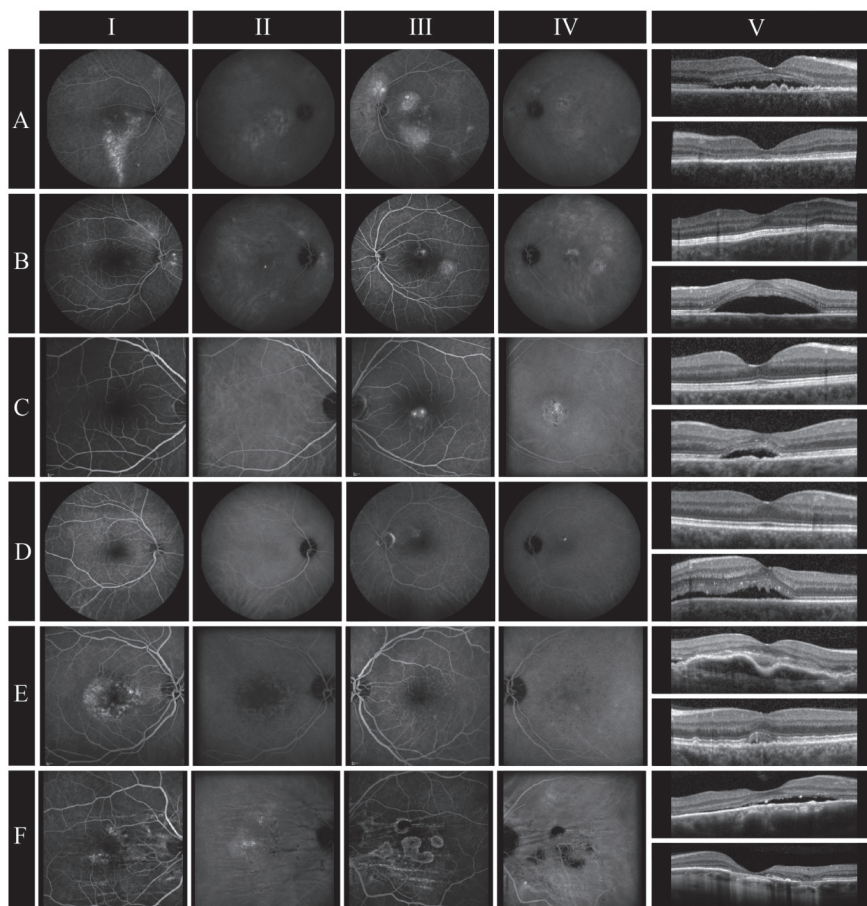


Figure 2.

Examples of fluorescein angiography (FA; of right eyes (RE): column **I**, of left eyes (LE): column **III**), indocyanine green angiography (ICG angiography of RE: column **II**, of LE: column **IV**) and spectral-domain optical coherence tomography (SD-OCT; of RE: upper images of column **V**, of LE: lower images of column **V**) imaging of each phenotypic subgroup. **(A-B)** The RE and LE of two patients representing subgroup 1, demonstrating diffuse areas of leakage on FA and ICG angiography (**A/I-II**, **B/III-IV**) and subretinal fluid (SRF) beneath the fovea (**A/V** (upper image), **B/V** (lower image)), illustrative for typical active chronic central serous chorioretinopathy (chronic CSC). **(A/I)** A classic example of a gravitational tract on FA in chronic CSC. The fellow eyes of these patients did not have SRF on SD-OCT (**A/V** (lower image), **B/V** (upper image)), but had clear hyperfluorescent areas on FA and ICG angiography indicating chronic CSC without active leakage (**A/III-IV**, **B/I-II**). **(C-D)** Imaging of two patients belonging to subgroup 2 with unilateral, more localized leakage on FA and ICG angiography (**C/III-IV**, **D/III-IV**) and central SRF on SD-OCT (**C/V** (lower image), **D/V** (lower image)). **(E-F)** The RE and LE of two patients as an example of subgroup 3. In the first patient an irregular hyperfluorescent pattern was seen on FA and ICG angiography of the right eye (**E/I-II**). SD-OCT showed a large retinal pigment epithelium detachment in association with serous SRF (**E/V** (upper image)). In the fellow eye central mild hyperfluorescence was seen on FA with hypofluorescence on ICG angiography (**E/III-IV**). Also, minimal central SRF was present on SD-OCT (**E/V** (lower image)). The second patient had diffuse leakage on FA and ICG angiography (**F/I-II**) accompanied by SRF on SD-OCT (**F/V** (upper image)) in the right eye. Imaging of the left eye showed multifocal areas of atrophy on FA and ICG angiography (**F/III-IV**) and retinal atrophy on SD-OCT (**F/V**). Both eyes had choroidal folds on FA and ICG angiography (**F/I-IV**).

Association of SNPs at AMD loci with chronic CSC

To investigate the extent to which chronic CSC and AMD overlap genetically, the association of 19 SNPs at previously described AMD loci was tested in 197 typical chronic CSC patients (subgroup1) versus 1311 controls (**Table 2**).

Of these 19 loci, only rs10490924 in *ARMS2* remained significant ($P = 0.002$, OR = 0.64) after correcting for multiple testing (**Table 2**).

Association of CFH SNPs and haplotypes with chronic CSC

To investigate the *CFH* locus in more detail, we tested six additional SNPs for association in 197 typical chronic CSC patients (subgroup 1), and 881 controls (**Table 3**).

After correction for multiple testing two *CFH* SNPs conferred an increased risk for chronic CSC (rs800292, $P = 7.5 \times 10^{-4}$, OR = 1.50 and rs1329428, $P = 4.6 \times 10^{-4}$, OR = 1.47) and one SNP was protective (rs1065489, $P = 0.003$, OR = 0.63) (**Table 3**).

Out of the five observed *CFH* haplotypes, H3 (TGTCCT) was significantly associated ($P = 0.01$) with chronic CSC. The H3 haplotype was protective for the development of chronic CSC (OR = 0.54), being present in 15.7% of the control population and in 9% of chronic CSC patients. The H2 haplotype (CATTTG) showed a trend towards association ($P = 0.072$), conferring risk for chronic CSC (OR = 1.33) and being present in 20.8% of control individuals and in 25.8% of chronic CSC patients (**Table 4**).

Differences in minor allele frequencies of tested SNPs and haplotypes among phenotypic subgroups of chronic CSC

To investigate whether classifying chronic CSC into three distinct phenotypic subgroups had an effect on the underlying genetic associations, the minor allele frequencies of the significantly associated SNPs (rs10490924 (*ARMS2*), rs800292 (*CFH*), rs1329428 (*CFH*) and rs1065489 (*CFH*)) were compared between subgroups 1, 2 and 3 (**Table 5**).

When comparing chronic CSC subgroups 1 and 2, none of the SNPs showed a significant difference in frequency, suggesting that these subgroups are genetically similar. When the atypical patients (subgroup 3) were compared to subgroup 1, rs10490924 in *ARMS2* ($P = 0.002$) and rs800292 in *CFH* ($P = 0.002$) showed a significant difference in allele frequencies between these clinical subgroups, suggesting that subgroup 1 and 3 are genetically different (**Table 5**).

Table 2. Analysis of 19 age-related macular degeneration loci in chronic central serous chorioretinopathy

SNP (locus)	Alleles (Major/Minor)	MAF subgroup 1 (n=197)	MAF controls (n=1311)	Unadjusted Allelic P- value	Allelic Odds Ratio (95% CI)
rs10490924 (<i>ARMS2</i>)	G/T	0.17	0.24	0.002	0.64 (0.49-0.85)
rs12144939 (<i>CFH</i>)	G/T	0.25	0.20	0.031	1.33 (1.03-1.70)
rs429608 (<i>C2-CFH</i>)	G/A	0.16	0.13	0.133	1.25 (0.94-1.68)
rs2230199 (<i>C3</i>)	G/C	0.19	0.17	0.393	1.16(0.83-1.61)
rs9621532 (<i>TIMP3</i>)	A/C	0.05	0.05	0.807	1.05 (0.65-1.68)
rs4420638 (<i>APOE</i>)	A/G	0.16	0.17	0.470	0.89 (0.66-1.19)
rs3764261 (<i>CETP</i>)	G/T	0.30	0.32	0.484	0.92 (0.73-1.16)
rs943080 (<i>VEGFA</i>)	T/C	0.44	0.48	0.211	0.87 (0.70-1.08)
rs13278062 (<i>TNFRSF10A</i>)	T/G	0.40	0.48	0.004	0.73 (0.59-0.90)
rs493258 (<i>LIPC</i>)	C/T	0.49	0.46	0.064	1.23 (0.99-1.52)
rs10033900 (<i>CFI</i>)	C/T	0.50	0.48	0.514	1.08 (0.87-1.34)
rs3812111 (<i>COL10A1</i>)	A/T	0.34	0.36	0.498	0.92 (0.74-1.15)
rs13081855 (<i>COL8A1-FILIP1L</i>)	G/T	0.12	0.09	0.074	1.38 (0.98-1.93)
rs3130783 (<i>IER3-DDR1</i>)	A/G	0.20	0.19	0.836	1.03 (0.78-1.34)
rs8135665 (<i>SLC16A8</i>)	C/T	0.21	0.22	0.600	0.92 (0.71-1.20)
rs334353 (<i>TGFBR1</i>)	T/G	0.26	0.25	0.662	1.06 (0.83-1.35)
rs8017304 (<i>RAD51B</i>)	A/G	0.36	0.38	0.467	0.92 (0.73-1.14)
rs6795735 (<i>ADAMTS9</i>)	C/T	0.46	0.41	0.047	1.25 (1.01-1.54)
rs9542236 (<i>B3GALT1</i>)	T/C	0.44	0.44	1.000	1.01 (0.81-1.25)

SNP = single nucleotide polymorphism; MAF = minor allele frequency; CI = confidence interval
 For the analysis displayed in this table two sided P-values < 0.0026 were considered to be significant

Table 3. *Complement factor H* locus in chronic central serous chorioretinopathy.

SNP	Location	Alleles (Major/Minor)	MAF subgroup 1 (n=197)	MAF controls (n=881)	Unadjusted Allelic P-value	Allelic Odds Ratio (95% CI)
rs3753394	Promotor	C/T	0.245	0.295	0.027	0.78 (0.60-1.00)
rs800292 (I62V)	Exon 2	G/A	0.315	0.235	7.5 x 10 ⁻⁴	1.50 (1.18-1.90)
rs1061170 (Y402H)	Exon 9	T/C	0.310	0.350	0.065	0.83 (0.66-1.05)
rs2284664	Intron 15	C/T	0.276	0.218	0.009	1.37 (1.07-1.76)
rs1329428	Intron 15	C/T	0.526	0.431	4.6 x 10 ⁻⁴	1.47 (1.17-1.83)
rs1065489 (D936E)	Exon 18	G/T	0.118	0.176	0.003	0.63 (0.45-0.87)

SNP = single nucleotide polymorphism; MAF = minor allele frequency; CI = confidence interval
 For the analysis displayed in this table one sided P-values < 0.0083 were considered to be significant

Table 4. *Complement factor H* haplotypes in chronic central serous chorioretinopathy.

SNP							HF Subgroup 1 (n=197)	HF Controls (n=881)	Unadjusted P-value	Odds ratio (95% CI)
rs3753394	rs800292	rs1061170	rs2284664	rs1329428	rs1065489					
H1	C	G	C	C	C	G	0.291	0.328	0.164	0.83 (0.59-1.17)
H2	C	A	T	T	T	G	0.258	0.208	0.072	1.33 (0.93-1.90)
H3	T	G	T	C	C	T	0.090	0.157	0.010	0.54 (0.32-0.91)
H4	C	G	T	C	T	G	0.125	0.132	0.480	0.96 (0.60-1.52)
H5	T	G	T	C	T	G	0.102	0.076	0.150	1.37 (0.81-2.32)

SNP = single nucleotide polymorphism; HF = haplotype frequency; CI = confidence interval
 For the analysis displayed in this table one sided P-values < 0.01 were considered to be significant

Table 5. Comparison of allele frequencies among the subgroups.

SNP	Location	MAF Subgroup 1 (n=197)	MAF ubgroup 2 (n=52)	MAF Subgroup 3 (n=43)	MAF controls (n=1311/881)	MAF AMD (n=1147)	P-value Subgroup 1 vs Subgroup 2	P-value Subgroup 1 vs Subgroup 3
rs10490924 (A69S)	ARMS2 exon 1	0.17	0.26	0.31	0.24	0.41	0.033	0.002
rs800292 (I62V)	CFH exon 2	0.31	0.26	0.15	0.24	0.18	0.337	0.002
rs1329428	CFH intron 15	0.53	0.41	0.40	0.43	N/A	0.047	0.032
rs1065489 (D936E)	CFH Exon 18	0.12	0.16	0.12	0.18	N/A	0.246	1

SNP = single nucleotide polymorphism; MAF = minor allele frequency; AMD = age-related macular degeneration
For the analysis displayed in this table two sided P-values < 0.0125 were considered to be significant

Discussion

Both risk-conferring and protective associations of polymorphisms in the *ARMS2* and *CFH* genes with chronic CSC were identified in this study. Moreover, by introducing a subclassification of chronic CSC our data demonstrate clear differences as well as a certain degree of phenotypic and genetic overlap between chronic CSC and AMD.

Chronic CSC is a heterogeneous disease that sometimes shows a clinical overlap with other macular diseases such as polypoidal choroidal vasculopathy and AMD. With detailed phenotyping based on SD-OCT, FA and ICG angiography, we defined three clinically distinctive subgroups, including typical chronic CSC (subgroup 1), slightly atypical chronic CSC (subgroup 2), and a third more atypical phenotypic subgroup of chronic CSC patients that had evidence of an overlap with other macular diseases (subgroup 3).

Out of an analysis of 19 SNPs at known AMD loci,²⁰⁻²² one SNP in *ARMS2* remained significant after correction for multiple testing, and three SNPs at other AMD loci (*CFH*, *TNFRSF10A*, *ADAMTS9*) showed a trend towards association with typical chronic CSC (subgroup 1). The association of these SNPs with chronic CSC was not exactly in concordance with the strength of the association previously reported in AMD.²⁰ Indeed, the effect sizes for *ARMS2* (rs10490924) and *CFH* (rs1061170 Y402H) are larger in AMD (ORs = 2.76 and 2.25, respectively),^{20, 24} while an inverse and weaker effect was observed in chronic CSC (ORs = 0.64 and 0.83, respectively). A protective effect was observed for *TNFRSF10A* (rs13278062) in chronic CSC (OR = 0.73), while an opposite and weaker effect was previously detected in AMD (OR = 1.15).²⁰ *ADAMTS9* (rs6795735) conferred increased risk for both diseases, but with a less strong effect in AMD (OR = 1.10) compared to chronic CSC (OR = 1.37).²⁰ For some of these associations the effect was mainly carried by the males (Supplementary Table 2). However, since chronic CSC is predominantly found in males, the low number of female patients present in our cohort made the interpretation of sex-specific associations unreliable. Genotyping of more female chronic CSC patients can shed light on the occurrence of a gender-specific effect, and on potential differences in disease etiology.

It is well known that AMD is a multifactorial disease, in which a number of subcellular systems and pathways are involved such as the complement system, angiogenesis, lipid metabolism and the extracellular matrix.²⁰ Our current findings suggest a partial pathophysiologic overlap of chronic CSC with AMD, that could be connected with one or more of these associated pathways

In both AMD and chronic CSC the reported association with *ARMS2* (rs10490924) has the strongest effect compared to other disease-associated SNPs (OR = 2.76 for AMD and OR = 0.64 for chronic CSC).²⁰ Interestingly, the association of *ARMS2* (rs10490924) with chronic

CSC is protective, whereas the previously reported association with AMD is risk-conferring.^{20, 25} The potential protective effect of *ARMS2* (rs10490924) in chronic CSC was not reported before. However, an association of *ARMS2* (rs10490924) with a lower incidence of serous retinal detachments has been reported in polypoidal choroidal vasculopathy, a disease that shows clinical overlap with chronic CSC.²⁶ Intriguingly, a history of CSC is more prevalent in patients with polypoidal choroidal vasculopathy and choroidal hyperpermeability,²⁷ and CSC in combination with a type 1 neovascularization or polypoidal choroidal vasculopathy has also been described.^{28, 29} The protective effect of *ARMS2* (rs10490924) in both conditions may suggest a functional involvement of *ARMS2* at the level of the RPE and/or choroid. Although the exact role of the *ARMS2* protein product is unknown, a recent study demonstrated that *ARMS2* interacts with components of the extracellular matrix.³⁰ Disturbances in the extracellular matrix at the level of the RPE and/or choroid could result in an increased susceptibility for cellular detachments, which may indicate a possible link between the supposed molecular function of *ARMS2* and the clinical phenotype of chronic CSC.

Our data also suggest involvement of other extracellular matrix molecules. Although these results did not remain significant after correction for multiple testing, and would require replication in other cohorts for confirmation, it is worthwhile to consider their association. *ADAMTS9* (rs6795735, $P = 0.045$) encodes a metalloproteinase that cleaves large aggregated proteoglycans, has thrombospondin domains, and is an inhibitor of angiogenesis.³¹ *COL8A1* (rs13081855, $P = 0.074$) encodes a collagen type VIII which is expressed in the endothelium of blood vessels and is involved in endothelial cell and vascular smooth muscle proliferation and migration.^{32, 33} *TNFRSF10A* (rs13278062, $P = 0.004$) is part of the tumor necrosis factor alpha receptor superfamily and acts as a death receptor after binding its cytokine ligand TNFSF10/TRAIL, known to play an important role in the induction of apoptosis,³⁴ vascular smooth muscle proliferation, and regulation of angiogenic responses in the brain after stroke.^{35, 36} These potential associations suggest that the extracellular environment as well as angiogenic processes may be involved in chronic CSC.

We also found a significant association with several SNPs in the *CFH* gene (rs800292, rs1329428, and rs1065489) but the effect sizes were slightly smaller than those recently reported in a Japanese CSC cohort (e.g OR = 1.47 for rs1329428 reported in the current cohort versus 1.79 reported by Miki et al).¹⁷ This may partially be explained by genetic differences in the frequency of the minor alleles for the tested SNPs at the *CFH* locus that exist between the Japanese and Western European populations (hapmap.org) (Supplementary Table 1), as well as differences in phenotyping. Similar to our observation for *ARMS2*, *CFH* SNPs that confer risk for chronic CSC were previously found to be protective for AMD, whereas SNPs that were found to be protective for chronic CSC were previously found to increase risk for AMD.²⁴ The H2 haplotype, previously found to be protective for AMD (OR = 0.54),²⁴ was found to increase risk for chronic CSC (OR = 1.33). Conversely, the H3 haplotype that was

previously not found to be significantly associated with AMD was found to be protective for chronic CSC (OR = 0.54).²⁴ The observation that *CFH* SNPs have opposite effects in CSC versus AMD was also recently reported by Miki et al,¹⁷ but the underlying mechanisms that could explain these observations are unclear.

The functional implications of the associated *CFH* SNPs in the present chronic CSC cohort and their possible significance for the pathogenesis of chronic CSC are unknown, but there appears to be an important role for the CFH protein in the RPE and choroid. CFH is an inhibitor of the alternative complement pathway (AP), and choroidal cells play a central role in complement AP activity in the eye. C3, an acute phase protein and the central player in complement activation, is most highly expressed in the choroid.^{37, 38} The CFH protein is the predominant cell surface-associated complement inhibitor in the RPE-choroid complex, where it down-regulates the complement AP activation via inhibition of C3 activity.³⁹

The choroid seems to play a pivotal role in the pathogenesis of CSC, as choroidal thickening, congestion, and hyperpermeability seem to be the most pronounced and extensive abnormalities in chronic CSC patients.⁴⁰ Additionally, patients with CSC show an increased choroidal blood flow compared to controls during exercise.⁴¹ Homozygosity for the *CFH* rs1061170 (Y402H) risk allele was shown to be associated with an increased choroidal blood flow and ocular perfusion pressure during exercise using Doppler flowmetry,⁴² a process that may be linked to the CFH-binding partner adrenomedullin via (steroid-)hormone-dependent nitric oxide bioactivity in vascular endothelial cells.^{39, 43, 44} Altered complement AP activity, extravasation of complement-related proteins, and deposition of terminal complement membrane attack complexes may lead to RPE damage and dysfunction. Damage to the RPE cell layer, further destabilized by changes in the extracellular matrix and under stress from increasing pressure from the thickened choroid, could eventually result in subretinal fluid leakage.^{43, 44}

Three distinct phenotypic subgroups within our analyzed chronic CSC patient population were identified based on multimodal imaging, ranging from typical to less typical phenotypes. The minor allele frequencies of the SNPs (rs10490924, rs800292, rs1329428, and rs1065489) that were significantly associated with typical chronic CSC (subgroup 1), differed from the minor allele frequencies observed in the other subgroups. Subgroup 2 differs only slightly from the most typical subgroup (subgroup 1), suggesting that considerable genetic overlap exists. In fact, the major distinction in the reported phenotypic criteria are bilateral versus unilateral occurrence. The atypical subgroup (subgroup 3) differs significantly from subgroup 1 for *ARMS2* (rs10490924, P = 0.002) and *CFH* (rs800292, P = 0.002) minor allele frequencies, which suggests that subgroup 3 is genetically different from the typical chronic CSC group. Based on the phenotypic criteria, subgroup 3 shows overlap with other maculopathies such as AMD, highly myopic macular changes and polypoidal choroidal vasculopathy. The minor

allele frequencies of these two SNPs in subgroup 3 were even similar to those normally observed in AMD, with the same direction of effect seen in AMD opposed to typical chronic CSC. Our results demonstrate that detailed phenotyping in chronic CSC patients is important to obtain reliable genetic results.

In conclusion, we show that genetic variants in *ARMS2* and *CFH* are associated with chronic CSC. Detailed phenotyping and classification of chronic CSC is important to establish such genetic associations. Our findings indicate that complement dysregulation in the RPE/choroid, and potentially dysregulation of genes involved in extracellular matrix and angiogenesis factors, are involved in the pathogenesis of chronic CSC. Further genetic and phenotypic analysis of chronic CSC, as well as genotype-phenotype correlation analyses, can provide important clues on the genetic background and pathogenesis of chronic CSC, and may lead to the identification of possible new preventive and therapeutic targets.

References

1. Liew G, Quin G, Gillies M, Fraser-Bell S. Central serous chorioretinopathy: a review of epidemiology and pathophysiology. *Clin Experiment Ophthalmol* 2013;41:201-14.
2. Wang M, Munch IC, Hasler PW, et al. Central serous chorioretinopathy. *Acta Ophthalmol* 2008;86:126-45.
3. Gemenetzi M, De Salvo G, Lotery AJ. Central serous chorioretinopathy: an update on pathogenesis and treatment. *Eye (Lond)* 2010;24:1743-56.
4. Eandi CM, Ober M, Iranmanesh R, et al. Acute central serous chorioretinopathy and fundus autofluorescence. *Retina* 2005;25:989-93.
5. Quin G, Liew G, Ho IV, et al. Diagnosis and interventions for central serous chorioretinopathy: review and update. *Clin Experiment Ophthalmol* 2013;41:187-200.
6. Nicholson B, Noble J, Forooghian F, Meyerle C. Central serous chorioretinopathy: update on pathophysiology and treatment. *Surv Ophthalmol* 2013;58:103-26.
7. Spaide RF, Campeas L, Haas A, et al. Central serous chorioretinopathy in younger and older adults. *Ophthalmology* 1996;103:2070-9; discussion 2079-80.
8. von Winning CH, Oosterhuis JA, Renger-van Dijk AH, et al. Diffuse retinal pigment epitheliopathy. *Ophthalmologica* 1982;185:7-14.
9. Polak BC, Baarsma GS, Snyers B. Diffuse retinal pigment epitheliopathy complicating systemic corticosteroid treatment. *Br J Ophthalmol* 1995;79:922-5.
10. Yannuzzi LA. Central serous chorioretinopathy: a personal perspective. *Am J Ophthalmol* 2010;149:361-3.
11. Loo RH, Scott IU, Flynn HW Jr, et al. Factors associated with reduced visual acuity during long-term follow-up of patients with idiopathic central serous chorioretinopathy. *Retina* 2002;22:19-24.
12. Wang MS, Sander B, Larsen M. Retinal atrophy in idiopathic central serous chorioretinopathy. *Am J Ophthalmol* 2002;133:787-93.
13. Bouzas EA, Karadimas P, Pournaras CJ. Central serous chorioretinopathy and glucocorticoids. *Surv Ophthalmol* 2002;47:431-48.
14. Oosterhuis JA. Familial central serous retinopathy. *Graefes Arch Clin Exp Ophthalmol* 1996;234:337-41.
15. Weenink AC, Borsje RA, Oosterhuis JA. Familial chronic central serous chorioretinopathy. *Ophthalmologica* 2001;215:183-7.
16. Park DW, Schatz H, Gaffney MM, et al. Central serous chorioretinopathy in two families. *Eur J Ophthalmol* 1998;8:42-7.
17. Miki A, Kondo N, Yanagisawa S, et al. Common variants in the complement factor H gene confer genetic susceptibility to central serous chorioretinopathy. *Ophthalmology* 2014;121:1067-72.
18. Schubert C, Pryds A, Zeng S, et al. Cadherin 5 is regulated by corticosteroids and associated with central serous chorioretinopathy. *Hum Mutat* 2014;35:859-67.
19. Yannuzzi LA, Freund KB, Goldbaum M, et al. Polypoidal choroidal vasculopathy masquerading as central serous chorioretinopathy. *Ophthalmology* 2000;107:767-77.

20. AMD Gene Consortium. Seven new loci associated with age-related macular degeneration. *Nat Genet* 2013;45:433-9.
21. Chen W, Stambolian D, Edwards AO, et al, Complications of Age-Related Macular Degeneration Prevention Trial (CAPT) Research Group. Genetic variants near TIMP3 and high-density lipoprotein-associated loci influence susceptibility to age-related macular degeneration. *Proc Natl Acad Sci U S A* 2010;107:7401-6.
22. Klein RJ, Zeiss C, Chew EY, et al. Complement factor H polymorphism in age-related macular degeneration. *Science* 2005;308:385-9.
23. Ristau T, Ersoy L, Lechanteur Y, et al. Allergy is a protective factor against age-related macular degeneration. *Invest Ophthalmol Vis Sci* 2014;55:210-4.
24. Hageman GS, Anderson DH, Johnson LV, et al. A common haplotype in the complement regulatory gene factor H (HF1/CFH) predisposes individuals to age-related macular degeneration. *Proc Natl Acad Sci U S A* 2005;102:7227-32.
25. Rivera A, Fisher SA, Fritsche LG, et al. Hypothetical LOC387715 is a second major susceptibility gene for age-related macular degeneration, contributing independently of complement factor H to disease risk. *Hum Mol Genet* 2005;14:3227-36.
26. Sakurada Y, Kubota T, Imasawa M, et al. Role of complement factor H I62V and age-related maculopathy susceptibility 2 A69S variants in the clinical expression of polypoidal choroidal vasculopathy. *Ophthalmology* 2011;118:1402-7.
27. Koizumi H, Yamagishi T, Yamazaki T, Kinoshita S. Relationship between clinical characteristics of polypoidal choroidal vasculopathy and choroidal vascular hyperpermeability. *Am J Ophthalmol* 2013;155:305-13.
28. Fung AT, Yannuzzi LA, Freund KB. Type 1 (sub-retinal pigment epithelial) neovascularization in central serous chorioretinopathy masquerading as neovascular age-related macular degeneration. *Retina* 2012;32:1829-37.
29. Park HS, Kim IT. Clinical characteristics of polypoidal choroidal vasculopathy associated with chronic central serous chorioretinopathy. *Korean J Ophthalmol* 2012;26:15-20.
30. Kortvely E, Hauck SM, Duetsch G, et al. ARMS2 is a constituent of the extracellular matrix providing a link between familial and sporadic age-related macular degenerations. *Invest Ophthalmol Vis Sci* 2010;51:79-88.
31. Koo BH, Coe DM, Dixon LJ, et al. ADAMTS9 is a cell-autonomously acting, anti-angiogenic metalloprotease expressed by microvascular endothelial cells. *Am J Pathol* 2010;176:1494-504.
32. Plenz GA, Deng MC, Robenek H, Volker W. Vascular collagens: spotlight on the role of type VIII collagen in atherogenesis. *Atherosclerosis* 2003;166:1-11.
33. MacBeath JR, Kielty CM, Shuttleworth CA. Type VIII collagen is a product of vascular smooth-muscle cells in development and disease. *Biochem J* 1996;319:993-8.
34. Crowder RN, El-Deiry WS. Caspase-8 regulation of TRAIL-mediated cell death. *Exp Oncol* 2012;34:160-4.

35. Kavurma MM, Schoppet M, Bobryshev YV, et al. TRAIL stimulates proliferation of vascular smooth muscle cells via activation of NF-kappaB and induction of insulin-like growth factor-1 receptor. *J Biol Chem* 2008;283:7754-62.
36. Buga AM, Margaritescu C, Scholz CJ, et al. Transcriptomics of post-stroke angiogenesis in the aged brain. *Front Aging Neurosci* [serial online] 2014;6:44.
37. Anderson DH, Radeke MJ, Gallo NB, et al. The pivotal role of the complement system in aging and age-related macular degeneration: hypothesis re-visited. *Prog Retin Eye Res* 2010;29:95-112.
38. Loyet KM, Deforge LE, Katschke KJ Jr, et al. Activation of the alternative complement pathway in vitreous is controlled by genetics in age-related macular degeneration. *Invest Ophthalmol Vis Sci* 2012;53:6628-37.
39. Boon CJ, van de Kar NC, Klevering BJ, et al. The spectrum of phenotypes caused by variants in the CFH gene. *Mol Immunol* 2009;46:1573-94.
40. Imamura Y, Fujiwara T, Margolis R, Spaide RF. Enhanced depth imaging optical coherence tomography of the choroid in central serous chorioretinopathy. *Retina* 2009;29:1469-73.
41. Tittl M, Maar N, Polska E, et al. Choroidal hemodynamic changes during isometric exercise in patients with inactive central serous chorioretinopathy. *Invest Ophthalmol Vis Sci* 2005;46:4717-21.
42. Told R, Palkovits S, Haslacher H, et al. Alterations of choroidal blood flow regulation in young healthy subjects with complement factor H polymorphism. *PLoS One* 2013;8:e60424.
43. Udono-Fujimori R, Udono T, Totsune K, et al. Adrenomedullin in the eye. *Regul Pept* 2003;112:95-101.
44. Dorner GT, Garhofer G, Huemer KH, et al. Effects of adrenomedullin on ocular hemodynamic parameters in the choroid and the ophthalmic artery. *Invest Ophthalmol Vis Sci* 2003;44:3947-51.

Supplementary tables

Supplementary Table 1.

Minor allele frequencies of *CFH* SNPs in European (CEU) and Japanese (JPT) population.

SNP	MA (HapMap-CEU)	MA frequency HapMap-CEU	MA frequency HapMap-JPT
<i>CFH</i> rs3753394	T	0.279	0.509
<i>CFH</i> rs800292	A	0.217	0.416
<i>CFH</i> rs2284664	T	0.195	0.406
<i>CFH</i> rs1329428	T	0.424	0.473
<i>CFH</i> rs1065489	T	0.161	0.469

CFH = complement factor H; SNP = single nucleotide polymorphism; MA = minor allele

Supplementary Table 2.


Analysis of 19 age-related macular degeneration loci in chronic central serous chorioretinopathy split based on gender


SNP (locus)	Alleles (Major/Minor)	Gender	MAF subgroup 1 (M=154/F=43)	MAF controls (M=629/F=682)	Unadjusted Allelic P- value	Allelic Odds Ratio (95% CI)
rs10490924 (<i>ARMS2</i>)	G/T	M	0.15	0.22	0.006	0.63 (0.45-0.88)
		F	0.21	0.25	0.601	0.83 (0.49-1.42)
rs12144939 (<i>CFH</i>)	G/T	M	0.27	0.20	0.006	1.51 (1.13-2.01)
		F	0.18	0.21	0.675	0.86 (0.49-1.54)
rs429608 (<i>C2-CFB</i>)	G/A	M	0.17	0.14	0.277	1.22 (0.87-1.71)
		F	0.14	0.13	0.615	1.15 (0.61-2.17)
rs2230199 (<i>C3</i>)	G/C	M	0.18	0.16	0.355	1.21 (0.81-1.82)
		F	0.21	0.19	0.630	1.16 (0.63-2.17)
rs9621532 (<i>TIMP3</i>)	A/C	M	0.05	0.05	0.883	0.93 (0.51-1.69)
		F	0.08	0.05	0.224	1.60 (0.71-3.60)
rs4420638 (<i>APOE</i>)	A/G	M	0.15	0.19	0.181	0.78 (0.55-1.10)
		F	0.18	0.16	0.649	1.13 (0.63-2.01)
rs3764261 (<i>CETP</i>)	G/T	M	0.31	0.32	0.681	0.94 (0.72-1.23)
		F	0.27	0.32	0.468	0.81 (0.50-1.33)
rs943080 (<i>VEGFA</i>)	T/C	M	0.44	0.48	0.337	0.88 (0.68-1.13)
		F	0.44	0.48	0.501	0.85 (0.55-1.33)
rs13278062 (<i>TNFRSF10A</i>)	T/G	M	0.41	0.50	0.005	0.69 (0.54-0.89)
		F	0.38	0.46	0.139	0.71 (0.45-1.12)
rs493258 (<i>LIPC</i>)	C/T	M	0.49	0.45	0.140	1.22 (0.95-1.56)
		F	0.48	0.47	1.000	1.02 (0.65-1.58)
rs10033900 (<i>CFI</i>)	C/T	M	0.50	0.48	0.443	1.11 (0.86-1.42)
		F	0.49	0.48	0.911	1.03 (0.66-1.60)
rs3812111 (<i>COL10A1</i>)	A/T	M	0.35	0.35	1.000	1.00 (0.77-1.30)
		F	0.31	0.37	0.295	0.76 (0.48-1.23)
rs13081855 (<i>COL8A1-FILIP1L</i>)	G/T	M	0.12	0.09	0.049	1.49 (1.01-2.21)
		F	0.10	0.09	0.844	1.07 (0.50-2.26)
rs3130783 (<i>IER3-DDR1</i>)	A/G	M	0.22	0.20	0.579	1.10 (0.81-1.49)
		F	0.12	0.18	0.184	0.62 (0.31-1.21)

rs8135665 (<i>SLC16A8</i>)	C/T	M	0.21	0.24	0.408	0.84 (0.65-1.18)
		F	0.18	0.20	0.675	0.85 (0.48-1.51)
rs334353 (<i>TGFBR1</i>)	T/G	M	0.27	0.25	0.513	1.10 (0.83-1.46)
		F	0.21	0.25	0.601	0.84 (0.49-1.43)
rs8017304 (<i>RAD51B</i>)	A/G	M	0.36	0.37	0.742	0.95 (0.73-1.23)
		F	0.35	0.38	0.563	0.85 (0.54-1.35)
rs6795735 (<i>ADAMTS9</i>)	C/T	M	0.47	0.41	0.052	1.29 (1.00-1.66)
		F	0.44	0.41	0.570	1.14 (0.73-1.77)
rs9542236 (<i>B3GALTL</i>)	T/C	M	0.43	0.44	0.748	0.96 (0.74-1.23)
		F	0.48	0.44	0.498	1.18 (0.76-1.83)

SNP = single nucleotide polymorphism; M = male; F= female; MAF = minor allele frequency; CI = confidence interval

For the analysis displayed in this table two sided P-values < 0.0026 were considered to be significant





CHAPTER 2.2

Genomic copy number variations of the complement component *C4B* Gene are associated with chronic central serous chorioretinopathy

Myrte B. Breukink^{*}, Rosa L. Schellevis^{*}, Camiel J.F. Boon, Sascha Fauser, Carel B. Hoyng, Anneke I. den Hollander & Eiko K. de Jong

Published in: *Investigative Ophthalmology and Visual Science*. 2015;56(9):5608-13
(*joint first author)

Purpose:

Chronic central serous chorioretinopathy (CSC) has recently been associated to variants in the *complement factor H* gene. To further investigate the role of the complement system in chronic CSC, the genomic copy number variations in the *complement component 4 (C4)* gene were studied.

Methods:

C4A and *C4B* copy numbers were analyzed in 197 chronic CSC patients and 303 healthy controls using a Taqman® copy number determination assay. Copy numbers of *C4A*, *C4B* and the total *C4* load were compared between cases and controls, using a Fisher Exact test. For this analysis Bonferroni correction was performed for three tests, and p-values <0.017 were considered to be significant. A logistic regression model was constructed to calculate the odds ratios (OR) of each of the *C4B* copy numbers, using two copies as a reference. For this model p-values <0.05 were considered to be significant.

Results:

C4B genomic copy numbers differed significantly between chronic CSC patients and healthy controls (p=0.0018). Absence of *C4B* significantly conferred risk of chronic CSC (p=0.039, OR=2.61 [95% confidence interval (CI)=1.05–6.52]), whereas three copies of *C4B* significantly decreased the risk of chronic CSC (p=0.014, OR=0.45 [95%CI=0.23–0.85]). The *C4A* genomic copy numbers and total *C4* load did not significantly differ between cases and controls.

Conclusions:

This study shows that copy numbers of *C4B* are significantly associated with chronic CSC. Carrying no copies of *C4B* significantly increases the risk of chronic CSC, whereas carrying three *C4B* copies is protective. These findings reinforce the hypothesis of a possible involvement of the complement system in the pathogenesis of chronic CSC.

Introduction

Chronic central serous chorioretinopathy (CSC) is characterized by fluid accumulation under the neuroretina. It has been postulated that this serous fluid derives from the choroid, and that it leaks through a dysfunctional retinal pigment epithelium (RPE) causing a detachment of the neuroretina.¹⁻⁴ Classically, chronic CSC patients are relatively young (middle-aged) men who are still professionally active.⁵ Besides male gender, also the use of corticosteroids, type A personality and stress have been associated with chronic CSC.⁴⁻⁶ Although the exact pathophysiological mechanism of the disease remains unknown, we and others have previously suggested involvement of the complement system, and in particular the *complement factor H (CFH)* gene in chronic CSC.^{7,8} Interestingly, *CFH* variants that confer increased risk in chronic CSC have previously been described to be protective in age-related macular degeneration (AMD), and vice versa.⁸⁻¹⁰

The complement system consists of three major pathways; the classical, the lectin, and the alternative pathway.¹¹ *CFH* is involved in the alternative pathway and can influence C3b production by blocking one of the two C3-convertases (C3bBb). The classical and lectin pathways also play an important role in C3b production mediated by the other C3-convertase (C4b2a), of which the complement component 4 (C4) protein is a key factor.¹²

Copy number variations of the *C4* gene have been associated with several eye diseases and autoimmune disorders (e.g. Vogt- Koyanagi-Harada and Beçhet's disease).¹³⁻¹⁵ In addition, Banlaki et al. found that the genomic copy number of *C4B* is associated with cortisol release after adrenocorticotrophic hormone (ACTH) stimulation.¹⁶ This is of particular interest considering that stress, which appears to be associated with chronic CSC,⁴ has a strong influence on the hypothalamic-pituitary-adrenal (HPA)-axis and increases ACTH release.¹⁷

Because of its role in the complement system, and its association with the HPA-axis, we hypothesized that copy number variation in the *C4* gene may be associated with chronic CSC. In this study we assessed the copy number variations of the *C4* gene in a chronic CSC cohort.

Materials and Methods

Subjects

In this study, 197 patients diagnosed with chronic CSC who visited the outpatient clinic of the department of Ophthalmology at the Radboud University Medical Center, Nijmegen, the Netherlands were included (**Table 1**). The diagnosis chronic CSC was based on an extensive ophthalmological examination including fundoscopy, spectral-domain optical coherence tomography, fluorescein angiography and indocyanine green angiography. The definition of typical chronic CSC used in this study was based on the previously published subgroups by de Jong et al.,⁸ and patients in this study were phenotypes by an experienced retina specialist (CJFB) (**Figure 1**). Additionally, a total of 303 control subjects were recruited from the blood bank of the Radboud University Medical Center, Nijmegen, the Netherlands (n = 154), and the European Genetic Database (EUGENDA, www.eugenda.org) (n = 149) (**Table 1**). For this last group fundus photographs were graded to rule out any ophthalmological abnormalities at the moment of inclusion. Informed consent for the use of DNA for genetic studies was obtained from all subjects. This study followed the guidelines of the Declaration of Helsinki and was approved by the local ethics committee.

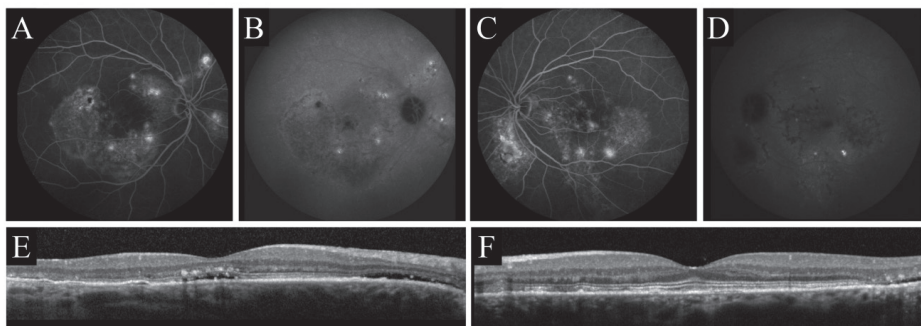


Figure 1.

Example of fluorescein angiography (FA) of a right eye (RE): **A**, and a left eye (LE): **C**, indocyanine green (ICG) angiography of a RE: **B**, and a LE: **D** and spectral-domain optical coherence tomography (SD-OCT) of a RE: **E**, and a LE: **F** imaging of the phenotypic characteristics of the chronic central serous chorioretinopathy (CSC) cohort used for this study. (**A-F**) The RE and LE of a patient demonstrate diffuse hyperfluorescent areas of leakage on FA and ICG angiography (**A-D**) and subretinal fluid beneath the fovea (**E**), illustrative for typical chronic CSC.

Table 1. Demographics of the study population

	cCSC patients	Controls	p-value
No. of subjects	197	303	NA
Sex (male/female)	154/43	226/77	0.392
Mean age \pmSD (years)	53 (\pm 10)	53 (\pm 11)	0.755
Age range (years)	29-74	29-77	NA

cCSC; chronic central serous chorioretinopathy, SD; standard deviation

Copy number determination

DNA was isolated from peripheral blood using standard procedures. *C4A* and *C4B* copy numbers were determined by real-time PCR using Taqman[®] genotyping assays (Applied Biosystems, Thermo Fisher Scientific, Waltham, USA). The FAM-labeled *C4A* (Hs07226349_cn) or *C4B* (Hs07226350_cn) Taqman[®] copy number assay was combined together with the VIC-labeled Ribonuclease P (*RNaseP*) reference assay (Catalog nr. 4403326), and Taqman genotyping mastermix (Catalog nr. 4381656). All samples were tested in duplicate for *C4A* and *C4B* on 384-wells plates using 10 ng of DNA in a total reaction volume of 10 μ l.

Samples with known copy numbers for either *C4A* (0-4) or *C4B* (0-3) were kindly provided by Dr. C. Yung Yu.¹⁸ These samples were included as a reference on each plate to facilitate accurate copy number determination, using the method described previously.¹⁸ In each run the amplification efficiencies of the *C4A/C4B* and *RNaseP* probes were calculated using a serial dilution (50 ng-1.56 ng) of a sample with two *C4A* and *C4B* copies. The primer efficiencies of the probes were compared, and deemed similar if they differed <2%, this was the case in all runs. Therefore, the efficiencies were not incorporated into the calculations of the copy numbers. PCR was performed with a 7900HT thermocycler (Applied Biosystems, Thermo Fisher Scientific, Waltham, USA) using the following program: 2 min at 50°C, 10 min at 95°C, and 40 cycles of 15 sec at 95°C and 60 sec at 60°C. Data was analyzed with the Copycaller software (V2.0) (Applied Biosystems, Thermo Fisher Scientific, Waltham, USA). Copy numbers determined by the Copycaller software were corrected using the trend line based on the reference samples, as described before.¹⁸ If the results were inconsistent between the Copycaller output and the values corrected with the trend line, samples were retested on a new plate in triplicate.

Statistics

The comparison of *C4A*, *C4B* and total *C4* copy number distribution between chronic CSC patients and controls was performed by means of a Fisher Exact test using SPSS Statistics (V20)(IBM Corp., Armonk, USA). Bonferroni correction for multiple testing was performed for three tests and p-values < 0.017 were considered to be statistically significant. A logistic regression model was constructed to determine the odds ratios for the various copy numbers of *C4B*. According to previously published studies, two genomic copy numbers of *C4B* are considered to be most common in the healthy population.^{15, 19} We were able to confirm this in our cohort, and therefore this copy number was set as reference. In this model, p-values <0.05 were considered to be significant. Graphs were generated using Graphpad Prism (V5) (Graphpad Software, San Diego, USA).

Results

The copy numbers of *C4A* and *C4B* were successfully determined in 197 chronic CSC cases and 303 controls. No significant difference was observed between cases and controls for the *C4A* genomic copy number (range: 0-6, $p=0.649$, **Figure 2A**). The *C4B* distribution was significantly different between chronic CSC patients and controls (range: 0-4, $p=0.0018$, **Figure 2B**). Overall, cases carried lower copy numbers of *C4B* than the control population. The total *C4* genomic copy number was not different in cases compared to controls ($p=0.148$, **Figure 2C**). Age and gender were not associated with either *C4A*, *C4B*, or total *C4* genomic copy number (**Table 2**, data for *C4A* and total *C4* not shown).

To assess the effect size of the different copy numbers of *C4B* on development of chronic CSC, a logistic regression was performed (**Table 2**). The logistic regression model based on the distribution of *C4B* between cases and controls was significant ($p=0.0035$, **Table 2**). Carrying no copies of *C4B* conferred increased risk of chronic CSC ($p=0.039$, odds ratio (OR)=2.61, 95% CI [1.05-6.52]). A similar trend was observed for carriers of one copy of *C4B*, but the results were not significant ($p=0.080$, OR=1.47, 95% CI [0.96-2.26]). Carrying three *C4B* copies was associated with a significantly decreased risk of chronic CSC ($p=0.014$, OR=0.45, 95% CI [0.24-0.85]), whereas no significant association with chronic CSC was observed in individuals carrying four copies of *C4B* ($p=0.81$).

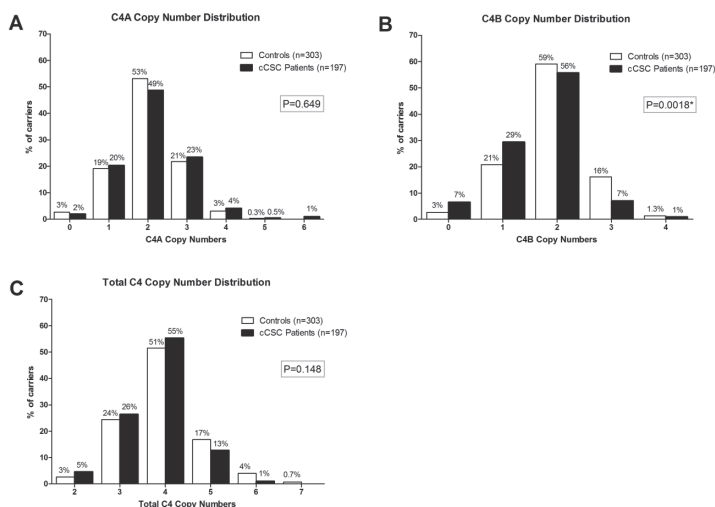


Figure 2.

Distribution of the genomic copy numbers of *C4A* (A), *C4B* (B), and total *C4* (C) in patients with chronic central serous chorioretinopathy (cCSC) and controls. Displayed p-values were generated with a Fisher Exact test. To correct for multiple testing, p-values <0.017 were considered to be significant.

Table 2. Logistic regression model for *C4B* loadOverall significance model **P=0.0035**

<i>C4B</i> copy nr.	cCSC patients (n)	Controls (n)	p-value	OR	95% CI
Age	197	303	0.605	NA	NA
Gender	197	303	0.346	NA	NA
0	13	8	0.039	2.613	1.048-6.518
1	58	63	0.080	1.469	0.956-2.259
2	110	179	Ref.	1	NA
3	14	49	0.014	0.445	0.234-0.849
4	2	4	0.808	0.809	0.145-4.503

cCSC; chronic central serous chorioretinopathy

OR; Odds Ratio

CI; Confidence Interval

Discussion

Our study results demonstrate that chronic CSC patients have a significantly different *C4B* load as compared to healthy controls ($p=0.0018$). Carrying no copies of *C4B* was associated with an increased risk of chronic CSC (OR=2.61, 95% CI [1.05-6.52]), whereas carrying three *C4B* copies was associated with a decreased risk of chronic CSC (OR=0.45, 95% CI [0.23-0.85]). No association with chronic CSC was observed in individuals carrying four *C4B* copies, which is likely due to the limited sample size of this group (cases, $n=4$, controls, $n=2$). No significant differences were observed between cases and controls for *C4A* and total *C4* load.

The *C4* gene lies within the *RP-C4-CYP21-TNX* (RCCX) locus located in the major histocompatibility complex (MHC) region III on chromosome 6 of the human genome.¹⁹ The MHC region contains an elevated level of genomic copy number variations that are presumably present to increase immunological diversity.²⁰ Duplications and deletions in the region have led to the formation of haplotypes containing variable copies of the RCCX locus in the human population (**Figure 3B**).²⁰⁻²² Haplotypes containing two or more duplications of the RCCX locus show extensive variability in their gene content, generally with complete duplications of the *C4* gene (**Figure 3B**).^{21, 23} The *C4* gene encodes for the C4 protein, of which two variants have been described (*C4A/C4B*), differing in only four amino acids encoded by exon 26 (**Figure 3A**).²⁴

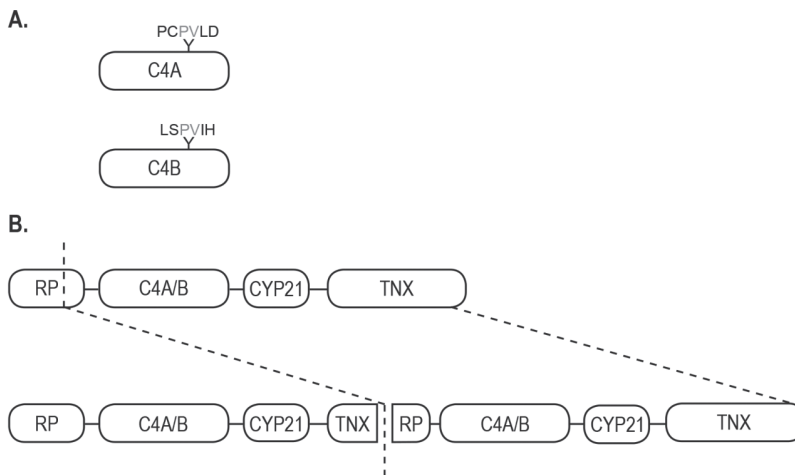


Figure 3.

A schematic illustration of the RCCX-locus. **A**, a display of the two variants of the *C4* gene, differing in 4 amino acids in exon 26. **B**, an example of the structure of the RCCX-locus with a single copy (upper panel) and two copies (lower panel) of the *C4* gene. In case of duplication, a complete *C4A* or *C4B* gene and the *CYP21* gene are duplicated while the *RP* and *TNX* genes are only partially duplicated. The dotted lines indicate the approximate site where during recombination the duplication has occurred in the past. (Figure based on Banlaki et al. 2013)²²

Copy number variations of either *C4A* or *C4B*, have been associated with several systemic diseases with ocular involvement, such as Vogt-Koyanagi-Harada disease, Behçet's disease, and systemic lupus erythematosus (SLE).¹³⁻¹⁵ Hou et al. showed that a lower copy number of *C4A* and *C4B* increased the risk of Vogt-Koyanagi-Harada, an autoimmune disorder characterized by bilateral granulomatous panuveitis.¹³ The same group also demonstrated that higher copy numbers of *C4A* conferred risk of Behçet's disease, an auto-inflammatory disease, which presents with acute anterior uveitis.¹⁴ Several studies have shown an association between low copy numbers of *C4* and an increased risk for SLE, an auto-immune disease that is typically mediated by immune complexes.^{15, 25, 26} In the past, CSC has been described in SLE patients,^{27, 28} but it remains unclear whether this is a primary manifestation of SLE, or whether it is a consequence of corticosteroid treatment for SLE.^{29, 30} Several studies have reported a positive linear correlation between serum C4 and *C4* genomic copy number,³¹⁻³³ suggesting that the lower number of *C4B* copies in chronic CSC patients leads to lower systemic C4B levels. This may indicate that an overall lower activity of the complement system might be present in chronic CSC patients.

Recently, low copy numbers of *C4B* have been described to be associated with hyperreactivity of the HPA axis.¹⁶ Banlaki et al. showed that in patients with adrenal incidentaloma and low (<2 copies) *C4B* genomic copy number, baseline ACTH was significantly reduced compared to high (≥2 copies) genomic copy number of *C4B*.¹⁶ Moreover, a significantly higher cortisol response was observed after ACTH stimulation in the patients with low *C4B* genomic copy number.¹⁶

These results are of interest in the context of chronic CSC because of the described clinical associations with stress and the use of corticosteroids that both exert physiological effects at the level of the HPA axis.¹⁷ Various relatively small studies have studied cortisol levels in chronic CSC patients. Although 24h urine samples showed elevated cortisol levels in chronic CSC patients in certain studies,^{34, 35} these results were not observed in single serum measurements during set times in other studies.^{36, 37} These discrepancies could be explained by variable cortisol fluctuations between individuals during the day, and therefore changes in endogenous cortisol levels cannot be ruled out as a hallmark of chronic CSC. It is possible that patients with chronic CSC generally have normal cortisol levels, but respond differently to stimulation of the HPA axis. Stress, which also appears to be associated with chronic CSC,^{2, 38} stimulates the HPA axis and could lead to temporarily elevated cortisol levels in patients as compared to healthy individuals. How high levels of cortisol can lead to subretinal fluid accumulation is currently unknown. A study in rats suggested that the disease mechanism could be mediated by binding of corticosteroids to the mineralocorticoid receptor.³⁹ In this study, activation of the mineralocorticoid receptor caused vascular effects similar to those observed in chronic CSC,³⁹ but the underlying pathways still remain to be elucidated.

The mechanism through which low copy numbers of *C4B* may lead to hyperresponsiveness of the HPA axis is unclear. It has been hypothesized that it is not the *C4B* gene, but rather the neighboring *CYP21A2* gene that mediates this effect.¹⁶ The *CYP21A2* gene encodes the enzyme 21-hydroxylase, which plays an important role in the steroid metabolism pathway by converting progesterone and 17-alpha-hydroxyprogesterone to 11-deoxycorticosterone and 11-deoxycortisol, respectively. Because of the genomic structure of the RCCX locus, variation in the *CYP21A2* gene is in high linkage disequilibrium with variation in the neighboring *C4* gene (*C4A* or *C4B*, respectively).¹⁶ Therefore, further exploration of the precise structure and specific variations present in the RCCX locus may reveal new insights into the pathogenesis of chronic CSC.

The current study and previous studies identified an association between complement genes and chronic CSC,^{7,8} suggesting that the complement system may be dysregulated in chronic CSC. Taken together, these findings may indicate that the immune system, influenced by environmental factors, such as stress, could play a pivotal role in the pathophysiology of chronic CSC. Further studies are necessary to determine the physiological effects of genetic variation at the *C4* gene and the RCCX locus in chronic CSC.

References

1. Wang M, Munch IC, Hasler PW, Prunte C, Larsen M. Central serous chorioretinopathy. *Acta Ophthalmol* 2008;86:126-145.
2. Gemenetzi M, De Salvo G, Lotery AJ. Central serous chorioretinopathy: an update on pathogenesis and treatment. *Eye (Lond)* 2010;24:1743-1756.
3. Nicholson B, Noble J, Forooghian F, Meyerle C. Central serous chorioretinopathy: update on pathophysiology and treatment. *Surv Ophthalmol* 2013;58:103-126.
4. Liew G, Quin G, Gillies M, Fraser-Bell S. Central serous chorioretinopathy: a review of epidemiology and pathophysiology. *Clin Experiment Ophthalmol* 2013;41:201-214.
5. Yannuzzi LA. Central serous chorioretinopathy: a personal perspective. *Am J Ophthalmol* 2010;149:361-363.
6. Bouzas EA, Karadimas P, Pournaras CJ. Central serous chorioretinopathy and glucocorticoids. *Surv Ophthalmol* 2002;47:431-448.
7. Miki A, Kondo N, Yanagisawa S, Bessho H, Honda S, Negi A. Common variants in the complement factor H gene confer genetic susceptibility to central serous chorioretinopathy. *Ophthalmology* 2014;121:1067-1072.
8. de Jong EK, Breukink MB, Schellevis RL, et al. Chronic central serous chorioretinopathy is associated with genetic variants implicated in age-related macular degeneration. *Ophthalmology* 2015;122:562-570.
9. Hageman GS, Anderson DH, Johnson LV, et al. A common haplotype in the complement regulatory gene factor H (HF1/CFH) predisposes individuals to age-related macular degeneration. *Proc Natl Acad Sci U S A* 2005;102:7227-7232.
10. Fritsche LG, Chen W, Schu M, et al. Seven new loci associated with age-related macular degeneration. *Nat Genet* 2013;45:433-439, 439e431-432.
11. Anderson DH, Radeke MJ, Gallo NB, et al. The pivotal role of the complement system in aging and age-related macular degeneration: hypothesis re-visited. *Prog Retin Eye Res* 2010;29:95-112.
12. Ricklin D, Hajishengallis G, Yang K, Lambris JD. Complement: a key system for immune surveillance and homeostasis. *Nat Immunol* 2010;11:785-797.
13. Hou S, Qi J, Liao D, et al. High C4 gene copy numbers protects against Vogt-Koyanagi-Harada syndrome in Chinese Han. *Br J Ophthalmol* 2014;98:1733-1737.
14. Hou S, Qi J, Liao D, et al. Copy number variations of complement component C4 are associated with Behcet's disease but not with ankylosing spondylitis associated with acute anterior uveitis. *Arthritis Rheum* 2013;65:2963-2970.
15. Yang Y, Chung EK, Wu YL, et al. Gene copy-number variation and associated polymorphisms of complement component C4 in human systemic lupus erythematosus (SLE): low copy number is a risk factor for and high copy number is a protective factor against SLE susceptibility in European Americans. *Am J Hum Genet* 2007;80:1037-1054.

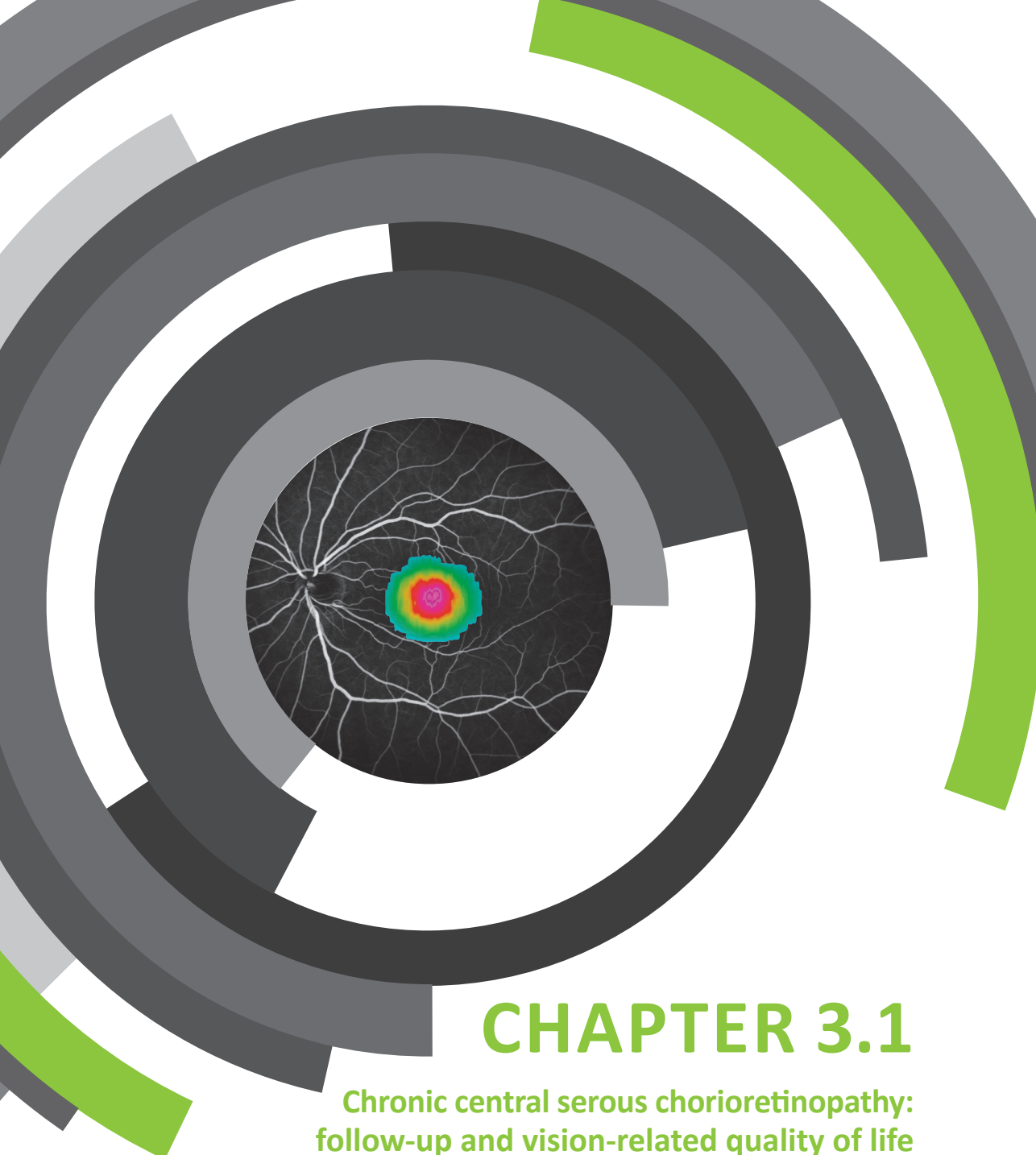
16. Banlaki Z, Raizer G, Acs B, et al. ACTH-induced cortisol release is related to the copy number of the *C4B* gene encoding the fourth component of complement in patients with non-functional adrenal incidentaloma. *Clin Endocrinol (Oxf)* 2012;76:478-484.
17. Aguilera G. Regulation of pituitary ACTH secretion during chronic stress. *Front Neuroendocrinol* 1994;15:321-350.
18. Wu YL, Savelli SL, Yang Y, et al. Sensitive and specific real-time polymerase chain reaction assays to accurately determine copy number variations (CNVs) of human complement *C4A*, *C4B*, *C4-long*, *C4-short*, and *RCCX* modules: elucidation of *C4* CNVs in 50 consanguineous subjects with defined HLA genotypes. *J Immunol* 2007;179:3012-3025.
19. Szilagy A, Fust G. Diseases associated with the low copy number of the *C4B* gene encoding *C4*, the fourth component of complement. *Cytogenet Genome Res* 2008;123:118-130.
20. Olsson LM, Holmdahl R. Copy number variation in autoimmunity--importance hidden in complexity? *Eur J Immunol* 2012;42:1969-1976.
21. Chung EK, Yang Y, Rennebohm RM, et al. Genetic sophistication of human complement components *C4A* and *C4B* and *RP-C4-CYP21-TNX* (*RCCX*) modules in the major histocompatibility complex. *Am J Hum Genet* 2002;71:823-837.
22. Banlaki Z, Szabo JA, Szilagy A, et al. Intraspecific evolution of human *RCCX* copy number variation traced by haplotypes of the *CYP21A2* gene. *Genome Biol Evol* 2013;5:98-112.
23. Blanchong CA, Zhou B, Rupert KL, et al. Deficiencies of human complement component *C4A* and *C4B* and heterozygosity in length variants of *RP-C4-CYP21-TNX* (*RCCX*) modules in caucasians. The load of *RCCX* genetic diversity on major histocompatibility complex-associated disease. *J Exp Med* 2000;191:2183-2196.
24. Yu CY, Belt KT, Giles CM, Campbell RD, Porter RR. Structural basis of the polymorphism of human complement components *C4A* and *C4B*: gene size, reactivity and antigenicity. *EMBO J* 1986;5:2873-2881.
25. Lv Y, He S, Zhang Z, et al. Confirmation of *C4* gene copy number variation and the association with systemic lupus erythematosus in Chinese Han population. *Rheumatol Int* 2012;32:3047-3053.
26. Ptacek T, Li X, Kelley JM, Edberg JC. Copy number variants in genetic susceptibility and severity of systemic lupus erythematosus. *Cytogenet Genome Res* 2008;123:142-147.
27. Eckstein MB, Spalton DJ, Holder G. Visual loss from central serous retinopathy in systemic lupus erythematosus. *Br J Ophthalmol* 1993;77:607-609.
28. Cunningham ET, Jr., Alfred PR, Irvine AR. Central serous chorioretinopathy in patients with systemic lupus erythematosus. *Ophthalmology* 1996;103:2081-2090.
29. Bouzas E, Mastorakos G. Central serous retinopathy in systemic lupus erythematosus: a manifestation of the disease or of its treatment? *Br J Ophthalmol* 1994;78:420-421.
30. Bouyon A, Costedoat-Chalumeau N, Limal N, et al. [Central serous chorioretinopathy and systemic diseases report of 2 cases associated with corticotherapy]. *Rev Med Interne* 2006;27:487-491.
31. Margery-Muir AA, Wetherall JD, Castley AS, et al. Establishment of gene copy number-specific normal ranges for serum *C4* and its utility for interpretation in patients with chronically low serum *C4* concentrations. *Arthritis Rheumatol* 2014;66:2512-2520.

32. Uko G, Christiansen FT, Dawkins RL, McCann VJ. Reference ranges for serum C4 concentrations in subjects with and without C4 null alleles. *J Clin Pathol* 1986;39:573-576.
33. Yang Y, Chung EK, Zhou B, et al. Diversity in intrinsic strengths of the human complement system: serum C4 protein concentrations correlate with C4 gene size and polygenic variations, hemolytic activities, and body mass index. *J Immunol* 2003;171:2734-2745.
34. Haimovici R, Rumelt S, Melby J. Endocrine abnormalities in patients with central serous chorioretinopathy. *Ophthalmology* 2003;110:698-703.
35. Shang Q, Liu C, Wei S, Shi F, Li Y, Qiao L. [Determination of cortisol in plasma and 24-hour urine of patients with central serous chorioretinopathy]. *Zhonghua Yan Ke Za Zhi* 1999;35:297-299.
36. Tufan HA, Gencer B, Comez AT. Serum cortisol and testosterone levels in chronic central serous chorioretinopathy. *Graefes Arch Clin Exp Ophthalmol* 2013;251:677-680.
37. Zakir SM, Shukla M, Simi ZU, Ahmad J, Sajid M. Serum cortisol and testosterone levels in idiopathic central serous chorioretinopathy. *Indian J Ophthalmol* 2009;57:419-422.
38. Yannuzzi LA. Type A behavior and central serous chorioretinopathy. *Trans Am Ophthalmol Soc* 1986;84:799-845.
39. Zhao M, Celerier I, Bousquet E, et al. Mineralocorticoid receptor is involved in rat and human ocular chorioretinopathy. *J Clin Invest* 2012;122:2672-2679.

CHAPTER 3

Clinical characteristics of chronic central serous chorioretinopathy





CHAPTER 3.1

Chronic central serous chorioretinopathy: follow-up and vision-related quality of life

Myrte B. Breukink,* Alexander J.M. Dingemans,* Anneke I. den Hollander, Jan E.E. Keunen,
Robert E. MacLaren, Sascha Fauser, Giuseppe Querques, Carel B. Hoyng,
Susan M. Downes & Camiel J.F. Boon

Accepted for publication in: *Clinical Ophthalmology*
(*joint first author)

Purpose:

To describe the clinical findings and long-term outcome of patients with chronic central serous chorioretinopathy (CSC).

Methods:

Retrospective case series in 52 eyes of 36 patients with a follow-up period of at least one year. Extensive ophthalmic examination, and a validated questionnaire concerning vision-related quality of life (NEI-VFQ-39) were analyzed.

Results:

The mean visual acuity (VA) showed a significant decline over time of 0.16 LogMAR (range:-0.22-1.30 LogMAR, $P = 0.009$) after a mean follow-up period of 10.6 years. Also, patients reported a lower vision-related quality of life based on the NEI-VFQ-39 for almost all categories compared to healthy controls. Macular atrophy was diagnosed more often on optical coherence tomography (OCT) as compared to other diagnostic entities. Retinal pigment epithelium (RPE) detachments in the macula were documented on OCT in 56% of the patients. We measured a significant thinning of the foveal thickness over time as compared to non affected fellow eyes ($P=0.002$). On long-term follow-up, 13 eyes (37%) showed an increase of the number of hot spots on fluorescein angiography.

Conclusions:

This study indicates that chronic CSC is a progressive disease in many patients, causing a progressive decline in VA, accompanied by a lower reported vision-related quality of life. In deciding whether or not to treat, the progressive nature of chronic CSC should be taken into account in this relatively young and often still professionally active patient group.

Introduction

Central serous chorioretinopathy (CSC) is characterized by a fluid accumulation between the neuroretina and the retinal pigment epithelium (RPE).^{1,2} It often affects the macula, leading to central vision loss, scotoma, metamorphopsia and/or micropsia.^{1,2} The accumulation of subretinal fluid (SRF) results from leakage through a dysfunctional RPE with a disrupted outer blood-retinal barrier. Dilation, congestion and hyperpermeability of the choriocapillaris and larger choroidal vessels appear to play a pivotal role in the pathogenesis of CSC.^{3,4,5}

The etiology of CSC is unknown. Risk factors for CSC include the use of corticosteroids, Cushing's disease, pregnancy, and male gender.^{2,6} Recent studies have also found genetic associations.^{7,8}

There are two main subtypes of CSC. Acute CSC is characterized by sudden vision loss due to fluid leakage through a focal pinpoint leak in the RPE, often in association with a small RPE detachment.^{1,2} In most acute CSC patients the SRF resolves spontaneously within 2-3 months.¹ The visual acuity (VA) in these patients generally returns to (near-)normal levels.¹ In the other main subtype, chronic CSC, patients have more widespread atrophic RPE abnormalities, as well as more extensive choroidal changes on fluorescein angiography (FA) and indocyanine green angiography (ICGA).^{1,2} In contrast to acute CSC, most patients with chronic CSC have a more pronounced central vision loss, and often do not show a spontaneous resolution of SRF.²

Although chronic CSC is one of the most common forms of macular degeneration,¹ relatively little is known about the long-term visual consequences in these patients. The aim of this study was evaluate the clinical outcome of patients with chronic CSC, and assess the vision-related quality of life to provide a more accurate prognosis to patients.

Materials and Methods

Participants

Patients with chronic CSC and a follow-up time of at least one year were included in this retrospective observational study. Subjects were recruited from the Department of Ophthalmology of the Radboud University Medical Center (Nijmegen, the Netherlands), and at the Oxford Eye Hospital (Oxford, United Kingdom). The diagnosis chronic CSC was defined as the presence of SRF longer than 3 months in at least 1 eye on optical coherence tomography (OCT), RPE window defects on FA with at least 1 “hot spot”, defined as indistinct hyperfluorescent area of leakage, and/or diffuse leakage in the affected eye(s), and corresponding hyperfluorescent zones on ICGA when available. Patients with evidence of other retinal diagnoses at the first visit, were excluded. This study adhered to the tenets of the Declaration of Helsinki, and approval for the study was obtained from the local institutional review board in Oxford, United Kingdom and waived by the local institutional board in Nijmegen, The Netherlands.

The following parameters, when available, were collected from the medical records: visual acuity (VA), disease activity, duration of visual symptoms, the (prior) use of corticosteroids, number of treatments, colour fundus photography, OCT, FA, and ICGA. Only visits for which VA and information about the disease activity, defined as subfoveal fluid on OCT or - when OCT was not available - as stated by the ophthalmologist in the medical records, were included.

Additionally, patients were asked to complete a validated questionnaire (Visual Function Questionnaire (VFQ-39)).⁹ For all Dutch patients a validated Dutch translation of this questionnaire was used.¹⁰

Clinical evaluation

Submacular RPE detachments, subfoveal SRF, change in submacular SRF accumulation and retinal atrophy were scored on OCT. The number of hot spots, defined as indistinct hyperfluorescent areas of leakage, seen on FA and ICGA were registered. Evidence of atrophy was assessed on FA and colour fundus photography.

Central foveal thickness (CFT), defined as the distance between the outer part of the internal limiting membrane and the outer part of the external limiting membrane at the central fovea, of the first and the last available OCT scans was measured by two independent graders. Only patients who had follow-up imaging with spectral domain OCT (OCT, Spectralis™, Heidelberg Engineering, Heidelberg, Germany) were included in CFT measurements. The mean of the measurements of both graders was used for further analysis, after no significant difference between the graders was confirmed by a student’s independent t-test (p -value > 0.05). In selected patients, the non-affected fellow eyes, defined as eyes in which no central lesions suspect for chronic CSC were present, were included. The difference in CFT over time was compared between the affected and non-affected eyes using a student’s independent t-test.

Visual acuity

The VA of all first visits was compared to the VA of all last known visits using an independent samples t-test. For the VA of the last visits, only patients with inactive disease, defined as absence of SRF on OCT, were included. Additionally, a Pearson correlation test was performed to determine if the number of episodes of active disease or the number of treatments affected the overall change in VA when comparing the first visit to the last visit.

Vision-related quality of life

The scores of every individual subcategory of the VFQ-39 questionnaire were compared to the reference group, which was used for the assessment in the original validation of the VFQ-39,⁹ using the independent samples t-test. The original validation of the VFQ-39 analysed the data of the reference group as being normally distributed, therefore this article also chose this approach. A Pearson correlation test was performed to analyse if VA at the end of follow-up was associated with the score on the VFQ-39 questionnaire.

A p-value < 0.05 was considered statistically significant for all tests.

Results

Demographics

The demographic information is presented in **Table 1**. The mean number of episodes of active disease per eye was 1.7 (range 0-6). Each episode was defined as a presence of documented SRF followed by a period of OCT-proven absence of SRF.

Table 1. Demographics of the study population

Parameters	Nijmegen	Oxford	Total
Patients (affected eyes)	22 (33)	14 (19)	36 (52)
Sex (male/female)	13/9	8/6	21/15
Mean age (years)	56.9 (range 42 - 72 years)	56.3 (range 39 - 81 years)	56.7 (range 39 - 81 years)
Bilateral disease (patients)	11 (50%)	5 (36%)	16 (44%)
Reported steroid use (patients)	6 (27%)	4 (29%)	10 (28%)
Mean follow-up (years)	9.8 (range 1 - 24 years)	3.8 (range 1 - 11 years)	7.4 (range 1 - 24 years)
Mean number of treatments per eye	3.2 (range 0 - 8)	0.1 (range 0 – 1)	2.1 (range 0 – 8)

Clinical course

When comparing the VA of the first and last visit, excluding the 21 eyes (40%) with persistent subfoveal SRF at the final visit, a mean decline of 0.16 LogMAR (range -0.22-1.30, $p = 0.009$) was found after a mean follow-up period of 10.6 years (range 1.5-24). In the 21 eyes (40%) with persistent subfoveal SRF at the final visit, a mean decline of 0.22 LogMAR (range -0.35-0.66, $p = 0.003$) with a mean follow-up period of 4.5 years (range 1-11 years) was seen. In 11 of these 21 eyes (52%) the SRF was continuously present during follow-up. The number of episodes of active disease, and number of treatments did not have a significant effect on the overall change of VA.

Optical coherence tomography

An overview of the findings on OCT is displayed in **Table 2** and **Figure 1A-C**. In the 13 eyes with a decrease of SRF, 8 eyes (62%) had received treatment. The 7 eyes with an increase of SRF, had not received treatment. In the eyes showing fluctuating SRF accumulation, 18 eyes (82%)

had received treatment. The following treatments were performed: 41 micropulse therapy (MP), 23 photodynamic therapy (PDT), 1 Argon laser treatment, 1 Retaane® (anecortave acetate) treatment and 9 anti-vascular endothelial growth factor (VEGF) treatments. In 14 eyes (24%) SRF was continuously present on OCT until the last follow-up. In this group this was also the case in 5 eyes (36%) despite receiving treatment (including MP (52%), PDT (29%), anti-VEGF (14%), and argon laser treatment (5%)). Posterior cystoid retinal degeneration as described previously by Piccolino et al was seen in 7 eyes of 4 patients (8%) (**Figure 1 F-G**).¹¹ In 3 of these 7 eyes a lesion which was suspected to be a choroidal neovascularisation developed during follow-up. In 3 of 7 eyes the posterior cystoid retinal degeneration disappeared completely during follow-up, in 2 eyes this resolution occurred spontaneously and in 1 eye after PDT (**Figure 1H,I**). The onset of posterior cystoid retinal degeneration was respectively 2, 10 and 16 years after the reported start of the chronic CSC in 3 of the 4 patients in whom this was recorded (**Figure 1D-G**). In 21 eyes (41%) with SRF and 6 eyes without SRF a spectral domain OCT was available for evaluation of CFT on follow-up. The CFT showed a mean decrease of 15.1 µm (standard deviation: 17.7 µm) in the eyes with SRF, whereas no significant change was seen in the eyes without SRF. This difference in CFT was statistically significant ($p = 0.002$).

Fluorescein angiography, indocyanine green angiography and colour fundus photography

Characteristics of hot spots of leakage on FA on follow-up are shown in **Table 2**. Of the 9 eyes that showed a decrease in the number of hot spots during follow-up, in 7 eyes the original hot spots disappeared after treatment, whereas the number of hot spots decreased spontaneously in the remaining 2 eyes. Overall the mean number of hot spots at the first visit was 1.0 (range 0-4) compared to 1.7 (range 0-7) at the last visit (**Figure 2A,B**). An increase of atrophic RPE changes on FA was seen in 14 eyes (41%) during a mean follow-up of 9.7 years (range 2-24 years).

A classic “gravitational tract” was seen in 8 eyes (15%), and was already present at the first visit in 5 eyes (**Figure 2C-D**). The other 3 eyes developed the gravitational tract after approximately 2, 4 and 8 years, respectively.

When ICGA was available (in 28 (54%) eyes), we were able to compare hot spots and hyperfluorescent areas on ICGA in 27 eyes (96%) with characteristics on FA that was performed on the same date. The overall hyperfluorescent area was larger on ICGA in 8 (30%) eyes, in 11 (41%) eyes the hyperfluorescent area had a comparable size, in 1 (4%) eye the hyperfluorescent area was smaller on ICGA, and in 8 eyes (30%) no clear hyperfluorescence was seen on ICGA to be compared (**Figure 2E,F**). In 11 eyes (39%) ICGA showed multiple small punctate hyperfluorescent spots, without clear evidence of a leaking hot spot focus (**Figure 2G-H**).

Colour fundus photography was available at baseline in 42 eyes (81%), and mild RPE atrophy in the macula was seen in 18 eyes (43%). Follow-up images were available for 31 (74%) eyes

with a mean follow-up of 45 months (range 1.5-87 months), and evidence of development and/or progression of RPE atrophy was present in 14 (45%) eyes.

Table 2. An overview of the findings on optical coherence tomography and fluorescein angiography

Optical coherence tomography	Fluorescein angiography
No. RPE detachments	No. hot spots at first visit (N=45)
0 = 23 eyes (44%)	1 =13 eyes (29%)
≥ 1 = 29 eyes (56%)	2 = 7 eyes (16%)
Subfoveal SRF	≥ 3 = 3eyes (7%)
yes = 40 eyes (77%)	diffuse leakage = 7 eyes (16%)
no = 12 eyes (23%)	no clear leakage = 15 eyes (33%)
Outer photoreceptor layer atrophy	Change in no. of hot spots (N=35)
yes = 24 eyes (49%)	increase = 13 eyes 37%
no = 28 eyes (51%)	decrease = 9 eyes (26%)
Change of height of SRF accumulation (N=49)	no change = 2 eyes (6%)
decrease = 13 (27%)	new hot spot ^{1,2} = 2 eyes (6%)
increase = 7 (14%)	no clear hot spot ³ = 9 eyes (26%)
no change = 3 (6%)	
fluctuation = 26 (53%)	

RPE; retinal pigment epithelium, SRF; subretinal fluid

¹ Hot spot defined as indistinct hyperfluorescent area of leakage

² Disappearance of the original hot spot and appearance of a new hot spot

³ No distinct hot spot at first visit

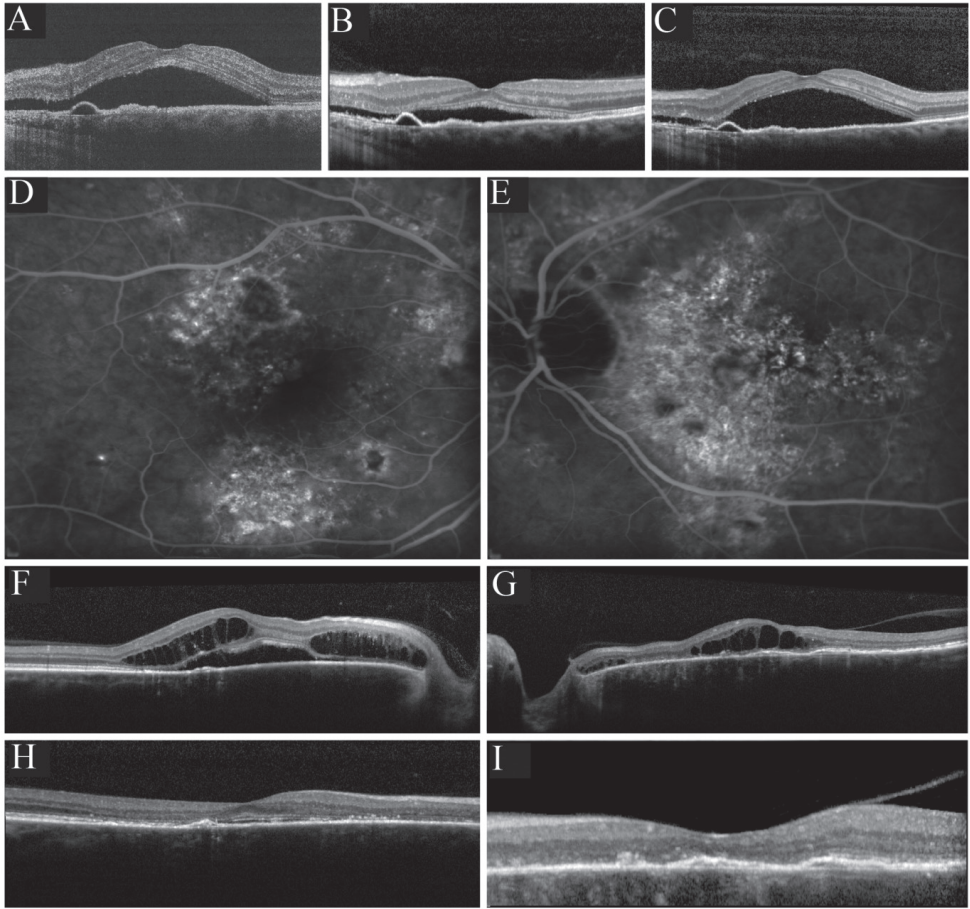


Figure 1.

Imaging of two chronic central serous chorioretinopathy (CSC) patients demonstrating characteristic findings in long-standing chronic CSC on optical coherence tomography (OCT) and fluorescein angiography (FA). Images **A-C** illustrate a fluctuating subretinal fluid (SRF) accumulation on OCT in the right eye of a patient, and typical subfoveal retinal pigment epithelium detachments. The time between scan **A** and **B** is 1 month, in which a clear decrease of SRF occurs, and between scan **B** and **C** another 2 weeks elapsed, showing a spontaneous increase of SRF. No therapeutic interventions had been performed between these visits. Images **D-G** represent the FA and OCT of the right and left eye of a chronic CSC patient suffering from bilateral extensive chronic CSC. On FA a large area of hyperfluorescence can be seen indicating advanced disease (**D-E**). OCT shows not only serous SRF in the right eye, but also bilateral central posterior cystoid degeneration, indicative of long-standing disease (**F-G**). This central posterior cystoid degeneration resolved spontaneously after a period of approximately 6 months (**H-I**).

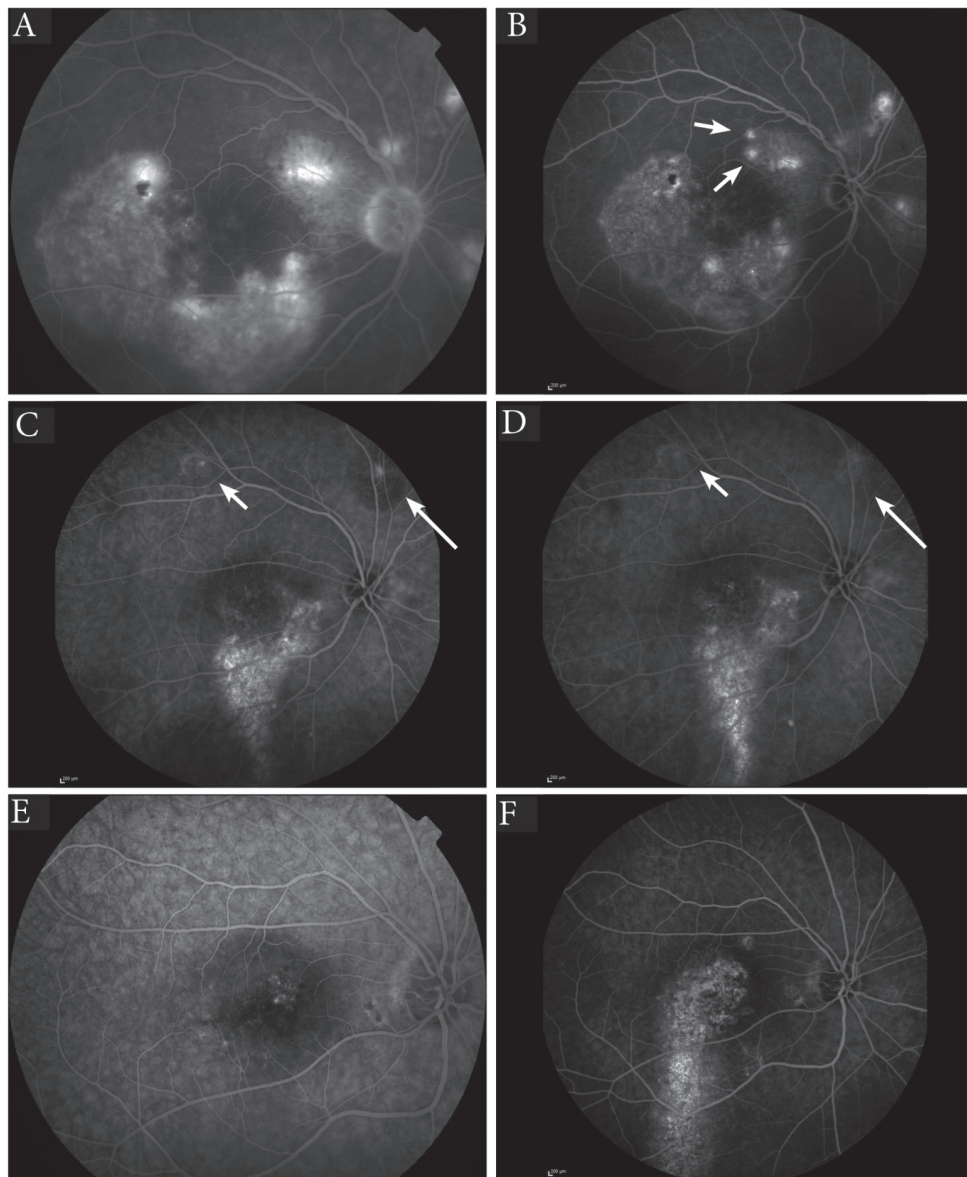


Figure 2.

Abnormalities on fluorescein angiography (FA), indocyanine green (ICG) angiography and fundus autofluorescence (FAF) in chronic central serous chorioretinopathy (chronic CSC). **A-B**, The appearance of 'new' hot spots, highlighted by two arrows, on FA during 4 years of follow-up. On image **C** and **D** the development of a gravitational tract was observed originating from the initial leakage area after 6 years of follow-up. **E-F**, Example of differences seen in the extent of the hyperfluorescence areas between FA (**E**) and ICGA (**F**). The area depicted by the arrow shows clear hyperfluorescence on ICGA, but is not evident on the mid-phase FA. **G-H**, ICGA (**H**) shows small punctiform hyperfluorescent areas in addition to diffuse hyperfluorescence. The corresponding FA (**G**) of the same patient shows an area of hyperfluorescence that is significantly smaller than the area seen on ICGA.

Quality of life

Patients of this chronic CSC cohort scored significantly less on the VFQ-39 questionnaire as compared to the reference group on 8 of the 12 subcategories (**Table 3**).

Patients with a lower last recorded VA scored significantly lower on the following categories of the VFQ-39: general vision, near activities, distance activities, social functioning, mental health, role difficulties, dependency and driving (**Table 3**).

Table 3. VFQ-39 questionnaire scores of the study population and controls, and Pearson correlation with last visual acuity

VFQ-39 item	Chronic CSC patients			Controls			Pearson correlation Last visual acuity	
	Subjects	Mean	SD	Subjects	Mean	SD	Pearson correlation	P-value
General Health	36	65	17	122	75	17	-0.146	0.396
General Vision	36	62	18	122	81	13	-0.360	0.031
Ocular Pain	36	85	17	122	90	15	-0.044	0.800
Near Activities	36	72	23	122	93	10	-0.435	0.008
Distance Activities	36	79	20	122	95	8	-0.475	0.003
Social Functioning	36	90	17	122	99	3	-0.416	0.012
Mental Health	36	72	22	122	91	11	-0.509	0.002
Role difficulties	36	74	22	122	96	6	-0.628	<0.001
Dependency	36	91	18	122	99	5	-0.408	0.013
Driving	31	70	29	122	89	14	-0.584	0.001
Colour Vision	36	94	19	122	98	8	-0.109	0.527
Peripheral Vision	36	80	26	122	97	10	-0.178	0.299

CSC = central serous chorioretinopathy; SD = Standard Deviation ; VFQ = Visual Function Questionnaire.

Discussion

This study shows that chronic CSC is a progressive chorioretinopathy with a significant impact on VA and vision-related quality of life.

Patients in this study cohort generally showed a progressive decline in VA as well as a gradual decrease in CFT on OCT. Wang et al previously demonstrated in the pre-OCT era that persistence of SRF for more than 4 months can result in foveal atrophy.¹² This permanent damage to photoreceptors and RPE can explain the often persistent visual complaints even after resolution of SRF. The progressive nature of chronic CSC is demonstrated on FA, characterized by an increase of hyperfluorescent atrophic RPE changes and an increased number of hot spots during follow-up.

An interesting finding in our study were the small punctate hyperfluorescent spots on ICGA (**Figure 2H**). Similar lesions have been described previously by Tsujikawa and co-workers.¹³ This group described small clusters, which were located within the center of the focal hyperfluorescent area on ICGA and were therefore thought to be very small leakage spots. In our study, no clear abnormalities corresponding to these lesions on ICGA could be identified on OCT. However, Lehmann et al identified similar hyperfluorescent lesions on ICGA that correlated with vascular dilations on en face enhanced-depth OCT.¹⁴ In contrast to the lesion seen in this study, the lesions were always located under an area of SRF accumulation and/or RPE detachment. Additionally, a clinical and pathogenetic overlap between CSC and polypoidal choroidal vasculopathy may exist. Punctate hyperfluorescent spots on ICGA have also been identified in polypoidal choroidal vasculopathy, in which these lesions correlated with a thicker choroid.¹⁵ We therefore hypothesize that these lesions may be focal vascular dilations in the choriocapillaris that fill on ICGA.

The blood flow in the choroid is among the highest in the human body, and the macular choriocapillaris is thicker, has a distinct lobular architecture and higher blood flow as compared to the peripheral choroid.^{16,17} These anatomical and functional choroidal differences, as well as anatomical differences between central and peripheral RPE and Bruch's membrane,^{18,19} probably explain why CSC principally affects the posterior pole. However, it is currently unclear why some individuals develop active CSC in the case of a dysfunctional thickened choroid ("pachychoroid") unlike others,²⁰ and why in the same individual the disease can remain subclinical in the fellow eye despite the presence of similar choroidal abnormalities.⁵ It is likely that additional factors play a role in determining an individual's likelihood to develop CSC, for instance patient-specific differences in genetic background,^{7,8} local differences in RPE outer blood-retinal function, and possibly the interphotoreceptor matrix.²¹

Our data show a marked decrease in reported vision-related quality of life in this chronic CSC cohort when compared to healthy individuals. Nevertheless, the impact of chronic CSC on vision-related quality of life seems to be less pronounced than in other common maculopathies such as neovascular age-related macula degeneration and diabetic retinopathy.^{22,23} In our chronic CSC cohort, social functioning and dependency seemed

to be most affected. Differences between the vision-related quality of life impact of the different diseases may not only be due to the variable effects on macular anatomy and visual function, but may also be partly explained by the difference in the mean age of the different study populations during which the VFQ-39 questionnaire was taken (present study 55 years, neovascular age-related macular degeneration 77 years, diabetic retinopathy 68 years, and diabetic macular oedema 62 years).²³ Also, the mean years since diagnosis was far shorter in the neovascular age-related macular degeneration studies compared to our study (respectively 0.6 and 7.4 years). A possible explanation could also be that younger individuals are more flexible and more capable to cope with newly developed visual impairment than older individuals.²⁴ Also, the negative impact on the reported vision-related quality of life appears to be higher when evaluated closer to the onset of visual impairment.

Surprisingly, we did not find a significant difference in the reported quality of colour vision, although impaired colour vision has been previously reported in CSC.²⁵ It is still possible that a disturbed colour vision exists in this cohort, but that it remains subclinical for instance due to a better-seeing fellow eye and does not interfere with the daily activities.

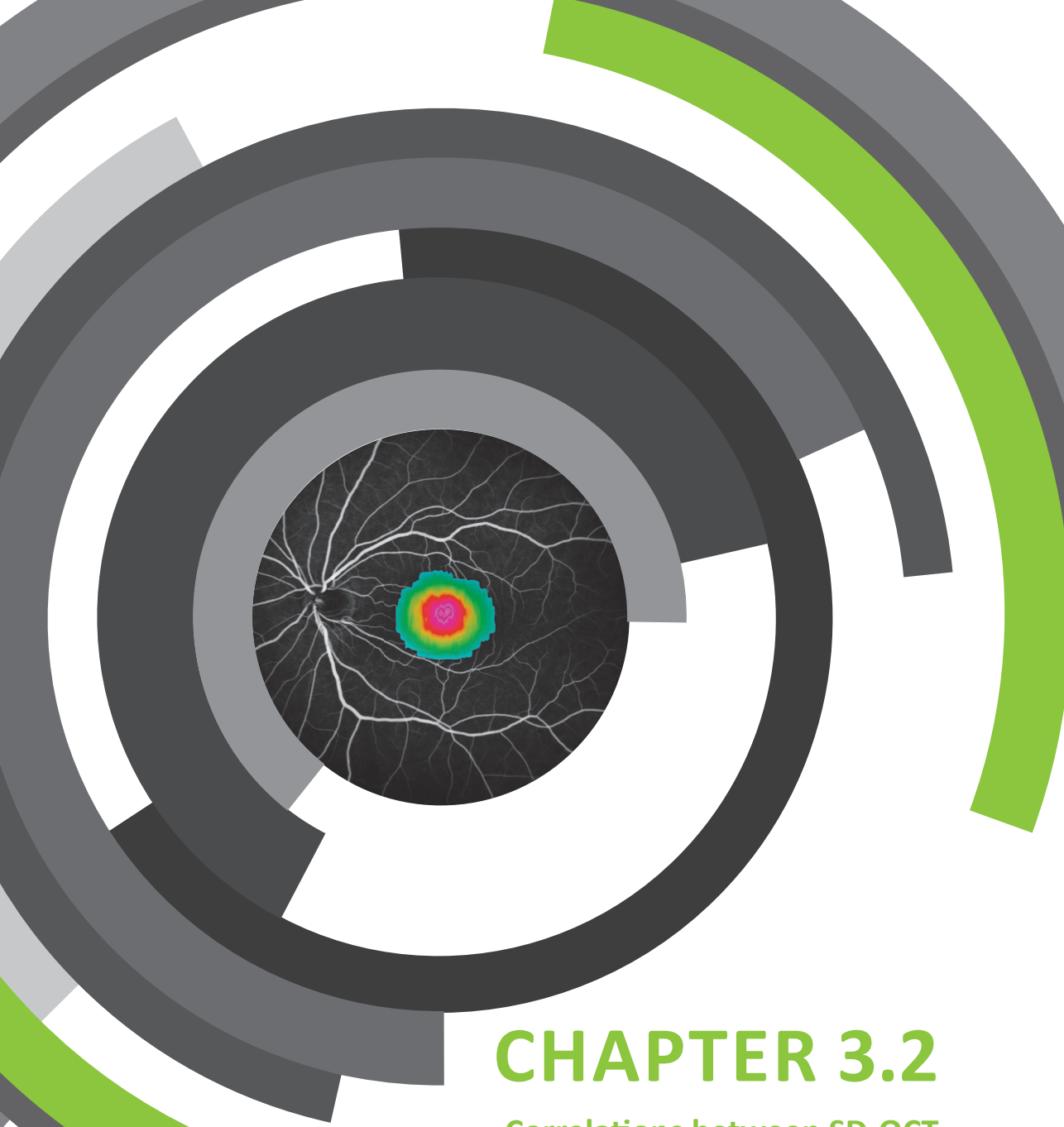
In conclusion, chronic CSC is a progressive chorioretinopathy with many chronic CSC patients experiencing significant vision loss, a lower vision-related quality of life, and a lower rating for overall health as compared to healthy individuals. Despite these observations, it is not uncommon for ophthalmologists to adopt a conservative approach in these patients who are often relatively young. Our findings demonstrate that the possible impact of chronic CSC should not be underestimated, and therefore an active treatment approach may be advocated. However, few high-quality randomized controlled treatment trials have been reported in chronic CSC, with a current lack of a gold standard for treatment of chronic CSC. We are currently performing a multicentre prospective randomized controlled treatment trial, comparing half-dose photodynamic therapy with high-density subthreshold micropulse laser treatment in chronic CSC [EudraCT number 2012-004555-36, NCT01797861] in an attempt to identify the most suitable treatment strategy in chronic CSC.

References

1. Liew G, Quin G, Gillies M, Fraser-Bell S. Central serous chorioretinopathy: a review of epidemiology and pathophysiology. *Clin Experiment Ophthalmol* 2013;41(2):201-14.
2. Nicholson B, Noble J, Forooghian F, Meyerle C. Central serous chorioretinopathy: update on pathophysiology and treatment. *Surv Ophthalmol* 2013;58(2):103-26
3. Guyer DR, Yannuzzi LA, Slakter JS, et al. Digital indocyanine green videoangiography of central serous chorioretinopathy. *Arch Ophthalmol* 1994;112(8):1057-62.
4. Prunte C, Flammer J. Choroidal capillary and venous congestion in central serous chorioretinopathy. *Am J Ophthalmol* 1996;121(1):26-34.
5. Kim YT, Kang SW, Bai KH. Choroidal thickness in both eyes of patients with unilaterally active central serous chorioretinopathy. *Eye (Lond)* 2011;25(12):1635-40.
6. Bouzas EA, Karadimas P, Pournaras CJ. Central serous chorioretinopathy and glucocorticoids. *Surv Ophthalmol* 2002;47(5):431-48.
7. Miki A, Kondo N, Yanagisawa S, et al. Common variants in the complement factor H gene confer genetic susceptibility to central serous chorioretinopathy. *Ophthalmology* 2014;121(5):1067-72.
8. de Jong EK BM, Schellevis RL, Bakker B, Mohr JK, Fauser S, Keunen JEE, Hoyng CB, den Hollander AI & Boon CJF Chronic central serous chorioretinopathy is associated with genetic variants implicated in age-related macular degeneration. *Ophthalmology* 2014.
9. Mangione CM, Lee PP, Gutierrez PR, et al. Development of the 25-item National Eye Institute Visual Function Questionnaire. *Arch Ophthalmol* 2001;119(7):1050-8.
10. Van der Sterre G, Van der Graaf FE, Verezen C. National Eye Institute Visual Functioning Questionnaire-25: Dutch consensus translation (VFQ-25 / NL). Rotterdam: Department of Ophthalmology, Erasmus Medical Center Rotterdam 2001.
11. Piccolino FC, De La Longrais RR, Manea M, Cicinelli S. Posterior cystoid retinal degeneration in central serous chorioretinopathy. *Retina* 2008;28(7):1008-12.
12. Wang MS, Sander B, Larsen M. Retinal atrophy in idiopathic central serous chorioretinopathy. *Am J Ophthalmol* 2002;133(6):787-93.
13. Tsujikawa A, Ojima Y, Yamashiro K, et al. Punctate hyperfluorescent spots associated with central serous chorioretinopathy as seen on indocyanine green angiography. *Retina* 2010;30(5):801-9.
14. Lehmann M, Wolff B, Vasseur V, Martinet V, Manasseh N, Sahel JA, Mauget-Faÿsse: Retinal and choroidal changes observed with 'En face' enhanced-depth imaging OCT in central serous chorioretinopathy. *Br J Ophthalmol* 2013;97(9):1181-6.
15. Park SJ, Kim BH, Park KH, Woo SJ. Punctate hyperfluorescence spot as a common choroidopathy of central serous chorioretinopathy and polypoidal choroidal vasculopathy. *Am J Ophthalmol* 2014.
16. Nickla DL, Wallman J. The multifunctional choroid. *Prog Retin Eye Res* 2010;29(2):144-68.
17. Alm A, Bill A. Ocular and optic nerve blood flow at normal and increased intraocular pressures in monkeys (*Macaca irus*): a study with radioactively labelled microspheres including flow determinations in brain and some other tissues. *Exp Eye Res* 1973;15(1):15-29.

18. Boulton M, Dayhaw-Barker P. The role of the retinal pigment epithelium: topographical variation and ageing changes. *Eye (Lond)* 2001;15(Pt 3):384-9.
19. Ramrattan RS, van der Schaft TL, Mooy CM, et al. Morphometric analysis of Bruch's membrane, the choriocapillaris, and the choroid in aging. *Invest Ophthalmol Vis Sci* 1994;35(6):2857-64.
20. Warrow DJ, Hoang QV, Freund KB. Pachychoroid pigment epitheliopathy. *Retina* 2013;33(8):1659-72.
21. Hageman GS, Marmor MF, Yao XY, Johnson LV. The interphotoreceptor matrix mediates primate retinal adhesion. *Arch Ophthalmol* 1995;113(5):655-60.
22. Suner IJ, Kokame GT, Yu E, et al. Responsiveness of NEI VFQ-25 to changes in visual acuity in neovascular AMD: validation studies from two phase 3 clinical trials. *Invest Ophthalmol Vis Sci* 2009;50(8):3629-35.
23. Lloyd AJ, Loftus J, Turner M, et al. Psychometric validation of the Visual Function Questionnaire-25 in patients with diabetic macular edema. *Health Qual Life Outcomes* 2013;11:10.
24. Cheng C, Lau HP, Chan MP. Coping flexibility and psychological adjustment to stressful lifechanges: a meta-analytic review. *Psychol Bull* 2014.
25. Maaranen TH, Tuppurainen KT, Mantyjarvi MI. Color vision defects after central serous chorioretinopathy. *Retina* 2000;20(6):633-7.





CHAPTER 3.2

Correlations between SD-OCT characteristics and response to half-dose photodynamic therapy in chronic central serous chorioretinopathy

Myrte B. Breukink, Freerk G. Venhuizen, Elon H.C. van Dijk, Anneke I. den Hollander, Jan E. E. Keunen, Carel B. Hoyng, Clara I. Sánchez & Camiel J.F. Boon

Manuscript in preparation

Purpose:

To analyse if characteristics of the subretinal fluid pocket in chronic central serous chorioretinopathy (CSC) on spectral-domain optical coherence tomography (SD-OCT) correlate with response to half-dose photodynamic therapy (PDT) treatment.

Methods:

Forty-eight eyes of 48 treatment-naive chronic CSC patients who underwent half-dose PDT for active chronic CSC as the first treatment were included. Clinical information including visual acuity, SD-OCT, fluorescein angiography, and indocyanine green angiography was retrospectively collected. The SRF collection seen on SD-OCT imaging was analysed by a machine-learning algorithm, specifically designed for this purpose. SRF volume and morphology, as well as SRF reflectivity characteristics were computed and correlated to response to half-dose PDT treatment (persistent or absent SRF on SD-OCT after treatment).

Results:

A complete resolution of SRF was seen in 24 eyes (51%). In a total of 47 SD-OCT scans (98%) the SRF accumulation could be segmented as a whole and SRF volume, and pixel information analyzed. The median intensity of the SRF accumulation was lower in the group with complete absence of SRF after treatment. Also, the skewness of the histogram of the pixel intensity values was significantly higher in this group. No significant difference was seen when comparing the total SRF volume before treatment between the groups.

Conclusions:

Characteristics of SRF on SD-OCT are significantly different between chronic CSC patients who do or do not respond well to half-dose PDT treatment. Using the described semi-automated segmentation program to analyse these imaging characteristics may help to predict response to half-dose PDT in chronic CSC patients.

Introduction

Central serous chorioretinopathy (CSC) is a relatively common early-onset eye disease, characterized by an accumulation of leaked serous subretinal fluid (SRF) causing a detachment of the neuroretina. This leakage of SRF results from dysfunction of the retinal pigment epithelium (RPE) outer blood-retinal barrier, caused by choroidal congestion and thickening and hyperpermeability of the choroid.¹⁻⁴ Although the etiology of CSC is largely unknown, previous studies have described the male gender, the use of corticosteroids, hypercortisolism, stress, and possibly type A personality as risk factors.^{1, 5, 6} Genetic predisposition also appears to play a role, as single nucleotide polymorphisms in the *Complement Factor H* and *ARMS2* have recently been found in association with sporadic chronic CSC,^{7, 8} and familial CSC cases have been described.^{9, 10}

In contrast to acute CSC, chronic CSC is usually not self-limiting, with persisting SRF on OCT. Persistent serous neuroretinal detachments can cause progressive and irreversible photoreceptor damage, resulting in a lower visual prognosis of chronic CSC as compared to acute CSC.^{2, 11, 12} Therefore, patients with chronic CSC who are affected by fluid leakage in the macula are often treated. A broad spectrum of treatment modalities has been used in chronic CSC, such as Argon or micropulse laser treatment of the leaking “hot spot” on fluorescein angiography (FA), intravitreal injections with anti-vascular endothelial growth factor or systemic drug treatments (e.g. spironolactone and eplerenone).^{2, 13-17} Currently, photodynamic therapy (PDT) is among the more frequently used treatments, that is effective in reducing SRF, with studies describing improvement of retinal anatomy and visual acuity (VA) in 70-100%.¹⁸⁻²² It is not precisely known why some patients respond well to PDT, and others respond poorly to therapy.

Inoue et al. found a correlation between the degree of hyperpermeability on indocyanine green angiography (ICGA) and the efficacy of PDT in CSC patient. In addition, Kim et al. demonstrated that patients that respond well to intravitreal injections with anti-vascular endothelial growth factor have a significant thicker subfoveal choroidal thickness on enhanced depth optical coherence tomography (OCT). OCT, which is a non-invasive imaging technique, gives high-resolution, cross-sectional images of the retina and choroid,²³ and can provide 3-dimensional information about the SRF accumulation, that can be used to monitor the disease activity over the time. Using retinal OCT-scans, correlations that have been found to be of importance in the prediction of the visual outcome are outer nuclear layer thickness in spontaneous resolved CSC,²⁴ and foveal thickness after resolution of SRF partially after photocoagulation.²⁵ In addition, Landa et al. also found a correlation between the thickness of the subfoveal deposits that are sometimes present in CSC and the BCVA and the time of spontaneous CSC resolution.²⁶

Recently, differences in the optical density ratio of the SRF accumulation in serous neuroretinal detachment were demonstrated to be a valuable tool to differentiate chronic CSC from polypoidal choroidal vasculopathy, two entities that may be strikingly similar and may partly have overlapping pathophysiology.²⁷⁻²⁹ In addition, Ahlers et al. found that the optical density ratio in the SRF correlates well with the functional outcome of an anti-vascular endothelial growth factor therapy in patients with age-related macular degeneration.³⁰

Also, in longer lasting SRF detachments, subretinal hyperreflective material on SD-OCT in chronic CSC can appear and may become increasingly prominent.³¹ Therefore, parameters obtained from SD-OCT in chronic CSC, which cannot be visualized with funduscopy or other imaging methods, could not only provide important information on the prognosis, but may also help in predicting the treatment outcome after half-dose PDT. The purpose of this explorative study was to identify possible biomarkers from the SRF accumulation on SD-OCT that can predict the treatment response to half-dose PDT in chronic CSC patients.

Methods

Patients

The patients enrolled for this retrospective case series were seen at the outpatient clinics of the Department of Ophthalmology of the Radboud University Medical Center, Nijmegen, the Netherlands between March 2012 and October 2014. The medical records of all patients who had been diagnosed with chronic CSC were retrospectively reviewed. Only treatment-naïve patients who received half-dose PDT as first therapy were considered for this study. The diagnosis chronic CSC was based on characteristic features as seen on multimodal imaging consisting of SD-OCT, FA and ICGA (according to previously described criteria).⁷ These criteria were defined as the presence of chronic serous SRF in at least one eye on SD-OCT, bilateral irregular RPE window defects on FA with at least one “hot spot” of leakage in the affected eye(s), and corresponding hyperfluorescent zones on ICGA. Patients who showed evidence of other diagnoses that could explain SRF accumulation, such as choroidal neovascularization, polypoidal choroidal vasculopathy, were excluded for this study. Approval for this study was obtained by the local institutional review boards, and the study adhered to the Declaration of Helsinki.

At the visit prior to the half-dose PDT therapy, and the first evaluation visit after therapy the following parameters were collected, if available: VA (LogMAR), onset of complaints, presence of SRF on SD-OCT, spot size and number of spots used for half-dose PDT treatment. Only patients who underwent an SD-OCT scan prior to half-dose PDT treatment and at the first evaluation visit after therapy were eligible for inclusion.

Half-dose photodynamic therapy

Pupils of the patients were dilated with 1.0% tropicamide and 2.5% phenylephrine. Verteporfin (Visudyne®) was intravenously administered at half dosage (3 mg/m²) as compared to the original protocol for neovascular age-related macular degeneration, with an infusion time of 10 minutes. At 15 minutes after the start of the infusion, an anesthetic eye drop was given (oxybuprocaine 0.4% or equivalent), a contact glass (a Volk® PDT lens) was positioned on the affected eye, and a laser beam was focused on the area to treat based on mid-phase (approximately 10 minutes) ICGA. PDT treatment was performed with standard 50 J/cm² fluency, a PDT laser wavelength of 689nm, and a standard treatment duration of 83 seconds.

Semi-automatic SRF segmentation

All SD-OCT images used in this study were made with the Spectralis HRA+OCT (Heidelberg Engineering, Heidelberg, Germany) at a wavelength of 870 nm, a horizontal resolution $\leq 15 \mu\text{m}$ and an axial resolution of up to $5 \mu\text{m}$. The number of slices varied from 18 to 60 B-scans per volume with 512 to 1536 A-scans per B-scan.

An image analysis algorithm was developed to automatically segment the 3-dimensional shape of the SRF from an arbitrarily selected seed point inside the SRF. The method applies a smart opening based region growing algorithm which uses intensity based similarity to determine if a pixel is part of the SRF or not. Therefore, the system performs the following steps:

- i. A seed point s_0 is manually placed in the SRF
- ii. s_0 is added to the set S called seeds
- iii. For each seed point s_i in S
 - a. Neighboring points p_n of s_i are identified
 - b. If the intensity of p_n is lower than a threshold T of the intensity of s_i , then p_n is added to S
 - c. Remove s_i from S
- iv. Repeat step iii until no seed points

After the segmentation of the SRF was obtained, a set of image biomarkers was extracted from the segmentation in order to capture the various characteristics of the SRF. These characteristics can be separated in two distinct groups, i.e., spatial characteristics, capturing the three-dimensional shape information, and reflectivity characteristics, which disregards the shape, and capture the pixel intensity characteristics of the fluid content.

The spatial characteristics were described using the following parameters: total volume (TV) in μl .

The reflectivity characteristics were described using the following parameters extracted from the raw pixel intensity values (greyscale range between 0 and 255): mean intensity (MI), median intensity (MedI), standard deviation of the intensity values (stdI), the kurtosis (KI), a measure for the "peakedness" of the histogram of pixel intensity values, and the skewness (SI), a measure for the symmetry of the histogram of pixel intensity values.

Definition of the outcomes

Efficacy of half-dose PDT was based on the anatomical result on SD-OCT, and defined absence of SRF as complete success. The outcome of half-dose PDT was compared with the following three variables analyzed on SD-OCT prior to the treatment: total volume of the SRF accumulation, MI and MedI of the fluid accumulation, and KI and SI.

Statistical analysis

MS-Excel version 2010 was used for data management. Statistical analyses were performed using IBM SPSS software for Windows version 20. For comparison of continuous numerical data in SD-OCT characteristics and study outcome (presence or absence of SRF on SD-OCT) we performed Mann-Whitney U test. Bonferroni correction for multiple testing was performed for three tests and p-values < 0.017 were considered to be statistically significant.

Results

Forty-six eyes of 46 chronic CSC patients (41 male, 5 female) with a mean age of 49 years (range: 29-67 years) were included in this study. For 42 eyes a date for the start of the complaints was reported, and in these eyes the mean time between start of the complaints and the SD-OCT scan was 82 weeks (range: 4 – 1037 weeks). The mean time between half-dose PDT and the first control visit was 8.6 weeks (range 4.9 – 20.3 weeks). In 24 eyes (51%) the PDT treatment resulted in a complete absence of SRF on SD-OCT.

In all eyes we were able to delineate the central SRF fluid pocket(s). In 1 eye (2%) the SRF fluid accumulation could not be computed as a whole, due to disruption by either debris or an RPE detachment. This eye was not included for the further analyses. In 7 eyes (15%) 2 separate SRF collections were detected. In these eyes the most central SRF accumulation was included for further analysis.

Skewness was significantly higher in the patients who had a complete absence of SRF after treatment (group 1) compared to those with persistent SRF on SD-OCT (group 2) (mean skewness 'group 1'; 1.09, SD: 0.38, range: 0.39 – 1.77 versus 'group 2'; 0.76, SD: 0.42, range: 0.12 – 1.72; $p=0.013$).

Comparison of the complete SRF volume before treatment between the patients in 'group 1' and 'group 2', did not show a significant difference (mean volume of SRF pocket in group 1'; 0.635 μl , standard deviation (SD): 1.47, range: 0.01 – 7.09 μl , versus a mean volume in group 2 of 0.383 μl , SD: 0.73, range: 0.01 – 3.33 μl , $p=0.476$).

When looking at the MI pixel intensity values of the SRF inside the fluid accumulation on SD-OCT, a possibly lower but statistically non-significant MI was seen in group 1 (mean intensity 'group 1'; 28.7 SD: 6.5, range: 17.09 – 41.51 versus group 2; 31.9, SD: 6.2, range: 15.58 – 41.01 $p=0.094$). Also, the median intensity appeared lower in this group (median intensity 'group 1'; 24.8, SD: 8.0, range: 12.00 – 41.00 versus 'group 2'; 29.8, SD: 7.2, range: 11.00 – 39.00 $p=0.038$). However, this difference was also not statistically significant after Bonferroni correction for multiple testing.

Finally, the correlation between the kurtosis and skewness of the histogram of the pixel intensity values between both groups was assessed. The kurtosis being appeared to be higher, although not statistically significant, in the 'group 1' (mean kurtosis 'group 1'; 1.50, SD: 1.33, range: -0.47 – 3.71 versus 'group 2'; 0.78, SD: 1.22, range: -0.96 – 3.14 $p=0.065$).

Discussion

In this study we analyzed the characteristics of the SRF accumulation on SD-OCT in chronic CSC. We were able to find significant differences in the characteristics of the SRF accumulation of SD-OCT between chronic CSC patients who respond well to half-dose PDT treatment, with a complete absence of SRF after treatment, and those who have persistent SRF. Assessment of the histogram of the intensity of the pixels inside the SRF accumulation on SD-OCT, showed a significantly higher skewness in the patients that respond well to half-dose PDT ($p=0.013$). The same may hold true for the median intensity, although significance was lost after Bonferroni correction ($p=0.038$). The total volume of the SRF accumulation did not show any significant correlation to the treatment outcome ($p=0.476$).

OCT is a non-invasive imaging technique that gives high-resolution, cross-sectional images of the retina and choroid,²³ and can provide 3-dimensional information about the SRF accumulation, which can be used to monitor the disease activity over the time. Several studies have shown correlations between the findings on OCT and the clinical outcome of patients with chronic CSC.^{24, 25, 32} These studies mainly focused on the anatomical changes located in the foveal neuroretina. Correlations found to be of importance in the prediction of the visual outcome are outer nuclear layer thickness in spontaneous resolved CSC,²⁴ and foveal thickness after resolution of SRF partially after photocoagulation.²⁵ Landa et al. also found a correlation between the thickness of the subfoveal deposits that are sometimes present in CSC and the BCVA and the time of spontaneous CSC resolution.²⁶ In longer lasting SRF detachments, subretinal hyperreflective material on SD-OCT in chronic CSC can appear and may become increasingly prominent,³¹ possibly due to progressive photoreceptor outer segment debris accumulation, in association with less efficient phagocytosis of this debris by a diseased RPE and/or SRF leakage that is less pronounced in the chronic stage of the disease.

Serous SRF accumulation is not an exclusive feature of CSC, and may also be seen for instance in diseases such as polypoidal choroidal vasculopathy, choroidal neovascularisation in age-related macular degeneration, and Best vitelliform macular dystrophy.

Differences in the optical density ratio of the SRF accumulation in serous neuroretinal detachment were recently demonstrated to be a valuable tool to differentiate chronic CSC from polypoidal choroidal vasculopathy, two entities that may be strikingly similar and may partly have overlapping pathophysiology.²⁷⁻²⁹ In addition, Ahlers et al. found that the optical density ratio in the SRF correlates well with the functional outcome of an anti-vascular endothelial growth factor therapy in patients with age-related macular degeneration.³⁰ These SD-OCT parameters in chronic CSC, which cannot be visualized with funduscopy or other imaging methods, can therefore not only provide important information on the

prognosis, but also seem to correlate with treatment outcome after half-dose PDT. In this study we describe a semi-automatic segmentation program for SD-OCT data, which can facilitate the reliable analysis of such SD-OCT parameters.

Numerous treatment options have been tried in chronic CSC patients over the past decades.^{2, 13-15} However, there is no international consensus on the optimal treatment of chronic CSC to date. In this study, we chose for half-dose PDT, which is the most frequently used treatment described in current literature.²⁰⁻²² Our findings suggest that a higher pixel intensity of the SRF accumulation exists in the patients that do not respond with a complete reduction of the SRF after PDT. The rationale of half-dose PDT is to reduce the fluid leakage from the hyperpermeable choroid by inducing remodeling of the choroidal vasculature, supposedly through selective vascular occlusion due to damage to choroidal endothelial cells and subsequent thrombotic events of the choriocapillaris.^{33, 34} Our findings suggest that chronic CSC patients with a higher pixel intensity on SD-OCT are less likely to achieve complete SRF resolution after half-dose PDT. A possible explanation may be that this higher intensity is a reflection of increased subretinal debris such as photoreceptor outer segments, that are less efficiently phagocytosed by an dysfunctional RPE due to longstanding, more inactive disease. In these less active cases, targeting the choroid with PDT may be too late to achieve optimal effect. It is currently unknown if persistence of SRF after half-dose PDT also resulted in a worse final visual outcome in this subgroup of chronic CSC patients.

Another limitation to this study was the relatively low sample size, which was due to the fact that only treatment-naive patients could be included.

In conclusion, this study shows that characteristics of SRF accumulation in chronic CSC patients correlates with the treatment outcome after half-dose PDT, using a new semi-automatic method of SD-OCT image analysis. Prospective studies in larger patient cohorts, such as the randomized controlled treatment trial that we are currently performing (EudraCT number 2012-004555-36, NCT01797861), are required to confirm the present findings. These findings may aid in achieving a more personalised healthcare approach in chronic CSC, in which patients can be identified who would have a higher likelihood to benefit from PDT treatment, or those who would require a different approach.

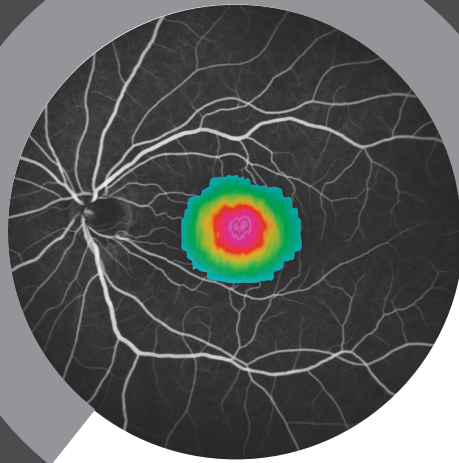
References

1. Liew G, Quin G, Gillies M, Fraser-Bell S. Central serous chorioretinopathy: a review of epidemiology and pathophysiology. *Clin Experiment Ophthalmol* 2013;41:201-214.
2. Wang M, Munch IC, Hasler PW, Prunte C, Larsen M. Central serous chorioretinopathy. *Acta Ophthalmol* 2008;86:126-145.
3. Gemenetzi M, De Salvo G, Lotery AJ. Central serous chorioretinopathy: an update on pathogenesis and treatment. *Eye (Lond)* 2010;24:1743-1756.
4. Nicholson B, Noble J, Forooghian F, Meyerle C. Central serous chorioretinopathy: update on pathophysiology and treatment. *Surv Ophthalmol* 2013;58:103-126.
5. Yannuzzi LA. Central serous chorioretinopathy: a personal perspective. *Am J Ophthalmol* 2010;149:361-363.
6. Bouzas EA, Karadimas P, Pournaras CJ. Central serous chorioretinopathy and glucocorticoids. *Surv Ophthalmol* 2002;47:431-448.
7. de Jong EK BM, Schellevis RL, Bakker B, Mohr JK, Fauser S, Keunen JEE, Hoyng CB, den Hollander AI & Boon CJF. Chronic central serous chorioretinopathy is associated with genetic variants implicated in age-related macular degeneration. *Ophthalmology* 2014;122(3):562-70
8. Miki A, Kondo N, Yanagisawa S, Bessho H, Honda S, Negi A. Common variants in the complement factor H gene confer genetic susceptibility to central serous chorioretinopathy. *Ophthalmology* 2014;121:1067-1072.
9. Weenink AC, Borsje RA, Oosterhuis JA. Familial chronic central serous chorioretinopathy. *Ophthalmologica* 2001;215:183-187.
10. Oosterhuis JA. Familial central serous retinopathy. *Graefes Arch Clin Exp Ophthalmol* 1996;234:337-341.
11. Loo RH, Scott IU, Flynn HW, Jr., et al. Factors associated with reduced visual acuity during long-term follow-up of patients with idiopathic central serous chorioretinopathy. *Retina* 2002;22:19-24.
12. Wang MS, Sander B, Larsen M. Retinal atrophy in idiopathic central serous chorioretinopathy. *Am J Ophthalmol* 2002;133:787-793.
13. Zhao M, Celerier I, Bousquet E, et al. Mineralocorticoid receptor is involved in rat and human ocular chorioretinopathy. *J Clin Invest* 2012;122:2672-2679.
14. Quin G, Liew G, Ho IV, Gillies M, Fraser-Bell S. Diagnosis and interventions for central serous chorioretinopathy: review and update. *Clin Experiment Ophthalmol* 2013;41:187-200.
15. Breukink MB, den Hollander AI, Keunen JE, Boon CJ, Hoyng CB. The use of eplerenone in therapy-resistant chronic central serous chorioretinopathy. *Acta Ophthalmol* 2014;92:e488-490.
16. Malik KJ, Sampat KM, Mansouri A, Steiner JN, Glaser BM. Low-intensity/high-density subthreshold micropulse diode laser for chronic central serous chorioretinopathy. *Retina* 2014.
17. Ricci F, Missiroli F, Regine F, Grossi M, Dorin G. Indocyanine green enhanced subthreshold diode-laser micropulse photocoagulation treatment of chronic central serous chorioretinopathy. *Graefes Arch Clin Exp Ophthalmol* 2009;247:597-607.

18. Chan WM, Lai TY, Lai RY, Tang EW, Liu DT, Lam DS. Safety enhanced photodynamic therapy for chronic central serous chorioretinopathy: one-year results of a prospective study. *Retina* 2008;28:85-93.
19. Valmaggia C, Haueter I, Niederberger H. Photodynamic therapy in the treatment of persistent central serous chorioretinopathy: a two-year follow-up. *Klin Monbl Augenheilkd* 2012;229:323-326.
20. Lai TY, Chan WM, Li H, Lai RY, Liu DT, Lam DS. Safety enhanced photodynamic therapy with half dose verteporfin for chronic central serous chorioretinopathy: a short term pilot study. *Br J Ophthalmol* 2006;90:869-874.
21. Nicolo M, Zoli D, Musolino M, Traverso CE. Association between the efficacy of half-dose photodynamic therapy with indocyanine green angiography and optical coherence tomography findings in the treatment of central serous chorioretinopathy. *Am J Ophthalmol* 2012;153:474-480 e471.
22. Rouvas A, Stavarakas P, Theodossiadis PG, et al. Long-term results of half-fluence photodynamic therapy for chronic central serous chorioretinopathy. *Eur J Ophthalmol* 2012;22:417-422.
23. Adhi M, Duker JS. Optical coherence tomography--current and future applications. *Curr Opin Ophthalmol* 2013;24:213-221.
24. Matsumoto H, Sato T, Kishi S. Outer nuclear layer thickness at the fovea determines visual outcomes in resolved central serous chorioretinopathy. *Am J Ophthalmol* 2009;148:105-110 e101.
25. Furuta M, Iida T, Kishi S. Foveal thickness can predict visual outcome in patients with persistent central serous chorioretinopathy. *Ophthalmologica* 2009;223:28-31.
26. Landa G, Barnett JA, Garcia PM, Tai KW, Rosen RB. Quantitative and qualitative spectral domain optical coherence tomography analysis of subretinal deposits in patients with acute central serous retinopathy. *Ophthalmologica* 2013;230:62-68.
27. Baek J, Park YH. Optical density ratio in the subretinal fluid: differentiating chronic central serous chorioretinopathy and polypoidal choroidal vasculopathy. *Am J Ophthalmol* 2015;159:386-392.
28. Yang LH, Jonas JB, Wei WB. Conversion of central serous chorioretinopathy to polypoidal choroidal vasculopathy. *Acta Ophthalmol* 2015;93(6):e512-4
29. Park HS, Kim IT. Clinical characteristics of polypoidal choroidal vasculopathy associated with chronic central serous chorioretinopathy. *Korean J Ophthalmol* 2012;26:15-20.
30. Ahlers C, Golbaz I, Einwallner E, et al. Identification of optical density ratios in subretinal fluid as a clinically relevant biomarker in exudative macular disease. *Invest Ophthalmol Vis Sci* 2009;50:3417-3424.
31. Wang M, Sander B, la Cour M, Larsen M. Clinical characteristics of subretinal deposits in central serous chorioretinopathy. *Acta Ophthalmol Scand* 2005;83:691-696.
32. Matsumoto H, Kishi S, Otani T, Sato T. Elongation of photoreceptor outer segment in central serous chorioretinopathy. *Am J Ophthalmol* 2008;145:162-168.
33. Ma J, Meng N, Xu X, Zhou F, Qu Y. System review and meta-analysis on photodynamic therapy in central serous chorioretinopathy. *Acta Ophthalmol* 2014;92:e594-601.

34. Schlotzer-Schrehardt U, Viestenz A, Naumann GO, Laqua H, Michels S, Schmidt-Erfurth U. Dose-related structural effects of photodynamic therapy on choroidal and retinal structures of human eyes. *Graefes Arch Clin Exp Ophthalmol* 2002;240:748-757.





CHAPTER 3.3

OCT angiography compared to fluorescein and indocyanine green angiography in chronic central serous chorioretinopathy

Michel M. Teussink, [Myrte B. Breukink](#), Mark J.J.P. van Grinsven, Carel B. Hoyng, B. Jeroen Klevering, Camiel J.F. Boon, Eiko K. de Jong & Thomas Theelen

Published in: *Investigative Ophthalmology and Visual Science*. 2015;56(9):5229-37

Purpose:

Abnormal choroidal blood flow is considered important in the pathogenesis of chronic central serous chorioretinopathy (CSC). Optical coherence tomography (OCT) angiography can image ocular blood cell flow and could thus provide novel insights in disease mechanisms of CSC. We evaluated depth resolved flow in chronic CSC by OCT angiography compared to fluorescein angiography (FA) and indocyanine green angiography (ICGA).

Method:

Eighteen eyes with chronic CSC, and 6 healthy controls, were included. Two human observers annotated areas of staining, hypofluorescence and hot spots on FA and ICGA, and areas of abnormal flow on OCT angiography. Inter-observer agreement in annotating OCT angiography and FA/ICGA was measured by Jaccard indices (JIs). We assessed co-location of flow abnormalities and subretinal fluid visible on OCT, and the distance between hot spots on ICGA from flow abnormalities.

Results:

Abnormal areas were most frequently annotated in late-phase ICGA and choriocapillary OCT angiography, with moderately high (median JI, 0.74) and moderate (median JI, 0.52) inter-observer agreement, respectively. Abnormalities on late-phase ICGA and FA co-located with those on OCT angiography. Aberrant choriocapillary OCT angiography presented as foci of reduced flow surrounded by hyperperfused areas. Hot spots on ICGA were located near hypoperfused spots on OCT angiography (mean distance, 168 μm). Areas with current or former subretinal fluid were co-located with flow abnormalities.

Conclusions:

On OCT angiography, chronic CSC showed irregular choriocapillary flow patterns, corresponding to ICGA abnormalities. These results suggest focal choriocapillary ischemia with surrounding hyperperfusion that may lead to subretinal fluid leakage.

Introduction

Central serous chorioretinopathy (CSC) is characterized by a serous retinal detachment, sometimes accompanied by a detachment of the retinal pigment epithelium (RPE).^{1,4} The leakage of fluid through the RPE often occurs at the macula, resulting in central vision loss, disturbed color vision, (para-) central scotoma, metamorphopsia and/or micropsia.^{2, 4-6} Patients with CSC are typically male (male/female ratio 6:1), with an average age of 45 to 51 years.^{1, 3} Besides the male gender, the most consistent risk factor appears to be the use of corticosteroids, as well as circumstances where corticosteroid levels are increased, such as Cushing disease and pregnancy. In addition, a type A personality and certain genetic factors may increase the risk for CSC.^{1, 7, 8} Although the precise pathophysiological mechanism is still unclear, multimodal imaging indicates that subretinal fluid (SRF) accumulation in CSC results from a thickened, congested, hyperpermeable choroid leaking fluid through a dysfunctional RPE.⁹⁻¹²

Two main forms of CSC can be distinguished: the acute and chronic form.^{1, 3, 4, 11} Patients with acute CSC usually present with sudden and marked central vision loss, caused by SRF leakage at the macula due to a focal leak in the RPE that is visible on fluorescein angiography (FA).^{1, 2, 13} The prognosis is favorable in this type and spontaneous recovery is often seen within 2-3 months.¹ In contrast to acute CSC, chronic CSC is typically not self-limiting and SRF persists for more than 3 months. Patients with chronic CSC have more diffuse multifocal leakage on FA and indocyanine green angiography (ICGA), as well as irregularly distributed widespread RPE changes associated with various degrees of low-grade, more distinct leakage on angiography: diffuse retinal pigment epitheliopathy (DRPE). Such persistent serous neuroretinal detachments may cause progressive and irreversible photoreceptor damage, resulting in a far worse visual prognosis of chronic CSC as compared to the acute form.^{2, 14, 15}

Previous studies have examined blood flow in CSC by use of FA/ICGA imaging, and observed choriocapillary congestion.¹⁰ In an ultrastructural study of a cynomolgus monkey model of CSC, damage of choriocapillary endothelial cells underneath damaged RPE cells that were covered by fibrin platelet clots was observed, which led to the suggestion that choriocapillary hyperpermeability occurs in CSC.^{16, 17} Blood flow in CSC has also been examined using other optical imaging modalities. For instance, choroidal hypoperfusion was demonstrated with laser Doppler flowmetry.¹⁸

Spectral-domain optical coherence tomography (SD-OCT) is a noninvasive, high-speed, high-resolution, three dimensional imaging technique frequently applied in patients with CSC to evaluate SRF and photoreceptor damage.¹⁹ SD-OCT may also be used to perform angiography in a non-invasive manner. Split-spectrum amplitude decorrelation angiography (SSADA) is a clinically feasible, commercialized technique which can visualize capillary

blood flow, but without determination of the flow direction.²⁰ In contrast to dye assisted FA and ICGA imaging, OCT angiography detects movements of blood cells, instead of serum extravasation or staining of vessel walls and tissue. SSADA has been used recently in the examination of abnormal vascular structures in macular telangiectasia type 2,²¹ and of choroidal neovascularization in age-related macular degeneration,^{22, 23} as well as chronic CSC.²⁴ Hence, OCT angiography could provide additional information on the blood supply in CSC, and it could therefore help to better understand the underlying pathophysiology of the disease. In our current study we compared OCT angiography in chronic CSC to established angiographic imaging modalities like FA and ICGA.

Methods

We studied 18 eyes of 11 consecutive patients (6 male, 5 female) with chronic CSC seen at the outpatient clinic of the Department of Ophthalmology of the Radboud University Medical Center (Nijmegen, the Netherlands) from November, 2014 to January 2015. All study participants gave oral informed consent for OCT based angiography imaging. In addition, 6 healthy volunteers (3 male, 3 female) with no medical history of ocular or cardiovascular diseases and/or diabetes mellitus served as controls. Ethical approval for retrospective analysis of this observational case series was granted by the institutional review board at the Radboud University Medical Center and the study adhered to the tenets of the Declaration of Helsinki. The diagnosis of chronic CSC was based on a history with persistent fluid of at least 3 months, as well as RPE damage due to longstanding SRF. Active chronic CSC was defined by active leakage of fluid under the neuroretina confirmed by SD-OCT and by hyperfluorescent spots on ICGA and/or at least one ill-defined leakage spot on FA. Patients were included if OCT angiography, FA and ICGA were performed on the same day to maximize the comparability of the angiographic techniques. Patients with other ocular disorders commonly associated with serous SRF, such as choroidal neovascularization, polypoidal choroidal vasculopathy, diabetic retinopathy, retinal vascular occlusion, and myopia > 6 diopters were not eligible.

For SD-OCT, fundus autofluorescence (AF), FA and ICGA imaging, we used the Spectralis™ HRA+OCT device (Heidelberg Engineering, Heidelberg, Germany). Simultaneous FA and ICGA imaging were performed after patients were given a 2.5 ml intravenous injection of 25% fluorescein solution mixed with 12.5 mg indocyanine green (ICG-Pulsion® 25 mg). FA and accompanying ICGA images were selected from the early phase (30 to 60 seconds post-injection) and the late phase (6 to 8 minutes post-injection) of the dye transit. Following ICGA/FA imaging, the presence of sub-macular fluid deposits was evaluated based on SD-OCT.

OCT Angiography

We used a newly developed SD-OCT device (Optovue RTVue XR Avanti™ AngioVue™, Optovue Inc, Fremont, CA) to obtain SSADA images. This instrument has an A-scan rate of 70 kHz and an axial resolution in tissue of 5 µm, using a light source with a center wavelength of 840 nm and a spectral bandwidth of 45 nm. Two consecutive B-scans (M-B frames) of 304 A-scans each along the fast scanning axis were recorded at each of the 304 positions along the slow scanning axis. According to this protocol, horizontal priority fast transverse (x-fast) scans and vertical priority fast transverse (y-fast) scans were obtained consecutively to record a 3-dimensional data cube. The M-B frames were analyzed for highly decorrelated pixels, which are co-located with moving blood cells in retinal and choroidal vessels. These data were used to reconstruct three-dimensional blood flow images as described previously.²⁰ Scans with insufficient quality due to blinking (appearing as straight, black

stripes), or fixation loss were excluded. After selecting the best scans, residual axial and saccadic motion artifacts were corrected using the contained software (ReVue™, Optovue Inc.). OCT angiography images of four vascular layers (inner vascular plexus, deep retinal vascular plexus, outer retina, and choriocapillaris), and a full thickness OCT angiogram including all retinal layers and the choriocapillaris, were then exported. Examples of these images in a healthy control subject and a patient with chronic CSC are depicted in **Figure 1**.

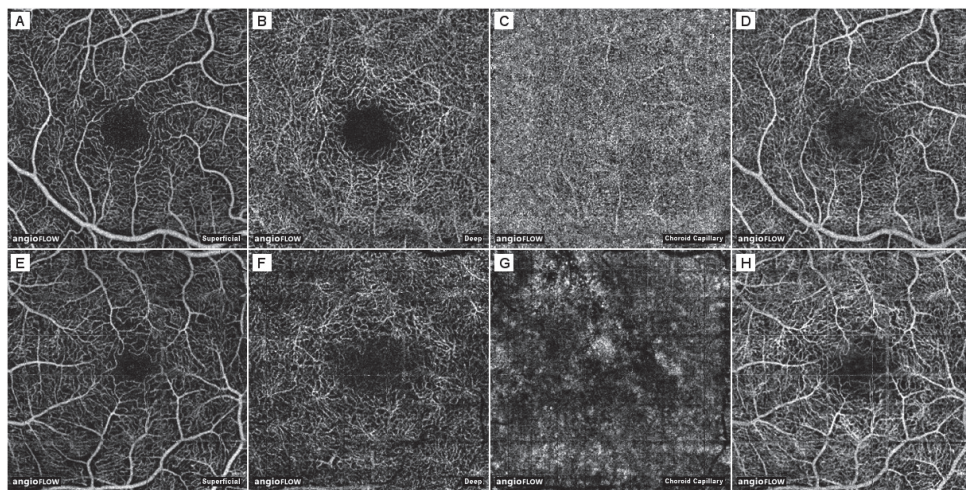


Figure 1.

OCT angiography of a healthy subject and of a patient with chronic CSC. **A-D**, Right eye of a healthy 25 year-old female, **E-H**, Left eye of a patient with chronic CSC (patient 4, see Table 1). **A** and **E**, The inner vascular plexus ('Superficial'). **B** and **F**, The deep retinal vascular plexus ('Deep'). **C** and **G**, Choriocapillaris ('Choroid cap'). The choriocapillaris was defined as a 20 μm band below the RPE-Bruch's membrane complex. It was segmented by the ReVue software and, if needed, corrected for significant segmentation errors. **D** and **H**, Full-thickness OCT angiogram. Outer retina not shown.

Image Readings and Annotations

OCT angiography images and FA/ ICGA images were aligned using a semi-automatic registration tool, developed in MeVisLab (version 2.5a, MeVis Medical Solutions AG, Bremen, Germany), that translates, rotates, and rescales the target image to accurately match three user specified landmark locations on both the source (FA) and target (OCT angiography of the superficial layer) images.²⁵ The same transformation matrix was applied to ICGA images for co-registration.

All image readings were performed at NANOREAD (Nijmegen Angio OCT Reading Center) by experienced and masked observers, and were done separately on the same computer. Each observer (M.B., T.T.) annotated areas showing leakage and hypofluorescence in the FA and ICGA images and regions in the OCT angiography images with visually evident deviations from the normal appearance. In **Figure 2**, the image registration and annotation processes are depicted in a flow chart together with illustrative examples. A representative example of registered images is shown in **Figure 3**. OCT angiography images of five healthy volunteers, who were not part of the study, served as a reference. Images of patients and controls were anonymized and randomized, by replacing filenames with unique random numbers and subsequent sequential rearrangement according to consecutive numbering. The region-of-interest (ROI) function of ImageJ (version 1.46r, National Institutes of Health, Bethesda, MD) was used for annotation purposes.




Figure 2.

Flow chart of the image registration and annotation procedures. Original images, i.e. superficial retinal OCT angiography and FA images, were registered by an observer, using a variety of image overlay options (Step 1). Simultaneously acquired ICGA images were transformed identically to the FA image (Step 2). The final display image, with a standard layout, was then created, which included the original FA/ICGA image containing contextual information (Step 3). Annotations were made by human observers (Step 4), after which the overlap of annotations was calculated by Jaccard's index (Step 5). See text for details.

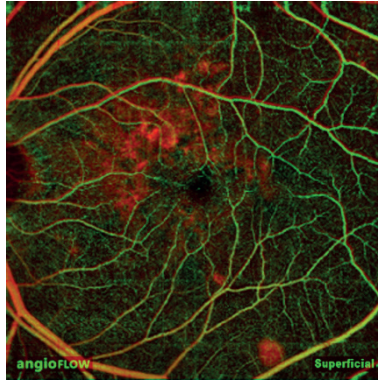


Figure 3.

Example of image registration. Overlay of an early-phase FA image (red) registered to a superficial OCT angiography image (green), with overlapping vessels indicated in yellow.

Image Analysis

To determine the inter-observer agreement of image annotations, the number of images annotated by both observers was determined. In case both observers annotated the image, we calculated the spatial overlap of the annotations by the Jaccard index (JI) as:

$$JI(R_1, R_2) = \frac{R_1 \text{ pixels} \cap R_2 \text{ pixels}}{R_1 \text{ pixels} \cup R_2 \text{ pixels}}$$

Indices were calculated separately for each observer's set of annotations, and were then pooled together. The spatial correspondence of abnormalities visible in OCT angiography images with FA/ICGA was firstly determined by the frequency of annotations on both modalities. In those cases, we calculated JIs to determine the extent of their overlap. We tested if the overlap of each combination of OCT angiography images and FA/ICGA images was different from all other combinations with the Mann-Whitney *U*-test. We also tested if this overlap, in terms of JIs, was correlated between both eyes of a patient. P-values < 0.05 were considered statistically significant.

Image analysis was performed to determine the correspondence between hot spots or profound hypofluorescence in late-phase ICGA images, and focal areas of decreased flow in the choriocapillary lamina on OCT angiography images, in terms of the distance between their centers. These centers were determined by the center of mass of the annotated areas. In case adjacent foci appeared confluent on ICGA images, they were often amalgamated in

a single ROI as 'beads on a string'. A watershed algorithm was applied to split these ROI's to facilitate the distinction of different foci. Subsequently, the shortest distances between leakage hot spots or hypofluorescent foci in ICGA images and dark spots in OCT angiography images with a visually evident correspondence were calculated (**Figure 4**).




Figure 4.

Annotation and quantitative analysis of hyperfluorescent areas on ICGA and aberrant flow on OCT angiography. Left image, late-phase ICGA image of a patient with chronic CSC with location of the registered image (yellow frame). Middle image, detail of abnormalities in the registered ICGA image. Right image, the aberrant flow pattern on OCT angiography of the choriocapillaris is co-located with the annotated region on late-phase ICGA; the darkest region corresponds with a hypofluorescent spot on ICGA, bordered by increased flow co-located to the leakage hot spot and late staining. The annotated region is depicted by the yellow line.

Fundus autofluorescence

To determine whether the results of OCT angiography of the choriocapillaris were affected by light-absorbing chromophores of the RPE, we compared OCT angiography images to AF images that were recorded on the same day. AF images were registered to OCT angiography images as described earlier. We considered OCT angiography signals above or below the mean \pm 2 standard deviations of apparently uninvolved areas, respectively, as abnormal choriocapillary flow. Uninvolved areas were determined by a lack of annotations, absence of large vessel shadows, and in the near vicinity of the image border, as irregular flow at the image borders was common even in healthy subjects. Thresholded pixels of increased or decreased flow were overlaid on the registered AF images. Finally, two observers (M.T., T.T.) evaluated whether there was any co-location of focally changed AF signals and choriocapillary flow.

Results

Patient demographics are depicted in **Table 1**.

Table 1. Clinical characteristics of the patients included in this study

ID/Gender /Age, y	Eye(s) Included	Signs of Chronic CSC on FA, ICGA and OCT	Active Chronic CSC on FA, ICGA and OCT	Previous Treatment(s)
P1/F/55	OD	yes	yes	1 x MP
P2/M/58	OD	yes	yes	NA
P3/F/64	OD	yes	yes	NA
	OS	yes	yes	NA
P4/M/40	OD	yes	no	NA
	OS	yes	yes	NA
P5/M/71	OD	yes	no	2 x PDT
P6/F/56	OD	yes	yes	NA
P7/F/38	OD	yes	no	NA
	OS	yes	yes	1 x PDT
P8/F/56	OD	yes	no	1 x MP
	OS	yes	yes	NA
P9/M/59	OD	yes	yes	2 x MP, 1 x PDT
	OS	no	no	NA
P10/M/62	OD	no	no	NA
	OS	yes	yes	NA
P11/M/47	OD	yes	yes	NA
	OS	yes	no	2 x MP, 1 x PDT

CSC: central serous chorioretinopathy; FA: fluorescein Angiography; F: female; ICGA: indocyanine green angiography; M: male; MP: micropulse laser therapy; NA: not applicable; OCT: optical coherence tomography; OD: right eye; OS: left eye; PDT: half-dose photodynamic therapy.

Inter-observer Agreement

A total of 255 images were analyzed, including 100 FA and ICGA-images of patients, and 125 and 30 OCT angiography images of patients and healthy subjects, respectively. In 132 images (52%), abnormalities were annotated by both observers (83 FA/ICGA images and 49 OCT angiography images). An example of image annotations by both observers is shown in **Figure 5**. The corresponding JIs as indicators of inter-observer agreement and numbers of annotated images are summarized in Table 2. FA and ICGA images were annotated with moderate agreement (median JIs, 0.43-0.67). Of the various OCT angiography images, choriocapillary flow images were most frequently annotated by both observers (80% of the patient images, 17% of the control images) with moderate inter-observer agreement (median JI, 0.52). OCT angiography images of retinal layers were annotated less often than choriocapillary flow images. The inter-observer agreement in annotating abnormal

choriocapillary flow was similar to FA and ICGA, both in terms of the frequency of annotations and the agreement scores.

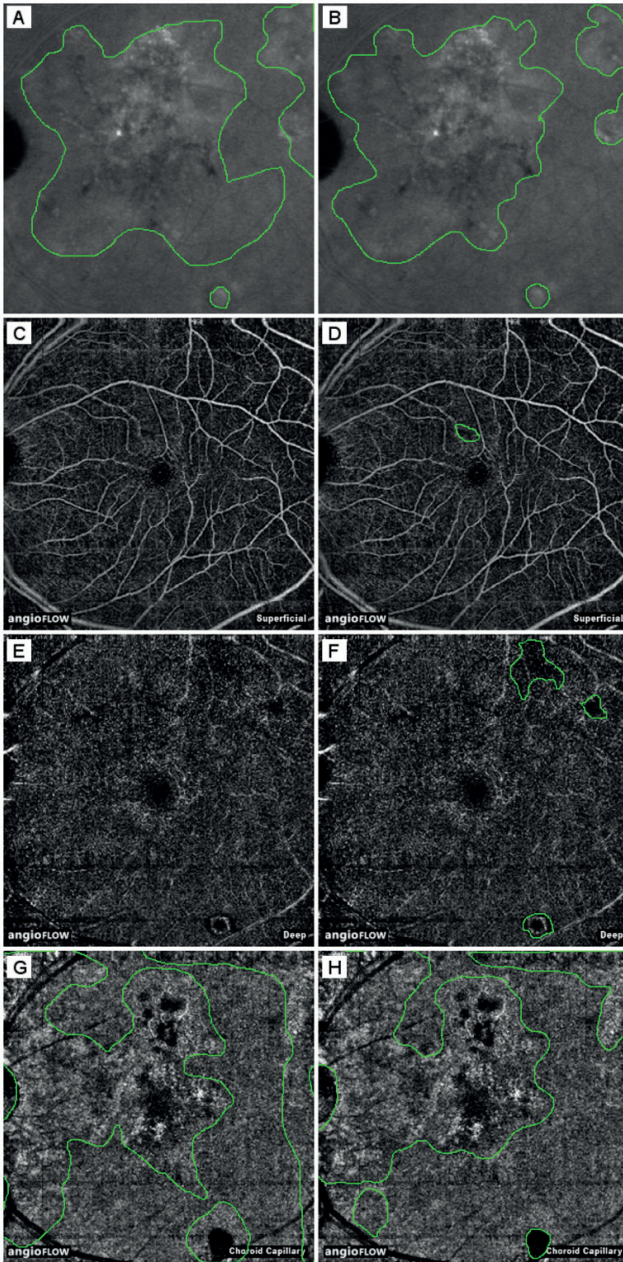


Figure 5.

Examples of image annotations. **A** and **B**, late-phase ICGA images (left eye of patient 8, 6x6 mm). **C** and **D**, superficial OCT angiography images. **E** and **F**, deep OCT angiography images. **G** and **H**, choriocapillary OCT angiography images. Left column, annotations by observer 1; right column, annotations by observer 2. The Jaccard indices (JIs) of overlap between late-phase ICGA and superficial- and deep- OCT angiography were 0.006 and 0.022, respectively (observer 2). The JIs of overlap of late-phase ICGA with choriocapillary OCT angiography were 0.43 and 0.55 for observers 1 and 2, respectively.

Table 2. Inter-observer agreement of annotated vascular abnormalities in FA, ICGA and OCT angiography images

	JI		Annotations Made by Observers		
	Mean (SD)	Median	Both	Either	None
FA/ICGA					
FA (early phase)	0.46 (0.29)	0.35	19	1	5
FA (late phase)	0.59 (0.23)	0.58	20	2	3
ICGA (early phase)	0.43 (0.29)	0.47	22	1	2
ICGA (late phase)	0.67 (0.15)	0.74	22	2	1
OCT Angiography					
Superficial	0.28 (0.22)	0.28	4	9	18
Deep	0.27 (0.19)	0.26	11	10	10
Outer retina	0.47 (0.17)	0.40	7	16	8
Choroid cap	0.49 (0.22)	0.52	21	5	5
FT-OCTA	0.5 (0.2)	0.53	6	11	14

JI: Jaccard index; FA: fluorescein angiography; ICGA: indocyanine green angiography; FT-OCTA: full thickness OCT angiogram; OCT: optical coherence tomography; SD: standard deviation.

General Correspondence between OCT Angiography and FA/ICGA

Table 3 summarizes the overlap of annotated abnormal areas observed with various angiographic imaging modalities expressed in JIs. Choriocapillary flow images and late-phase FA/ICGA images corresponded best in determining abnormality with moderately low overlap of the annotated areas (median JI of both FA and ICGA vs. choriocapillary, 0.41). In general, there was a poor overlap between annotated changes on FA and OCT angiography images, with median JIs ranging from 0 to 0.05. The correspondence between aberrant choriocapillary flow and abnormalities on late-phase FA/ICGA was higher than the correspondence of abnormalities in early or late FA images and abnormalities in retinal OCT angiography images ($p < 0.001$). In general, the JIs showed a significant correlation between both eyes (Spearman's $\rho = 0.59$, $p = 4.5 \cdot 10^{-7}$).

The annotated choriocapillary flow patterns had a highly variable appearance. In some cases, we observed mottled flow patterns with patches of increased and decreased flow. Mostly, however, we observed irregular patterns with large and semi-confluent patches of decreased flow adjacent to similar patches with increased flow. A small number of patches with decreased choriocapillary flow corresponded with RPE-detachments visible on SD-OCT. Several other patches corresponded with focal areas of a thickened RPE below a SRF pocket, which appeared to produce shadow artifacts on late phase ICGA. In general, light-absorbing fluorophores in the RPE, as visualized by AF imaging, had no apparent correspondence with the appearance of choriocapillary flow on OCT angiography of CSC. A few sporadic

hyper-AF areas corresponded with decreased flow areas, although not all hyper-AF in the same images corresponded with decreased flow and vice-versa. The same was true for the correspondence between hypo-AF and increased flow, and for other combinations. Areas of aberrant choriocapillary flow were generally co-located with locations of current SRF accumulation visible on SD-OCT, or with locations where SRF had resolved. The aberrant flow patterns appeared similarly heterogeneous in treatment naive patients and treated subjects, with no consistent differences in eyes that received micropulse laser treatment or photodynamic therapy.

Correspondence between Hot Spots on ICGA and Aberrant Choriocapillary Flow

We also studied the relationship between decreased choriocapillary flow and hot spots or hypofluorescence on ICGA (**Figure 4**). In most areas with decreased flow on OCT angiography we were unable to observe a corresponding, well-defined focus of abnormal fluorescence on late phase ICGA (75 out of 117 areas, or 64.1%). The remaining areas with decreased flow, however, overlapped largely with hypofluorescent areas on ICGA. Twelve (29.3%) out of 41 leakage areas and hot spots on late phase ICGA appeared to be connected with areas of decreased choriocapillary flow on OCT angiography, versus 24 (42.9%) out of 56 hypofluorescent spots on late phase ICGA. The mean distance between hot spots on ICGA and matched areas with decreased signal in choriocapillary flow images on OCT angiography was 168 μm (SD, 133 μm), or 17 pixels. The mean distance of hypofluorescent spots was 133 μm (SD, 70 μm), or 13 pixels. Areas of increased flow, however, were often found adjacent to leakage hot spots on ICGA. For choriocapillary flow images and corresponding FA/ICGA and AF images of all included patients and controls.

Table 3. Overlap of image annotations on FA/ICGA and OCT angiography in 11 patients with chronic CSC

FA/ ICGA	OCT Angiography	Mean JI (SD)	Median
FA (early phase)	Superficial	0.04 (0.1)	0
	Deep	0.06 (0.1)	0.01
	Choroid cap	0.25 (0.21)	0.22
	FT-OCTA	0.1 (0.19)	0
FA (late phase)	Superficial	0.03 (0.06)	0
	Deep	0.09 (0.14)	0.02
	Choroid cap	0.38 (0.22)	0.41
	FT-OCTA	0.11 (0.15)	0.05
ICGA (early phase)	Superficial	0.12 (0.2)	0
	Deep	0.09 (0.12)	0.04
	Choroid cap	0.27 (0.18)	0.24
	FT-OCTA	0.1 (0.15)	0.05
ICGA (late phase)	Superficial	0.04 (0.06)	0
	Deep	0.08 (0.11)	0.05
	Choroid cap	0.41 (0.19)	0.41
	FT-OCTA	0.14 (0.2)	0.05

Choroid cap: choriocapillaris; CSC: central serous chorioretinopathy; JI: Jaccard index; FA: fluorescein angiography; ICGA: indocyanine green angiography; FT-OCTA: full thickness OCT angiogram; OCT: optical coherence tomography; SD: standard deviation.

Discussion

In this study, we compared OCT angiography characteristics of patients with chronic CSC to FA and ICGA findings. We found typical changes in the choriocapillary flow pattern of chronic CSC patients, which corresponded to areas affected by subretinal fluid accumulation. There was moderate inter-observer agreement on changes in choriocapillary flow images of CSC patients, and there was moderate spatial correspondence between late FA/ICGA and choriocapillary flow images.

Kitaya et al. (2003) used laser Doppler flowmetry to show that eyes with CSC had reduced choroidal blood flow relative to the unaffected fellow eye.¹⁸ Using combined FA/ICGA imaging, Scheider et al. (1993) also confirmed the reduction in choroidal blood flow in CSC and demonstrated that the hypoperfusion persisted after clinical improvement.²⁶ In our study, changes of the choriocapillary flow pattern on OCT angiography appeared as focally increased and decreased pixel values, indicating coexisting increased and decreased flow, respectively. Even though, the appearance of these changes was significantly different from the fairly homogeneous appearance of the healthy choriocapillary layer, there was only a moderate inter-observer agreement. Obviously, the border between the appearance of healthy and affected tissue in OCT angiography may not easily be drawn between observers. This phenomenon has been observed earlier in a study that evaluated the agreement among highly experienced retinal specialists in grading of FA images for the presence of active choroidal neovascularization.²⁷ A multimodal approach in angiographic techniques may help to improve the identification of pathological changes. One has to keep in mind, however, that OCT angiography measures blood flow dependent on intravascular cell movements, while FA/ICGA images the flow of blood plasma, independent of cell movement. Therefore, these three techniques give blood flow information that is supplementary to each other.

On OCT angiography, we observed choriocapillary hypoperfusion with hyperperfusion in the surrounding area. This is consistent with results of earlier studies, showing focal filling defects in the choriocapillaris with dilated and tortuous feeding arterioles and dilated venules.^{10, 28-30} These filling defects may be caused by capillary congestion and/or rarefaction.¹⁰ Areas of irregular choriocapillary texture on OCT angiography partially co-located to areas with late staining on ICGA. Also, many hot spots on late-phase ICGA, if present, were in close proximity of relative ischemia on OCT angiography within those areas of irregular texture. Taken together, these data suggest that reduced blood perfusion in the choriocapillaris may be surrounded by reactive hyperperfusion. Hyperperfusion leads to increased hydrostatic pressure within the fenestrated choriocapillaris. Together with chronic hypoxic damage, this may lead to disintegrity of the continuity of the RPE,³¹ and to subretinal fluid leakage with serous neuroretinal detachment in chronic CSC.^{32, 33}

According to our data, the abnormal vascular situation in the choriocapillary layer appeared to persist even after resolution of SRF and seemed to be independent of any kind of treatment. It is still unclear, why different treatment modalities may lead to successful fluid resorption. The mechanism of action of photodynamic therapy has been postulated to include short-term choriocapillary hypoperfusion and long-term choroidal vascular remodeling with subsequent reduction of vascular hyperpermeability and leakage.^{19, 34, 35} On the short term, the hypoperfusion may lead to more ischemic RPE damage. Because of the long time period between photodynamic therapy and our study measurements, we may have missed any therapeutic effects visible on OCT angiography. It may be useful to prospectively follow patients after photodynamic therapy by OCT angiography to learn more about the therapeutic mechanism of this treatment. Subthreshold micropulse diode laser treatment is applied in an attempt to trigger the regeneration of the RPE and a long-term metabolic increase at the chorioretinal junction,³⁶ which may increase SRF resorption by the RPE.³⁷ Micropulse laser treatment is not thought to affect the choriocapillaris directly. The lack of effects on choriocapillary flow in patients after micropulse laser treatment is therefore not surprising.

Our study is mainly limited by the small number of patients and the retrospective and cross-sectional data acquisition. As a consequence, we have studied a combination of treatment-naive patients and patients who were previously treated by micropulse laser or photodynamic therapy once or multiple times. We do not have pre-treatment data and we did not monitor patients over time. To further improve our knowledge of the vascular changes in chronic CSC, prospective and longitudinal studies are required to monitor vascular changes during the natural course and during different treatment strategies. Although we found no consistent effects of chromophores in the RPE on the appearance of choriocapillary flow, save for a few sporadic cases, a comprehensive analysis of potential confounders on the appearance of OCT angiography signals was out of the scope of this study. This is important in OCT angiography studies of retinal diseases in which layers with high light-absorption are affected. Therefore, future studies should include SD-OCT and AF imaging to determine potential imaging artifacts. The fields of view on OCT angiography were of considerably smaller size than those currently used in ICGA or SD-OCT. Peripheral areas with obvious FA/ICGA irregularities were therefore missed. Future studies should aim to include the complete posterior pole with all angiographic abnormalities by OCT angiography scanning. This could be achieved by a montage of many high-resolution OCT angiography scans or by improved OCT hardware-software combinations capable to visualize larger fundus areas with high resolution.

In conclusion, OCT angiography showed significant textural changes of the choriocapillary flow pattern in chronic CSC patients. Our results suggest foci of ischemia surrounded by reactive choroidal hyperperfusion as an important factor in the pathogenesis of chronic CSC. Prospective OCT angiography studies on chronic CSC are needed to better understand the pathogenesis and treatment response of this visually threatening disease.

References

1. Liew G, Quin G, Gillies M, Fraser-Bell S. Central serous chorioretinopathy: a review of epidemiology and pathophysiology. *Clin Exp Ophthalmol* 2013;41:201-214.
2. Wang M, Munch IC, Hasler PW, Prunte C, Larsen M. Central serous chorioretinopathy. *Acta Ophthalmol* 2008;86:126-145.
3. Nicholson B, Noble J, Forooghian F, Meyerle C. Central serous chorioretinopathy: update on pathophysiology and treatment. *Surv Ophthalmol* 2013;58:103-126.
4. Gemenetzi M, De Salvo G, Lotery AJ. Central serous chorioretinopathy: an update on pathogenesis and treatment. *Eye (Lond)* 2010;24:1743-1756.
5. Yannuzzi LA. Central serous chorioretinopathy: a personal perspective. *Am J Ophthalmol* 2010;149:361-363.
6. Maaranen TH, Tuppurainen KT, Mantyjarvi MI. Color vision defects after central serous chorioretinopathy. *Retina* 2000;20:633-637.
7. de Jong EK, Breukink MB, Schellevis RL, et al. Chronic central serous chorioretinopathy is associated with genetic variants implicated in age-related macular degeneration. *Ophthalmology* 2015;122:562-570.
8. Miki A, Kondo N, Yanagisawa S, Bessho H, Honda S, Negi A. Common variants in the complement factor H gene confer genetic susceptibility to central serous chorioretinopathy. *Ophthalmology* 2014;121:1067-1072.
9. Gass JD. Pathogenesis of disciform detachment of the neuroepithelium. *Am J Ophthalmol* 1967;63:Suppl:1-139.
10. Prunte C, Flammer J. Choroidal capillary and venous congestion in central serous chorioretinopathy. *Am J Ophthalmol* 1996;121:26-34.
11. Spaide RF, Hall L, Haas A, et al. Indocyanine green videoangiography of older patients with central serous chorioretinopathy. *Retina* 1996;16:203-213.
12. Guyer DR, Yannuzzi LA, Slakter JS, Sorenson JA, Ho A, Orlock D. Digital indocyanine green videoangiography of central serous chorioretinopathy. *Arch Ophthalmol* 1994;112:1057-1062.
13. Eandi CM, Ober M, Iranmanesh R, Peiretti E, Yannuzzi LA. Acute central serous chorioretinopathy and fundus autofluorescence. *Retina* 2005;25:989-993.
14. Loo RH, Scott IU, Flynn HW, Jr, et al. Factors associated with reduced visual acuity during long-term follow-up of patients with idiopathic central serous chorioretinopathy. *Retina* 2002;22:19-24.
15. Wang MS, Sander B, Larsen M. Retinal atrophy in idiopathic central serous chorioretinopathy. *Am J Ophthalmol* 2002;133:787-793.
16. Yoshioka H, Katsume Y, Akune H. Experimental central serous chorioretinopathy in monkey eyes: fluorescein angiographic findings. *Ophthalmologica* 1982;185:168-178.
17. Yoshioka H, Katsume Y. Experimental central serous chorioretinopathy. III: ultrastructural findings. *Jpn J Ophthalmol* 1982;26:397-409.

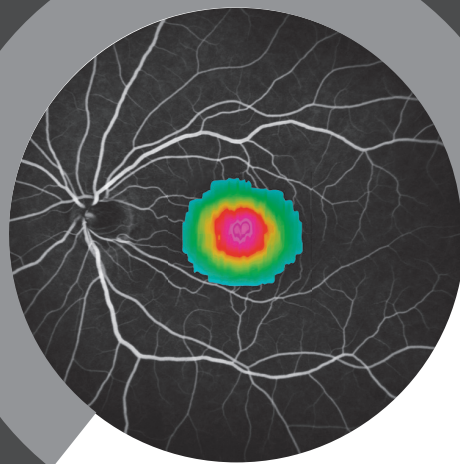
18. Kitaya N, Nagaoka T, Hikichi T, et al. Features of abnormal choroidal circulation in central serous chorioretinopathy. *Br J Ophthalmol* 2003;87:709-712.
19. Liegl R, Ulbig MW. Central serous chorioretinopathy. *Ophthalmologica* 2014;232:65-76.
20. Jia Y, Tan O, Tokayer J, et al. Split-spectrum amplitude-decorrelation angiography with optical coherence tomography. *Opt Express* 2012;20:4710-4725.
21. Spaide RF, Klancnik JM, Jr., Cooney MJ. Retinal vascular layers in macular telangiectasia type 2 imaged by optical coherence tomographic angiography. *JAMA Ophthalmology* 2015;133:66-73.
22. Jia Y, Bailey ST, Wilson DJ, et al. Quantitative optical coherence tomography angiography of choroidal neovascularization in age-related macular degeneration. *Ophthalmology* 2014;121:1435-1444.
23. de Carlo TE, Bonini Filho MA, Chin AT, et al. Spectral-domain optical coherence tomography angiography of choroidal neovascularization. *Ophthalmology* 2015;122:1228-1238.
24. Bonini Filho MA, de Carlo TE, Ferrara D, et al. Association of choroidal neovascularization and central serous chorioretinopathy with optical coherence tomography angiography. *JAMA Ophthalmology* 2015; doi: 10.1001/jamaophthalmol.2015.1320. [Epub ahead of print].
25. van Grinsven MJ, Buitendijk GH, Brussee C, et al. Automatic identification of reticular pseudodrusen using multimodal retinal image analysis. *Invest Ophthalmol Vis Sci* 2015;56:633-639.
26. Scheider A, Nasemann JE, Lund OE. Fluorescein and indocyanine green angiographies of central serous choroidopathy by scanning laser ophthalmoscopy. *Am J Ophthalmol* 1993;115:50-56.
27. Holz FG, Jorzik J, Schutt F, Flach U, Unnebrink K. Agreement among ophthalmologists in evaluating fluorescein angiograms in patients with neovascular age-related macular degeneration for photodynamic therapy eligibility (FLAP-study). *Ophthalmology* 2003;110:400-405.
28. Nishiyama Y, Mori K, Murayama K, Yoneya S. Quantitative analysis of indocyanine green angiographic image in central serous chorioretinopathy. *Jpn J Ophthalmol* 2001;45:116.
29. Iida T, Kishi S, Hagimura N, Shimizu K. Persistent and bilateral choroidal vascular abnormalities in central serous chorioretinopathy. *Retina* 1999;19:508-512.
30. Ferrara D, Mohler KJ, Waheed N, et al. En face enhanced-depth swept-source optical coherence tomography features of chronic central serous chorioretinopathy. *Ophthalmology* 2014;121:719-726.
31. Uyama M, Matsunaga H, Matsubara T, Fukushima I, Takahashi K, Nishimura T. Indocyanine green angiography and pathophysiology of multifocal posterior pigment epitheliopathy. *Retina* 1999;19:12-21.
32. Hussain D, Gass JD. Idiopathic central serous chorioretinopathy. *Indian J Ophthalmol* 1998;46:131-137.
33. Slakter JS, Yannuzzi LA, Guyer DR, Sorenson JA, Orlock DA. Indocyanine-green angiography. *Curr Opin Ophthalmol* 1995;6:25-32.
34. Karakus SH, Basarir B, Pinarci EY, Kirandi EU, Demirok A. Long-term results of half-dose photodynamic therapy for chronic central serous chorioretinopathy with contrast sensitivity changes. *Eye (Lond)* 2013;27:612-620.

35. Koytak A, Erol K, Coskun E, Asik N, Ozturk H, Ozerturk Y. Fluorescein angiography-guided photodynamic therapy with half-dose verteporfin for chronic central serous chorioretinopathy. *Retina* 2010;30:1698-1703.
36. Brinkmann R, Schule G, Neumann J, et al. [Selective retina therapy: methods, technique, and online dosimetry]. *Ophthalmologe* 2006;103:839-849.
37. Klatt C, Saeger M, Oppermann T, et al. Selective retina therapy for acute central serous chorioretinopathy. *Br J Ophthalmol* 2011;95:83-88.

CHAPTER 4

Studies on the treatment of
chronic central serous chorioretinopathy





CHAPTER 4.1

Half-dose photodynamic therapy followed by diode micropulse laser therapy as treatment for chronic central serous chorioretinopathy: evaluation of a prospective treatment protocol

Myrte B. Breukink, Jacqueline K. Mohr-Karsenberg, Annette Ossewaarde-van Norel, Anneke I. den Hollander, Jan E.E. Keunen, Carel B. Hoyng & Camiel J.F. Boon

Published in: *Acta Ophthalmology*. 2016;94(2):187-97

Purpose:

To evaluate the outcome of a prospective protocol for the treatment of chronic central serous chorioretinopathy (CSC).

Methods:

Interventional prospective case series in 59 eyes (59 patients) with active chronic CSC. All patients were first treated with indocyanine green angiography (ICGA)-guided half-dose photodynamic therapy (PDT). In case of persistent serous subretinal fluid (SRF) after a follow-up period of at least 6 weeks, ICGA-guided PDT was repeated. If the SRF persisted after 2 PDT treatments, additional ICGA-guided high-density subthreshold diode micropulse laser (HSML) therapy was performed. Clinical evaluation included best-corrected visual acuity (BCVA), funduscopy, OCT, fundus autofluorescence, fluorescein angiography and ICGA.

Results:

After a single PDT treatment, complete resolution of SRF was seen in 37 of 59 eyes. Of the 22 eyes with no complete resolution of SRF, 19 eyes received a second PDT treatment, after which 7 eyes of the 19 eyes showed a complete resolution of SRF. Ten eyes underwent HSML, of which 1 eye had complete resolution of SRF within 7 weeks. At final follow-up a complete resolution of SRF was present in 80% of all eyes. The mean BCVA improved from 0.28 logMAR at baseline to 0.16 logMAR at final follow up. Improvement of BCVA was highest after the first treatment (-0.12 logMAR, $p < 0.001$).

Conclusions:

The proposed treatment strategy using half-dose PDT and HSML in active chronic CSC resulted in an anatomical success rate of 80%. The first half-dose PDT treatment has the highest likelihood of a favorable treatment response on OCT and BCVA increase.

Introduction

Central serous chorioretinopathy (CSC) is characterized by subretinal fluid (SRF) accumulation through a dysfunctional outer blood-retinal barrier of the retinal pigment epithelium (RPE),¹⁻⁴ causing a serous detachment of the neurosensory retina. Patients with CSC are typically in the professionally active age, and men are affected more often than women.¹ Besides the male sex, several other risks factors have been described, such as the use of corticosteroids, Cushing's disease, stress, and genetic factors.^{1,5,6} More recently, we have identified genetic variants implicated in the complement system to be associated with chronic CSC,⁵ and similar findings have been described in a Japanese CSC cohort.⁶ After the first description of CSC by Von Graefe in 1866,⁷ Gass postulated that not only the RPE, but also the underlying choroid plays a pivotal role in the pathogenesis of CSC.⁸ Multimodal imaging using optical coherence tomography (OCT) and indocyanine green angiography (ICGA) has shown that dilation, congestion and hyperpermeability of the choriocapillaris and larger choroidal vessels is a prominent and possibly primary characteristic of CSC.^{9,10} However, the precise pathophysiological mechanism remains unclear.

Two main subtypes of CSC can be distinguished. Acute CSC patients present with a rapid onset of central vision loss, micropsia and metamorphopsia.²⁻⁴ Acute CSC is characterized by a focal leakage spot on fluorescein angiography (FA), often with a classic "smokestack pattern" of leakage from this small focal "hot spot", without extensive atrophic RPE changes.^{1,2,11,12} The SRF in acute CSC generally resolves spontaneously within 2-3 months with limited visual sequelae.¹ Some of these acute CSC patients can have SRF persisting for more than 3 months, and can therefore be designated as chronic CSC cases based on this time definition. However, many CSC patients without a history of acute CSC present with diffuse SRF accumulation and widespread RPE changes that indicate chronic disease.² Chronic CSC patients can have one or more hot spots of leakage on FA that are less distinct than in acute CSC cases, but widespread hyperfluorescence of an apparently more diffusely hyperpermeable RPE barrier without clear hot spots is also common in this chronic subtype of CSC.^{2-4,11} ICGA characteristically demonstrates hyperfluorescent areas of choroidal congestion and hyperpermeability that are more extensive in chronic CSC than in acute CSC. In a study by Wang and co-workers,¹³ a prolonged neurosensory detachment (> 4 months), which is often seen in chronic CSC, was shown to be associated with retinal atrophy.

Therefore, the primary goal of treatment in chronic CSC should be to achieve complete resolution of the SRF, preferably within the first 4 months after diagnosis of the disease. A broad spectrum of treatment modalities has been used in chronic CSC, such as Argon laser treatment of the leaking hot spot on FA, intravitreal injections with anti-vascular endothelial growth factor (anti-VEGF) or systemic drug treatments (e.g. spironolactone and eplerenone).^{2,14-16} Currently, photodynamic therapy (PDT) and high-density subthreshold diode micropulse laser treatment (HSML) are among the frequently reported treatment

modalities. In HSML a 810 nm diode laser is used delivering repetitive low energy pulses, selectively targeting the RPE without inducing a visible laser burn and applied as high density grid over the leaking areas.¹⁷ Several studies have shown efficacy of both PDT with verteporfin and HSML in chronic CSC.¹⁸⁻²² However, few prospective studies on the treatment of chronic CSC have been published.²²⁻²⁵ Also, it is unclear if re-treatment or a switch to other treatments in previous non-responders can be successful. In this study we evaluate a prospective treatment protocol consisting of half-dose PDT as a primary treatment in chronic CSC, followed by HSML in non-responders to 2 half-dose PDT treatments.

Material and Methods

Patients

This study represents an interventional prospective case series demonstrating a standardized treatment protocol in chronic CSC. The protocol was performed in patients with symptomatic active chronic CSC, who were treated according to the protocol between October 2011 and April 2013, at the Department of Ophthalmology of the Radboud University Medical Center, Nijmegen, the Netherlands. This study followed the guidelines of the Declaration of Helsinki and local ethics committee waived approval.

Active chronic CSC was defined by active leakage of fluid under the retina as evidenced on spectral domain (SD)-OCT and further supported by hyperfluorescent area (s) on ICGA or/and ≥ 1 ill-defined leakage area(s) on FA. Patients with active chronic CSC were considered for treatment if they had a decline in best-corrected visual acuity (BCVA) associated with subjective vision loss.

Exclusion criteria included: evidence of other disease that could explain serous SRF such as choroidal neovascularization (CNV) or polypoidal choroidal vasculopathy, myopia > 6 diopters, no hyperfluorescence on ICGA, (relative) contraindications for half-dose PDT treatment (e.g. porphyria, severely disturbed liver function), and (relative) contraindications for FA (or ICGA).

An extensive ophthalmological examination was performed in all patients including the following examinations; visual acuity (VA), SD-OCT of the retina and choroid, fundus autofluorescence, FA and ICGA (SD-OCT, FA, ICGA; Spectralis HRA+OCT; Heidelberg Engineering GmbH, Heidelberg, Germany). If active disease was confirmed by SRF on SD-OCT and characteristic leakage on FA and ICGA, ICGA-guided half-dose PDT was performed (**Figure 1**).

A control visit was scheduled preferably 6-8 weeks after treatment. Treatment response was evaluated based on the SD-OCT scan. A complete response to treatment was defined as complete absence of serous SRF on SD-OCT at the first control visit after treatment. In case of persistent SRF, a second half-dose PDT treatment was performed that was guided by a second ICGA made at the control visit 6-8 weeks after the first half-dose PDT treatment. If SRF was still present 6-8 weeks after the second half-dose PDT treatment, ICGA-guided HSML treatment was performed if there was no evidence of an alternative diagnosis such as CNV or polypoidal choroidal vasculopathy at this time point.

Interventions

We decided to use half-dose PDT treatment as the first treatment based on reported success percentages of 70-100% in the available (retrospective) literature,^{22, 25-28} as compared to 41-58% reported for HSML treatment in CSC.^{27, 29} We preferred to use half-dose PDT because this treatment strategy appears to have an outcome that is comparable with half-fluence or

half-time PDT, and because reducing the dose may decrease the likelihood of verteporfin-associated adverse reactions. Both interventions were performed in mydriasis, achieved by instillation of a drop of 1.0% tropicamide and 5% phenylephrine in each eye at 3 different moments with an interval of 10 minutes.

Half-dose photodynamic treatment

All patients received 3 mg/m² verteporfin (Visudyne[®]) (half-dose) intravenously, with an infusion time of 10 minutes. At exactly 15 minutes after the start of the infusion, a contact lens (a Volk[®] PDT lens) was positioned on the affected eye, and the aiming beam of the laser was focused on the treatment area. The magnification factor was taken into account in the settings of the half-dose PDT machine. The treatment area was chosen based on those hyperfluorescent area(s) on mid-phase ICGA that corresponded to SRF accumulation in the macula on the OCT scan and hyperfluorescent “hot spots” on the mid-phase FA, with the area of the aiming beam corresponding to the area of the subsequent laser spot area. The spot size corresponded to the diameter of the hyperfluorescent area on ICGA plus 1mm. The treatment was performed with standard 50 J/cm² fluency, a PDT laser wavelength of 689 nm, and a standard treatment duration of 83 seconds (**Figure 1**). The average spot size used in this study was 2.4 μm (range 1.3-7.2 μm; 5th percentile: 1.4 μm, median: 2.3 μm, 95th percentile: 6.6 μm).

High-density subthreshold diode micropulse laser treatment

For this intervention a contact lens (an Ocular[®] Mainster Focal/Grid laser lens) was positioned on the affected eye. HSML treatment with an 810 nm diode laser (Iridex, Mountain View, United States) was performed over the areas identified on mid-phase ICGA. Multiple confluent, adjacent (non-overlapping) laser spots were applied, covering the leakage area on mid-phase ICGA. The area to treat was determined based on those hyperfluorescent area(s) on ICGA that corresponded to SRF accumulation in the macula on the OCT scan and hyperfluorescent “hot spots” on the mid-phase FA (**Figure 1**).

The following HSML treatment settings were used: a power of ≤ 1800 mW, a duty cycle of 5%, frequency of 500 Hz, exposure time of 0.2 s per application (100 x [0.1 ms ON-time and 1.9 ms OFF-time per single pulse]), spot size: 125 μm and delivered with a high-density grid pattern of subthreshold invisible applications over the entire area of leakage, with a 500 μm minimum distance to the fovea¹⁷. To avoid suprathreshold treatment, a laser test spot of 1800 mW was first applied outside the macular area, and 3 seconds of observation of the test spot area to exclude a delayed discoloration due to a suprathreshold effect. If retinal discoloration was seen at a power of 1800 mW (corresponding to suprathreshold treatment), the power was reduced with steps of 300 mW until there was no visible reaction. This power was then used to perform the ICGA-guided HSML treatment.

Clinical evaluation

The onset of complaints, the use of steroids, previous episodes, previous treatments and recurrence of disease after first successful treatment were recorded. In addition, all available imaging data (SD-OCT, FA, ICGA, and FAF) were collected to investigate the evolution of the clinical picture on multimodal imaging.

The presence of SRF and RPE detachments within the macular area was evaluated using SD-OCT.

In all affected eyes the SD-OCT scan made before each treatment was compared to the scan after that treatment, and the SD-OCT scan of the first visit was compared to the last available scan.

The central foveal thickness (CFT), defined as the distance between the inner part of the internal limiting membrane and the outer part of the external limiting membrane at the central fovea, was measured. Also, the height of the SRF accumulation was measured from the outer part of the external limiting membrane to the outer part of the RPE layer at the central fovea, which we will refer to as the SRF accumulation. If enhanced-depth SD-OCT imaging was available, the choroidal thickness was measured from the outer part of the hyperreflective RPE layer to the hyperreflective line of the inner surface of the sclera. Information of both the study eye and the fellow eye was included. Differences in the outcome of these measurements were compared among the patients using a paired t-test.

All FA ICGA, and FAF imaging that was available was evaluated on the following aspects; the extent, intensity, and pattern of retinal and choroidal abnormalities by an experienced grader. Also, the number of hot spots was registered at baseline, and during follow-up on FA and ICGA. Changes in extent, intensity, and pattern of retinal and choroidal abnormalities on FA, ICGA, and FAF were evaluated including hot spots on FA and ICGA and focal hyperfluorescent spots on ICGA.

Visual acuity

To assess the overall effect of treatment on VA over time, the VA at first visit before treatment was compared to the VA of the first control visit after the first treatment. In addition, the VA of the first visit was compared to the VA at the final visit using an independent samples t-test, with a p-value < 0.05 considered statistically significant.

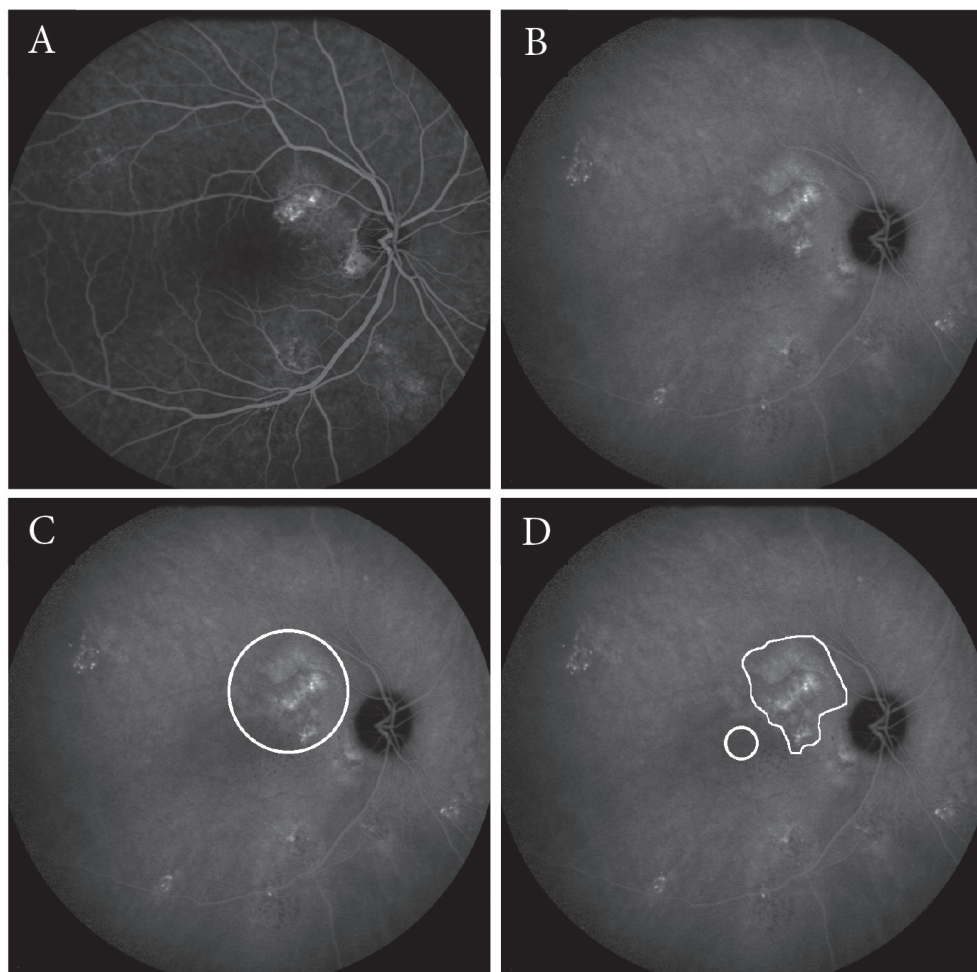


Figure 1.

Examples of imaging features on fluorescein angiography (FA) and indocyanine green angiography (ICGA) in chronic central serous chorioretinopathy (CSC), and the corresponding treatment areas for photodynamic therapy (PDT) and high-density subthreshold micropulse laser treatment (HSML). **A-B** FA of the right eye of a patient showing hyperfluorescent hot spots, indicating leakage superior of the fovea (**A**). On ICGA an area area of hyperfluorescence is seen which corresponds to the hyperfluorescent area on the FA(**B**). **C-F** An example of a PDT spot (white circle) overlapping the hyperfluorescent area on the ICGA plus 1 mm as described in the protocol (**C**). HSML treatment scheme that would apply to the same eye, in which the central foveal area is excluded for treatment (white circle). The hyperfluorescent area on ICGA is treated with numerous, non-overlapping adjacent laser spots (white area outlined superior of the fovea) (**D**).

Results

Demographics

A total of 59 eyes of 59 patients (46 male, 78%) with a mean follow-up of 39.2 weeks (range: 8 - 126 weeks) were included in this study. The mean age of the participants was 48 years (range: 30-71 years). At the moment of inclusion current use of corticosteroids was reported in 7 patients (12%), 3 patients (5%) reported the use of corticosteroids in the past, 44 patients (75%) did not report any corticosteroid use, and in 5 patients (8%) no information on corticosteroid use was available. Fifteen eyes (25%) received previous treatment partially at their referring ophthalmologist varying from HSML, Argon laser therapy, intravitreal anti-vascular endothelial growth factor (anti-VEGF) injections, and oral acetazolamide. In 2 patients these previous treatments took place 7 and 11 weeks before the first PDT treatment, respectively. In the other previously treated eyes, the previous treatment was performed more than 3 months before the first PDT treatment. Eleven patients (19%) reported one or more acute episode(s) of CSC with spontaneous resolution in the past.

In 5 patients (8%) SRF was found bilaterally at the first visit. An RPE detachment within the macular area was seen on SD-OCT in 13 of the study eyes (22%), and in 5 of the fellow eyes.

Treatment response based on presence of SRF on SD-OCT

Overall, after 1 half-dose PDT treatment 37 eyes (63%) showed complete resolution of the SRF at the first control visit (mean time 8.7 weeks, range: 4 – 18 weeks). Of these 37 eyes, 2 eyes (5%) had recurrence of SRF within the study period and received further treatment according to the protocol. On the last available SD-OCT scan the SRF remained absent in 35 eyes (95%); the 2 eyes that experienced a recurrence had persistence of SRF on SD-OCT, despite additional treatment.

An overview of the treatment results is given in figure 2 (**Figure 2**).

Of the 43 eyes (73%) that did not receive any previous treatment, 29 eyes (67%) had absence of SRF after the first half-dose PDT treatment. In the group that received previous treatments, in 7 (47%) of the 15 eyes no SRF was seen on SD-OCT after the first treatment.

At the last known visit the SRF has disappeared completely on SD-OCT in 47 eyes (80%) (mean time 39.1 weeks, range 8 – 126 weeks). In 5 of these 47 eyes (11%) SRF was still present at the control visit 6-8 weeks after the last treatment, but a spontaneous improvement occurred resulting in complete absence of SRF at the last known visit.

No significant correlations were found between the treatment response and the spot size used during half-dose PDT, the use of steroids, the presence of RPE detachments, previous treatment and the duration of complaints.

	Baseline N=59 eyes		
	Patients who received only 1 half-dose PDT treatment N=40 eyes	Patients who received a total of 2 half-dose PDT treatments N=9 eyes ¹	Patients who received 2 half-dose PDT treatments followed by 1 HSML treatment N=10 eyes ²
Control visit after the last performed intervention	Absence of SRF = 35 eyes (88%)	Absence of SRF = 7 eyes (78%)	Absence of SRF = 1 eye (10%)
Mean FU-time	8.7 weeks range 3.9 - 18.1	6.3 weeks range 5.4 - 7.3	12.0 weeks range 5.4 - 32.0
Last available control visit	Absence of SRF = 39 (98%) Persistence of SRF = 1 (2%) Recurrence = 0	Absence of SRF = 6 eyes (67%) Persistence of SRF = 2 eyes (22%) Recurrence = 1 eye (11%)	Absence of SRF = 2 eyes (20%) Persistence of SRF = 8 eyes (80%) Recurrence = 0
Mean FU-time	29.0 weeks range 8.0 - 110.1	46.0 weeks range 19.0 - 126.1	73.3 weeks range 32.9 - 118.1

¹ This group includes 1 eye that received a second half-dose PDT treatment despite a good response to the first PDT treatment (evidenced by an absence of SRF)
² This group includes 1 eye that responded well to the first half-dose PDT treatment with resolution of SRF, but then had a recurrence of SRF for which a second unsuccessful half-dose PDT treatment was performed

Figure 2.

Overview of the number of treatments per study eye and the treatment result as defined by the absence or persistent presence of subretinal fluid on optical coherence tomography FU-time; Follow-up-time, HSML; High-density subthreshold micropulse laser, PDT; Photodynamic therapy, SRF; Subretinal fluid

Clinical course

Fluorescein angiography, indocyanine green angiography, and fundus autofluorescence

FA, ICGA and FAF were compared before and after each treatment and all changes were scored (**Table 1**). The abnormalities seen on FA were compared to the changes seen on ICGA after the first half-dose PDT treatment, and an overlap between the two modalities was found in 43 eyes (73 %) (i.e. in the 33 eyes with changes on FA the ICGA also showed similar changes, and in the 13 eyes without post-treatment changes on FA also no change was seen on ICGA). Changes seen on FA after treatment mainly consisted of a decrease in hyperfluorescence, conversion of clear focal leakage into staining or more diffuse leakage, and complete disappearance of hot spots. In 20 of 30 cases (67%) with a disappearance of the hot spot and/or decrease of the hyperfluorescent area as seen on FA, the findings corresponded to a complete absence of SRF on SD-OCT. On ICGA a decrease in focal hyperfluorescent zones, that may correspond to focal vascular dilations of the choriocapillaris, was observed in 39 eyes out of 80 eyes/observations (49%) after treatment. In 74% (28 eyes) this decrease in hyperfluorescence on ICGA corresponded with a complete resolution of SRF on SD-OCT, and a decrease in SRF on SD-OCT was seen in 23% (**Figure 3**).

To compare FAF before and after treatment, accurate imaging was available in 51 eyes. The changes that were seen on FAF could mainly be explained by the absence or presence of SRF. The presence of SRF as evidenced on SD-OCT led to relative light scatter/blockage of autofluorescence. Nineteen of the 51 eyes showed a clear change on FAF imaging after treatment, and in 6 of these eyes (32%) a typical punctiform hyperautofluorescent pattern was seen in the area of previous SRF accumulation.

Table 1. Percentages of changes seen in multimodal imaging after treatment

	First treatment	Second treatment	Third treatment
FA	58 eyes <u>Change</u> ; 37 eyes (64%) <u>No change</u> ; 21 eyes (36%)	17 eyes <u>Change</u> ; 8 eyes (47%) <u>No change</u> ; 9 eyes (53%)	2 eyes <u>Change</u> ; 1 eyes (50%) <u>No change</u> ; 1 eyes(50%)
ICGA	57 eyes <u>Change</u> ; 40 eyes (70%) <u>No change</u> ; 17 eyes (33%)	18 eyes <u>Change</u> ; 8 eyes (44%) <u>No change</u> ; 10eyes (56%)	2 eyes <u>Change</u> ; 0 eyes (0%) <u>No change</u> ; 2 eyes (100%)
FAF	51 eyes <u>Change</u> ; 19 eyes (37%) <u>No change</u> ; 32 eyes (63%)	19 eyes <u>Change</u> ; 5 eyes (26%) <u>No change</u> ; 14 eyes (74%)	4 eyes <u>Change</u> ; 1 eye (25%) <u>No change</u> ; 3 eyes (75%)

FA; Fluorescein angiography, FAF; Fundus autofluorescence, ICG Angiography; indocyanine green angiography

Table 2. Changes measured on spectral domain optical coherence tomography after treatment

	Number of eyes	Mean difference	95% CI	P-value
SRF accumulation				
treatment 1	59	-125.6 μ m	-162.5 - -88.8	< 0.001
treatment 2	19	-75.7 μ m	-113.1 - -38.3	<0.001
treatment 3	10	-10.1 μ m	-55.6 – 35.4	0.627
treatment total	59	-143.0 μ m	-177.3- -108.7	<0.001
CFT				
treatment 1	59	5.4 μ m	0.1 – 10.6	0.044
treatment 2	19	-3.1 μ m	-11.1 – 4.9	0.426
treatment 3	10	4.5 μ m	-4.9 – 13.9	0.306
treatment total	59	7.3 μ m	1.3 – 13.3	0.018
EDI				
treatment 1	29	-56.2 μ m	-85.8- -26.7	0.001
treatment 2	17	2.6 μ m	-32.9 – 38.0	0.879
treatment 3	5	-12.6 μ m	-60.8 – 35.6	0.508
treatment total	22	-21.9 μ m	-53.9 – 10.1	0.170

CFT; Central foveal thickness, CI: Confidence interval, EDI; Enhanced depth imaging, SD-OCT; Spectral domain optical coherence tomography, SRF; Subretinal fluid

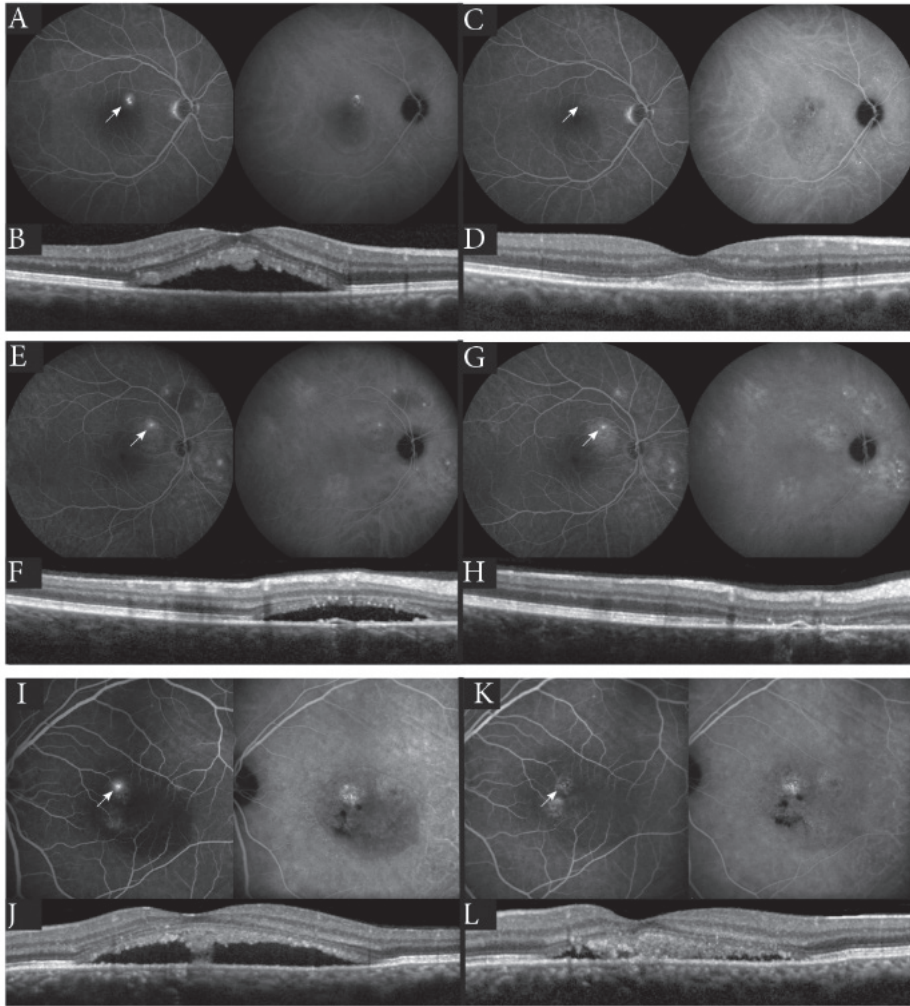


Figure 3.

Examples of changes after treatment as seen on fluorescein angiography (FA), indocyanine green angiography (ICGA) and spectral-domain optical coherence tomography (SD-OCT) in chronic central serous chorioretinopathy (CSC). **A-B/E-F/I-J** Examples of clear hot spots (indicated by the white arrows) on FA (left image) and ICGA (right image) of CSC patients (**A/E/I**) with a corresponding subretinal fluid (SRF) accumulation on SD-OCT (**B/F/J**) before treatment. **C-D/G-H/K-L** The same imaging modalities in the same patients after treatment (respectively). **C-D** An illustration of the disappearance of the hot spot in FA and ICGA (**C**; white arrow), as well as the resolution of the SRF on SD-OCT (**D**). **G-H** Persistence of the hot spot on FA and ICGA (**G**; white arrow) after treatment, with an absence of SRF on SD-OCT (**H**). **K-L** The hot spot as seen before the treatment on FA and ICGA (**I**), changed into diffuse staining on FA and ICGA after treatment (**K**; white arrow). Also, a clear decline of SRF was seen on SD-OCT (**L**).

Spectral-domain optical coherence tomography

After the first treatment, the SRF accumulation and the thickness of the choroid showed a significant decrease (mean decrease: 125.6 μm ; range: 88.8 – 162.5 μm ; $p < 0.001$, and mean: 56. μm ; range: 26.7 – 85.8 μm ; $p = 0.001$, respectively), and the CFT showed a mean increase of 5.4 μm (range: 0.1 – 10.46 μm ; $p = 0.044$; **Table 2**).

Nine fellow eyes that did not have an SRF accumulation on OCT were found to be eligible for comparison of the choroidal thickness on the EDI-OCT scan with the affected study eyes. For this analysis only the difference between the first EDI-OCT scan and the last available EDI-OCT was used. The mean decrease in choroidal thickness was significantly lower in the untreated fellow eyes without SRF than in the treated study eyes (-58.7 μm in the study eyes versus -14.4 μm in the fellow eyes ($p = 0.006$)).

In 9 eyes (15%), of which 8 responded well to the one half-dose PDT treatment with a complete resolution of SRF, a gradual anatomical alignment of the outer photoreceptor structure was seen on SD-OCT in the months following SRF resolution after treatment (**Figure 4**), which also resulted in VA improvement in 5 of these eyes (50%) at the final follow-up visit (approximately 5-6 months after treatment).

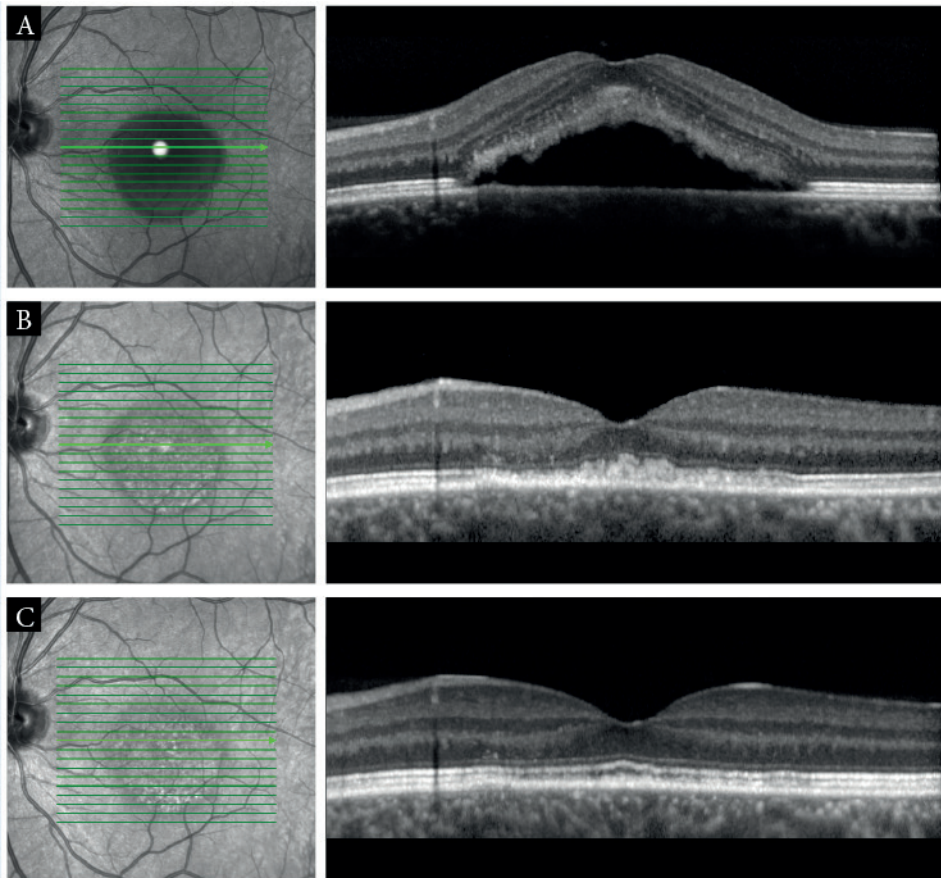


Figure 4.

An example of recovery of the photoreceptor layer on the long-term follow-up on Spectral Domain Optical Coherence Tomography (SD-OCT) after half-dose photodynamic therapy (PDT). **(A)** An SD-OCT of a left eye with active chronic CSC as evidenced by subretinal fluid. **(B)** An SD-OCT scan of the same eye taken 9 weeks after half-dose PDT. The treatment resulted in complete absence of the subretinal fluid (SRF), but the OCT layers corresponding to the outer photoreceptor structures are still irregular (visual acuity: 0.30 LogMAR). **(C)** An SD-OCT scan of the same eye taken 25 weeks after the treatment, without further therapeutic intervention. The SRF is still absent and the outer photoreceptor layers have gradually remodeled to a more physiological aspect, which corresponded to a visual acuity increase to 0.03 LogMAR.

Development of choroidal neovascularisation

During follow-up, 3 eyes (5%) of 3 patients (2 female and 1 male, aged; 68, 51 and 40 years) in this study cohort developed a CNV. Two of these eyes received 2 half-dose PDT treatments and 1 HSML treatment according to the protocol, before the development of the CNV. One eye received 2 half-dose PDT treatments before treatment with bevacizumab was started after the diagnosis of CNV was established. One patient refused anti-VEGF treatment and was lost to follow-up. In one patient anti-VEGF treatment caused an incomplete decrease

in SRF, whereas in the other patient an increase in SRF accumulation was seen despite treatment with bevacizumab.

Re-evaluation of the initial imaging before inclusion in the study treatment protocol in these 3 patients with CNV showed lesions suggestive for a very early stage of a CNV that may already have been present and slumbering at that time point. However, the clinical characteristics of the lesions at that point in time appeared more compatible with a diagnosis of chronic CSC without CNV than with CNV as primary cause of the SRF accumulation.

Visual acuity

Eyes were divided into two groups for specific sub-analysis: group 1 consisting of patients with only one half-dose PDT treatment and group 2 containing patients with more than one treatment.

When looking at the overall change in VA after the first half-dose PDT treatment, among all eyes a mean decrease of 0.12 LogMAR (95% CI = -0.07 to -0.17, $p < 0.0001$) was found. When dividing the patients into the aforementioned subgroups, we observed that patients who received only 1 treatment appeared to have a more pronounced, but not significantly different, VA improvement as compared to the group that received multiple treatments ((-0.14 LogMAR (95% CI = -0.07 to -0.20; $p < 0.0001$) versus -0.09 LogMAR (95% CI = -0.01 to -0.18; $p = 0.038$), respectively).

The mean VA at the last visit in group 1 showed a further increase at the final visit (-0.16 LogMAR (95% CI: -0.10 to -0.23, $p < 0.001$) as compared to the change in VA at the first control visit, whereas the mean VA in group 2 did not show a significant change at the final visit as compared to the change after the first treatment (-0.08 LogMAR (95% CI: 0.01 to -0.18, $p = 0.082$).

When comparing the change in VA after the first, second and third treatment, the highest increase in VA was seen after the first treatment (**Figure 5**).

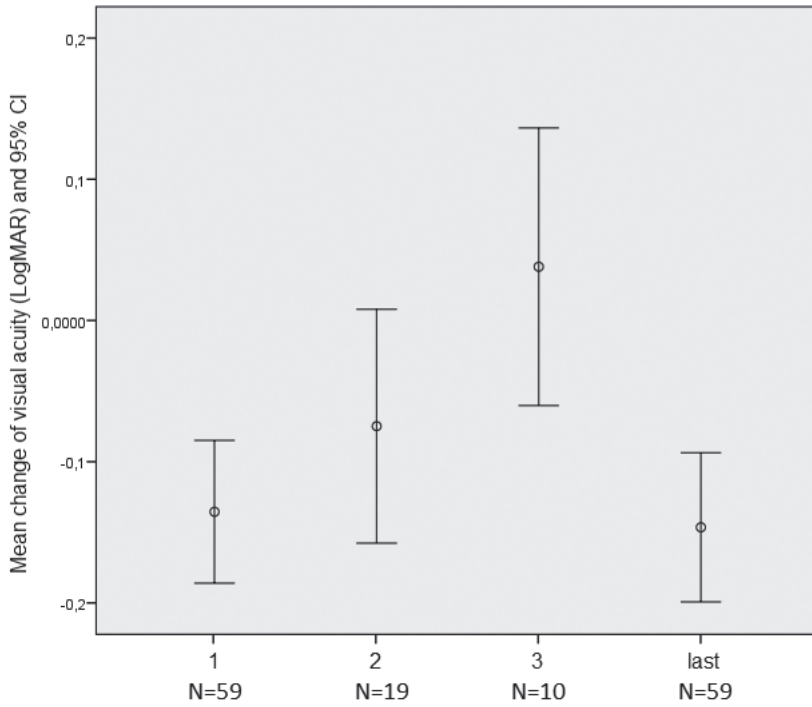


Figure 5.

The mean change of visual acuity (LogMAR) and 95% confidence interval after each treatment (1-3 respectively), and the change between the first and the last known measurements of visual acuity (last).

Discussion

This study of a prospective treatment protocol for chronic CSC describes a positive treatment response using sequential half-dose PDT and HSML treatment. The most significant treatment response was seen after the first treatment with half-dose PDT, with a complete resolution of SRF in 63% of chronic CSC cases after 1 half-dose PDT treatment. HSML treatment as “salvage therapy” in previous non-responders to 2 half-dose PDT treatments had a lower treatment response rate, with only 2 of 10 eyes having complete absence of SRF at the final follow-up after HSML treatment.

The success rate of half-dose PDT treatment in our study, defined as an absence of the SRF on OCT after treatment, is lower than reported in previous retrospective studies. A possible explanation may relate to the fact that 25% of the included patients had previously received a treatment (excluding PDT) for chronic CSC before being enrolled in our treatment protocol. Also, we observed that a second half-dose PDT treatment, in patients with persistent SRF, appeared to have a lower chance of success. It is possible that the subtle changes in the choroidal vasculature caused by the first half-dose PDT treatment decreases the susceptibility of the choroidal vasculature to further treatment. Sonoda et al. described a decrease in luminal area of the choroidal vessels after PDT treatment in patients with AMD using non-reduced treatment settings.³⁰ This decreased choroidal luminal volume may result in a lower concentration of verteporfin (Visudyne[®]) at the area to treat, and therefore reduce the efficacy of a second half-dose PDT treatment. In addition, changes at the level of the RPE have been reported after PDT treatment.^{31, 32} Pre-existent RPE dysfunction due to the chronic CSC itself and/or potential damage to the RPE caused by the previous PDT treatment may interfere with the HSML treatment effect, which could result in non-response. Also, the titration of a harmless but optimally effective subthreshold HSML treatment effect remains uncertain. However, based on previously published studies we believe that the HSML treatment settings used in our study are in the upper range of the subthreshold. Selective retinal therapy, on the other hand, is a technique introduced by Roeder and colleagues,³³ in which the RPE is selectively treated with short laser pulses (microsecond pulse duration), based on the leakage area seen on FA. The advantage of this technique is that response of the RPE can be detected during the treatment procedure due to the occurrence of microbubbles, and after treatment by laser effects on the RPE on angiography.³⁴ As first-line therapy, this technique has shown clinical success in chronic cases, as well as in patients with acute CSC.^{35, 36} However, we did not study the HSML treatment used as a first-line therapy, and are therefore unable to compare these results. It is possible that first-line treatment of chronic CSC with HSML would be more effective,²⁰ and although no serious side effects such a RPE atrophy have been described thus far for selective retinal therapy, we chose the HSML treatment in which no anatomical damage is detected, for our study. Additionally, we were unable to identify a specific subgroup of chronic CSC patients that may be less likely

to respond to half-dose PDT and/or HSML treatment based on the available clinical and imaging characteristics.

Our data show that the highest gain in VA occurs after the first half-dose PDT treatment. The second half-dose PDT treatment and HSML treatment showed less effect on VA. Where a previous study already outlined the importance of the correlation between the initial VA and the final outcome,³⁷ our findings can also guide clinicians in providing further prognostic information to the patients. Based on the current findings, ophthalmologists may inform their patients that most gain of VA occurs after the first half-dose PDT treatment, and that there may be a slow VA gain over up to 6 months due associated with gradual anatomical recovery (**Figure 4**). The gradual VA gain has been described in previous studies. Some prognostic factors have been found to be of influence on the final VA outcome. Wang et al. described the development of macular atrophy if a subretinal detachment persists longer than 4 months.¹³ Our data did not reveal a clear correlation between the period of complaints and the visual outcome, which could be due to the small sample size. Piccolino et al. also reported that the preservation of the outer photoreceptor layer is a prognostic factor of the VA.³⁸

We show that the CFT significantly increased after treatment. It is possible that while SRF is present, the SRF accumulation stretches the overlying fovea and therefore causes a decreased CFT. Prolonged SRF accumulation that separates the neuroretina and RPE and precludes their normal symbiotic interaction, as well as the possible foveal stretching, may cause irreversible anatomical and functional retinal damage with vision loss. Comparable mechanisms have been reported in the Müller cells of rats after mechanically stretching was performed.³⁹ Although, our findings were significant, the difference was relatively small (5.4 μm), and it should be kept in mind that this observation may be caused by the individual measurement error.

In this study, 3 patients developed a CNV. PDT can cause hypoperfusion of the choriocapillaris,¹⁵ which may play a role in the development of CNV in these cases. On the other hand, our protocol uses half-dose PDT in which side-effects such as CNV have rarely been reported. In addition, a 4-year follow-up study of PDT using full settings in CSC has found no evidence of CNV development.⁴⁰ Re-evaluation of the initial imaging before treatment in the 3 patients with CNV in the present study revealed abnormalities that could in retrospect be compatible with a subtle, initial stage of CNV. It is unclear if half-dose PDT may increase the risk of further growth of a smoldering, small CNV. A certain degree of clinical and genetic overlap between age-related macular degeneration and chronic CSC has previously been described.^{5, 41} This diagnostic pitfall should be kept in mind in the case of a suboptimal effect of half-dose PDT treatment in chronic CSC patients, or vice versa in non-response to anti-VEGF in CNV patients.

The pathophysiological mechanism of chronic CSC remains unknown, although many theories have been postulated. One generally accepted theory postulates that the SRF primary derives from fluid leakage in the choroid through a dysfunctional RPE with a disrupted outer blood-retinal barrier.^{3, 42} Multimodal imaging using EDI-OCT and ICGA has shown evidence of choroidal dilation, congestion and hyperpermeability of the choriocapillaris in chronic CSC.^{9, 10, 43, 44} The treatment mechanism of PDT is based on this choroidal dysfunction. PDT is assumed to induce a remodeling of the choroidal vasculature, supposedly through selective vascular occlusion due to damage to choroidal endothelial cells and subsequent thrombotic events of the choriocapillaris.^{45, 46} This change in the choroidal vasculature would then result in a reduced choroidal congestion, and less vascular hyperpermeability and extravascular leakage.^{45, 47, 48} Maruko and co-workers have also identified a decrease in choroidal thickness after half-dose PDT treatment using EDI-OCT, which supports the aforementioned presumed treatment effects on the choroid.⁴⁹ PDT is therefore one of the most commonly used treatment modalities in chronic CSC.^{20, 21} Although, it is suggested that these changes in choroidal thickness may result from diurnal variation,⁵⁰ we do not think that this phenomenon can fully explain the findings in this study. Especially the fact that a significantly greater decrease in choroidal thickness was seen in the study eye as compared to the fellow eye, which was examined in the same visit, supports a treatment effect. We have found the highest treatment response rate after the first half-dose PDT treatment, as well as a significant decrease in choroidal thickness after this treatment, which may also indicate that treatment of the choroidal structures as a primary driving force for SRF accumulation can treat the SRF as a consequence of this choroidal process. Also, the findings on ICGA in our study seemed to correspond better with the findings on SD-OCT than FA.

Besides the apparently prominent role for choroidal dysfunction in CSC, dysfunction of the RPE also seems to play an important role, but it is unclear if there is primary RPE dysfunction or that its dysfunction is purely secondary to the choroidal abnormalities.^{2, 3} To inhibit the leakage of SRF, focal argon (suprathreshold) laser treatment of the “hot spots” of RPE leakage has been used in CSC. However, despite the fact that argon laser photocoagulation may be able to shorten the duration of SRF accumulation, there appears to be no or limited effect on VA and disease recurrence rate.^{49, 51-53} Also, conventional laser therapy cannot be used to treat hot spots of leakage near the fovea, because of the risk of central scotoma, long-term focal laser scar expansion (atrophic creeping) and/or secondary CNV development. Chronic CSC patients often have larger and/or multiple areas of SRF leakage that would make the risk of damage of Argon laser treatment even higher. The use of conventional suprathreshold laser treatment in chronic CSC patients has therefore lost popularity especially with the description of alternative treatments such as PDT, and HSML treatment that seem to have a more favorable safety profile.³ Our proposed HSML treatment protocol uses subthreshold settings, avoiding the risks of the conventional laser therapy.^{20, 21} Anti-VEGF treatment has also been proposed as therapeutic option. However, Bae and co-workers showed that

in terms of the anatomic outcomes, the effect of ranibizumab injections was inferior to low-fluence PDT.⁵⁴ Therefore, a primarily VEGF-driven process seems less likely, although increased VEGF levels could play a significant role in the mechanism of CNV development in advanced chronic CSC. Other treatment modalities, including for instance mineralocorticoid antagonists such as eplerenone or spironolactone, may also be considered as alternative treatment options in chronic CSC,⁵⁵ although the effectiveness of eplerenone in previously treatment-resistant chronic CSC may also be limited.¹⁶

In conclusion, this prospective study has demonstrated effective treatment with half-dose PDT in chronic CSC. Patients should be informed that the highest chance of success and most visual gain is to be expected after the first half-dose PDT treatment. The role of HSML treatment in CSC remains unclear, and no results from multicentre randomized controlled treatment trials on this topic have been published thus far. We are currently performing such a multicenter prospective randomized controlled trial comparing half-dose PDT with HSML as primary treatment for chronic CSC

[EudraCT number 2012-004555-36, NCT01797861; <http://clinicaltrials.gov/>].

References

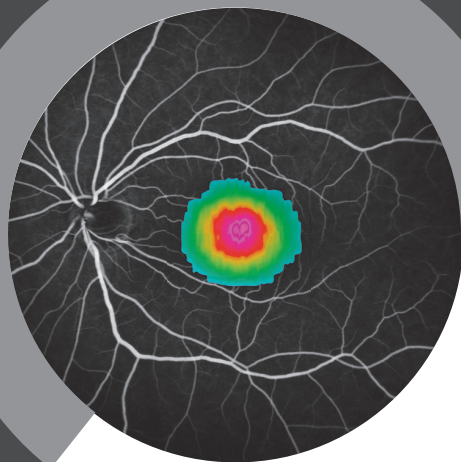
1. Liew G, Quin G, Gillies M, Fraser-Bell S. Central serous chorioretinopathy: a review of epidemiology and pathophysiology. *Clin Experiment Ophthalmol* 2013;41(2):201-14.
2. Wang M, Munch IC, Hasler PW, et al. Central serous chorioretinopathy. *Acta Ophthalmol* 2008;86(2):126-45.
3. Nicholson B, Noble J, Forooghian F, Meyerle C. Central serous chorioretinopathy: update on pathophysiology and treatment. *Surv Ophthalmol* 2013;58(2):103-26.
4. Gemenetzi M, De Salvo G, Lotery AJ. Central serous chorioretinopathy: an update on pathogenesis and treatment. *Eye (Lond)* 2010;24(12):1743-56.
5. de Jong EK BM, Schellevis RL, Bakker B, Mohr JK, Fauser S, Keunen JEE, Hoyng CB, den Hollander AI & Boon CJF Chronic central serous chorioretinopathy is associated with genetic variants implicated in age-related macular degeneration. *Ophthalmology* 2015;122(3):562-70.
6. Miki A, Kondo N, Yanagisawa S, et al. Common variants in the complement factor H gene confer genetic susceptibility to central serous chorioretinopathy. *Ophthalmology* 2014;121(5):1067-72.
7. Mazzuca DE, Benson WE. Central serous retinopathy: variants. *Surv Ophthalmol* 1986;31(3):170-4.
8. Gass JD. Pathogenesis of disciform detachment of the neuroepithelium. *Am J Ophthalmol* 1967;63(3):Suppl:1-139.
9. Prunte C, Flammer J. Choroidal capillary and venous congestion in central serous chorioretinopathy. *Am J Ophthalmol* 1996;121(1):26-34.
10. Spaide RF, Koizumi H, Pozzoni MC. Enhanced depth imaging spectral-domain optical coherence tomography. *Am J Ophthalmol* 2008;146(4):496-500.
11. Spaide RF, Campeas L, Haas A, et al. Central serous chorioretinopathy in younger and older adults. *Ophthalmology* 1996;103(12):2070-9; discussion 9-80.
12. Eandi CM, Ober M, Iranmanesh R, et al. Acute central serous chorioretinopathy and fundus autofluorescence. *Retina* 2005;25(8):989-93.
13. Wang MS, Sander B, Larsen M. Retinal atrophy in idiopathic central serous chorioretinopathy. *Am J Ophthalmol* 2002;133(6):787-93.
14. Zhao M, Celerier I, Bousquet E, et al. Mineralocorticoid receptor is involved in rat and human ocular chorioretinopathy. *J Clin Invest* 2012;122(7):2672-9.
15. Quin G, Liew G, Ho IV, et al. Diagnosis and interventions for central serous chorioretinopathy: review and update. *Clin Experiment Ophthalmol* 2013;41(2):187-200.
16. Breukink MB, den Hollander AI, Keunen JE, et al. The use of eplerenone in therapy-resistant chronic central serous chorioretinopathy. *Acta Ophthalmol* 2014;92(6):e488-90.
17. Lavinsky D, Cardillo JA, Melo LA, Jr., et al. Randomized clinical trial evaluating mETDRS versus normal or high-density micropulse photocoagulation for diabetic macular edema. *Invest Ophthalmol Vis Sci* 2011;52(7):4314-23.
18. Malik KJ, Sampat KM, Mansouri A, et al. Low-intensity/high-density subthreshold micropulse diode laser for chronic central serous chorioretinopathy. *Retina* 2015;35(3):532-6.

19. Eriktila OC, Crosby-Nwaobi R, Lotery AJ, Sivaprasad S. Photodynamic therapy for central serous chorioretinopathy. *Eye (Lond)* 2014;28(8):944-57.
20. Ricci F, Missiroli F, Regine F, et al. Indocyanine green enhanced subthreshold diode-laser micropulse photocoagulation treatment of chronic central serous chorioretinopathy. *Graefes Arch Clin Exp Ophthalmol* 2009;247(5):597-607.
21. Chan WM, Lim TH, Pece A, et al. Verteporfin PDT for non-standard indications--a review of current literature. *Graefes Arch Clin Exp Ophthalmol* 2010;248(5):613-26.
22. Chan WM, Lai TY, Lai RY, et al. Safety enhanced photodynamic therapy for chronic central serous chorioretinopathy: one-year results of a prospective study. *Retina* 2008;28(1):85-93.
23. Chen SN, Hwang JF, Tseng LF, Lin CJ. Subthreshold diode micropulse photocoagulation for the treatment of chronic central serous chorioretinopathy with juxtafoveal leakage. *Ophthalmology* 2008;115(12):2229-34.
24. Roisman L, Magalhaes FP, Lavinsky D, et al. Micropulse diode laser treatment for chronic central serous chorioretinopathy: a randomized pilot trial. *Ophthalmic surgery, lasers & imaging retina* 2013;44(5):465-70.
25. Valmaggia C, Haueter I, Niederberger H. Photodynamic therapy in the treatment of persistent central serous chorioretinopathy: a two-year follow-up. *Klin Monbl Augenheilkd* 2012;229(4):323-6.
26. Lai TY, Chan WM, Li H, et al. Safety enhanced photodynamic therapy with half dose verteporfin for chronic central serous chorioretinopathy: a short term pilot study. *Br J Ophthalmol* 2006;90(7):869-74.
27. Nicolo M, Zoli D, Musolino M, Traverso CE. Association between the efficacy of half-dose photodynamic therapy with indocyanine green angiography and optical coherence tomography findings in the treatment of central serous chorioretinopathy. *Am J Ophthalmol* 2012;153(3):474-80 e1.
28. Rouvas A, Stavarakas P, Theodossiadis PG, et al. Long-term results of half-fluence photodynamic therapy for chronic central serous chorioretinopathy. *Eur J Ophthalmol* 2012;22(3):417-22.
29. Lanzetta P, Furlan F, Morgante L, et al. Nonvisible subthreshold micropulse diode laser (810 nm) treatment of central serous chorioretinopathy. A pilot study. *Eur J Ophthalmol* 2008;18(6):934-40.
30. Sonoda S, Sakamoto T, Yamashita T, et al. Choroidal structure in normal eyes and after photodynamic therapy determined by binarization of optical coherence tomographic images. *Invest Ophthalmol Vis Sci* 2014;55(6):3893-9.
31. Postelmans L, Pasteels B, Coquelet P, et al. Severe pigment epithelial alterations in the treatment area following photodynamic therapy for classic choroidal neovascularization in young females. *Am J Ophthalmol* 2004;138(5):803-8.
32. Wachtlin J, Behme T, Heimann H, et al. Concentric retinal pigment epithelium atrophy after a single photodynamic therapy. *Graefes Arch Clin Exp Ophthalmol* 2003;241(6):518-21.
33. Roider J, Brinkmann R, Wirbelauer C, et al. Retinal sparing by selective retinal pigment epithelial photocoagulation. *Arch Ophthalmol* 1999;117(8):1028-34.
34. Schuele G, Elsner H, Framme C, et al. Optoacoustic real-time dosimetry for selective retina treatment. *J Biomed Opt* 2005;10(6):064022.

35. Klatt C, Saeger M, Oppermann T, et al. Selective retina therapy for acute central serous chorioretinopathy. *Br J Ophthalmol* 2011;95(1):83-8.
36. Elsner H, Porksen E, Klatt C, et al. Selective retina therapy in patients with central serous chorioretinopathy. *Graefes Arch Clin Exp Ophthalmol* 2006;244(12):1638-45.
37. Aggio FB, Roisman L, Melo GB, et al. Clinical factors related to visual outcome in central serous chorioretinopathy. *Retina* 2010;30(7):1128-34.
38. Piccolino FC, Borgia L. Central serous chorioretinopathy and indocyanine green angiography. *Retina* 1994;14(3):231-42.
39. Wang X, Xu G, Fan J, Zhang M. Mechanical stretching induces matrix metalloproteinase-2 expression in rat retinal glial (Muller) cells. *Neuroreport* 2013;24(5):224-8.
40. Silva RM, Ruiz-Moreno JM, Gomez-Ulla F, et al. Photodynamic therapy for chronic central serous chorioretinopathy: a 4-year follow-up study. *Retina* 2013;33(2):309-15.
41. Fung AT, Yannuzzi LA, Freund KB. Type 1 (sub-retinal pigment epithelial) neovascularization in central serous chorioretinopathy masquerading as neovascular age-related macular degeneration. *Retina* 2012;32(9):1829-37.
42. Yannuzzi LA. Central serous chorioretinopathy: a personal perspective. *Am J Ophthalmol* 2010;149(3):361-3.
43. Imamura Y, Fujiwara T, Margolis R, Spaide RF. Enhanced depth imaging optical coherence tomography of the choroid in central serous chorioretinopathy. *Retina* 2009;29(10):1469-73.
44. Spaide RF, Hall L, Haas A, et al. Indocyanine green videoangiography of older patients with central serous chorioretinopathy. *Retina* 1996;16(3):203-13.
45. Schlotzer-Schrehardt U, Viestenz A, Naumann GO, et al. Dose-related structural effects of photodynamic therapy on choroidal and retinal structures of human eyes. *Graefes Arch Clin Exp Ophthalmol* 2002;240(9):748-57.
46. Ma J, Meng N, Xu X, et al. System review and meta-analysis on photodynamic therapy in central serous chorioretinopathy. *Acta Ophthalmol* 2014;92(8):e594-601.
47. Chan WM, Lam DS, Lai TY, et al. Choroidal vascular remodelling in central serous chorioretinopathy after indocyanine green guided photodynamic therapy with verteporfin: a novel treatment at the primary disease level. *Br J Ophthalmol* 2003;87(12):1453-8.
48. Schmidt-Erfurth U, Laqua H, Schlotzer-Schrehard U, et al. Histopathological changes following photodynamic therapy in human eyes. *Arch Ophthalmol* 2002;120(6):835-44.
49. Maruko I, Iida T, Sugano Y, et al. Subfoveal choroidal thickness after treatment of central serous chorioretinopathy. *Ophthalmology* 2010;117(9):1792-9.
50. Tan CS, Cheong KX, Sadda SR. Changes in choroidal thickness after photodynamic therapy in patients with central serous chorioretinopathy. *Acta Ophthalmol* 2014;92(1):e79.
51. Robertson DM, Ilstrup D. Direct, indirect, and sham laser photocoagulation in the management of central serous chorioretinopathy. *Am J Ophthalmol* 1983;95(4):457-66.
52. Watzke RC, Burton TC, Leaverton PE. Ruby laser photocoagulation therapy of central serous retinopathy. I. A controlled clinical study. II. Factors affecting prognosis. *Trans Am Acad Ophthalmol Otolaryngol* 1974;78(2):OP205-11.

53. Gilbert CM, Owens SL, Smith PD, Fine SL. Long-term follow-up of central serous chorioretinopathy. *Br J Ophthalmol* 1984;68(11):815-20.
54. Bae SH, Heo JW, Kim C, et al. A randomized pilot study of low-fluence photodynamic therapy versus intravitreal ranibizumab for chronic central serous chorioretinopathy. *Am J Ophthalmol* 2011;152(5):784-92 e2.
55. Bousquet E, Beydoun T, Zhao M, et al. Mineralocorticoid receptor antagonism in the treatment of chronic central serous chorioretinopathy: a pilot study. *Retina* 2013;33(10):2096-102.





CHAPTER 4.2

Efficacy of photodynamic therapy in steroid-associated chronic central serous chorioretinopathy: a case-control study

Myrte B. Breukink*, Danial Mohabati*, Elon H.C. van Dijk, Anneke I. den Hollander, Eiko K. de Jong, Greet Dijkman, Jan E.E. Keunen, Carel B. Hoyng & Camiel J.F. Boon

Published in: *Acta Ophthalmology*. 2016;94(6):565-72
(*joint first author)

Purpose:

To investigate if patients who developed chronic central serous chorioretinopathy (CSC) in association with corticosteroid treatment respond differently to photodynamic therapy (PDT) as compared to patients who have not used steroids.

Methods:

Clinical evaluation included visual acuity (VA), fundoscopy, optical coherence tomography (OCT), fluorescein- and indocyanine green angiography. The main outcome measure was a complete resolution of subretinal fluid (SRF) on OCT after PDT.

Results:

One hundred and twenty-three eyes (117 patients), including 35 steroid-associated cases (29%), who received PDT treatment with reduced settings for active chronic CSC were included. Complete resolution of SRF on OCT was seen in 69% of the steroid-associated cases, and in 50% of the controls after PDT treatment ($p = 0.062$). At the final follow-up moment 74% of the cases had a complete resolution of SRF compared to 60% in the control group ($p = 0.142$). The VA at the first visit after therapy showed an increase in both groups (mean VA before treatment; cases: 69 ± 14 Early Treatment Diabetic Retinopathy Study (ETDRS) letters, controls: 74 ± 13 ETDRS letters, mean VA first visit after treatment; cases: 76 ± 13 ETDRS letters, controls: 75 ± 13 ETDRS letters). No significant differences were seen in response to PDT between the patients who continued corticosteroid treatment and those who ceased the use of corticosteroids.

Conclusions:

PDT appears to be equally effective in patients suffering from steroid-associated chronic CSC as compared to chronic CSC patients who do not use corticosteroids. Continuation of corticosteroids at the time of PDT treatment does not seem to adversely affect PDT response.

Introduction

Central serous chorioretinopathy (CSC) is a relatively common early-onset eye disease, characterized by an accumulation of leaked serous fluid under the retina, causing a detachment of the neuroretina. This subretinal fluid (SRF) leakage results from dysfunction of the retinal pigment epithelium (RPE), presumably caused by choroidal congestion and thickening and hyperpermeability of the choroid.¹⁻⁴

Two main subtypes can be distinguished: acute CSC and chronic CSC.¹⁻⁷ In acute CSC, patients manifest with sudden and marked vision loss, and acute CSC is characterized by a focal leakage spot seen on fluorescein angiography (FA) that indicates leakage at the level of the retinal pigment epithelium (RPE).¹⁻⁹ This SRF accumulation resolves spontaneously within 3 months in most acute CSC patients, with near-complete visual recovery.^{2,4}

Compared to acute CSC patients, chronic CSC patients present at an older age, with a disease onset that is generally experienced as less sudden.⁷ Furthermore, chronic CSC generally shows a more diffuse and sometimes multifocal leakage pattern on FA and especially on indocyanine green angiography (ICGA), often with more widespread and irregular RPE changes associated with various degrees of low-grade leakage as compared to acute CSC.^{1-6, 8-11} In contrast to acute CSC, the SRF accumulation in chronic CSC tends to persist for more than 3 months, although it can wax and wane multiple times.⁴⁻⁶ Additionally, ICGA characteristically demonstrates widespread hyperfluorescent areas of choroidal congestion and hyperpermeability, which are more extensive in chronic CSC than in acute CSC.^{3, 8, 12-14} These abnormalities mostly overlap with those seen on FA, but can also be present without any evidence of leakage on FA in chronic CSC.⁸

A persistent serous neuroretinal detachment in chronic CSC can cause progressive and irreversible photoreceptor damage.^{3, 15, 16} Therefore, it is common practice to treat these patients, although prospective multicenter randomized controlled trials on the optimal treatment are largely lacking. Currently, photodynamic laser therapy (PDT) is one of the most frequently used treatment modalities in chronic CSC, with reported anatomical success rates in retrospective studies ranging from 70-100%.¹⁷⁻²⁰ This is a relatively broad range. Therefore, it is of clinical relevance to identify possible factors that could influence treatment success.

Although the exact mechanism by which CSC develops is largely unclear, several associations and risk factors have been described in the literature, such as male gender, stress, type A personality, pregnancy, and the use of corticosteroids.²¹⁻²³ In addition, genetic risk factors have recently been identified in CSC.²⁴⁻²⁶ In particular the use of corticosteroids, is one of the most prominent risk factors known in CSC, although the reported effect sizes vary (odds ratio: 2.4 and 10.3).^{21, 27} Some patients report a clear association between the initiation of corticosteroids and the start of CSC-associated visual complaints. This could indicate possible differences in the disease mechanisms between steroid users and non-steroid users. The

previous or ongoing use of corticosteroids is likewise thought to be a risk factor for ongoing disease activity in chronic CSC, and could potentially limit the efficacy of treatment.

In studies on PDT as treatment for chronic CSC the use of corticosteroids is often an exclusion criterion; therefore it is unclear if the outcome of PDT in chronic CSC is different compared to patients who have no history of current or previous corticosteroid use.

The aim of this study was to investigate whether the response to PDT is different in treatment-naive patients presenting with steroid-associated chronic CSC versus chronic CSC patients without a history of steroid use.

Methods

Patients

The patients enrolled for this retrospective case-control study were seen at the outpatient clinics of the Departments of Ophthalmology of the Radboud University Medical Center (Nijmegen, the Netherlands) and the Leiden University Medical Center (Leiden, the Netherlands) between January 2004 and February 2015. We retrospectively reviewed the medical records of all patients who had been diagnosed with chronic CSC and who consequently had been treated with PDT as first-line therapy. The diagnosis of chronic CSC was based on characteristic features as seen on multimodal imaging consisting of OCT, FA, and ICGA. These features included presence of SRF in the macula on OCT, and irregular diffuse and/or multifocal hyperfluorescent areas in the posterior pole, corresponding to irregular RPE window defects with or without obvious hot spots of leakage on FA, with one or more corresponding hyperfluorescent areas on ICGA (**Figure 1**).²⁵ Approval for this study was obtained at the local institutional review boards, and the study adhered to the tenets of the Declaration of Helsinki.

At the visit prior to the PDT, the first evaluation visit after therapy, and at the last available follow-up visit, the following parameters were collected; visual acuity (VA) in Early Treatment Diabetic Retinopathy Study (ETDRS) letters, start date of visual symptoms, the use of corticosteroids (including reason for use and route of administration), presence of SRF on OCT, and central retinal thickness (CRT) as measured automatically by the integrated software of the Spectralis™ HRA+OCT (Heidelberg Engineering, Heidelberg, Germany). Due to a satisfying response to treatment, only the first evaluation visit was available in a part of the cases and the controls. If the first evaluation visit after treatment was also the last available follow-up visit, the collected information was only used in the analysis for the first evaluation visit. An exception was made for the absence of SRF at final follow-up.

Steroid use

Patients were divided into two groups based on their reported use of steroids; patients who used corticosteroids within 12 months prior to the development of the chronic CSC (cases), and patients who did not have a history of current or prior use of any type of corticosteroids (controls). For the first group, only patients in whom a relation between steroid use and the onset of CSC symptoms was highly suspected, were included. This probability of a causal relationship was assessed by the treating physician at the moment of diagnosis.

For sub-analysis in the cases, a further distinction was made between patients who continued steroid use in the period when PDT had been performed and those who ceased corticosteroid use before treatment.

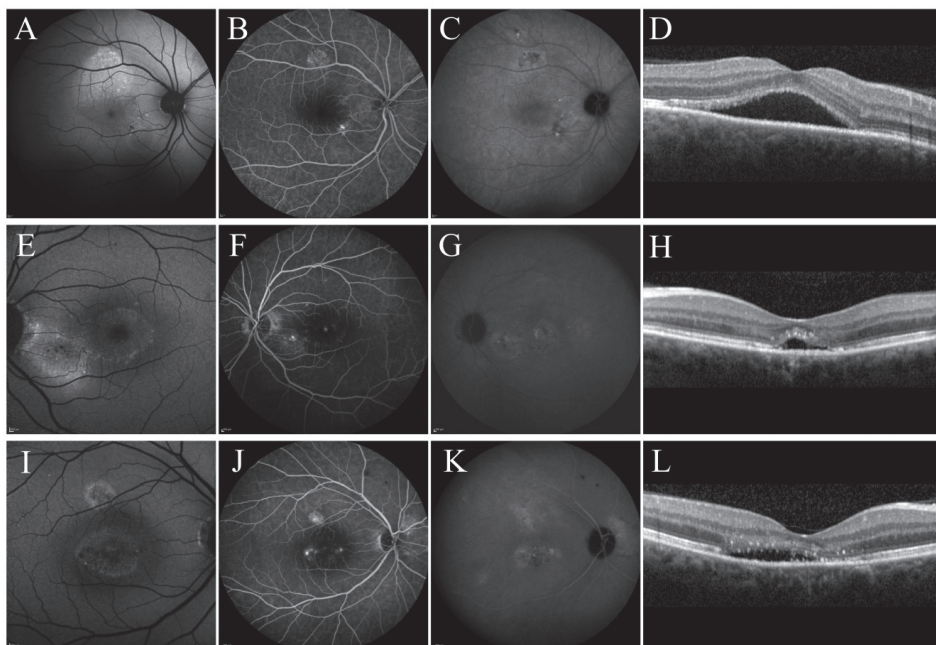


Figure 1.

Examples of the typical abnormalities as observed on multimodal imaging techniques (left to right; fundus autofluorescence (FAF), early fluorescein angiography (FA), mid-phase indocyanine green angiography (ICGA), and optical coherence tomography (OCT)) in 3 patients with chronic central serous chorioretinopathy (CSC). The images in the upper 2 rows belong to 2 patients with steroid-associated chronic CSC. **(A-D)** The right eye of a 45-year-old male bodybuilder with frequent steroid injections, illustrating juxtafoveal hyper- autofluorescent irregularities of the retinal pigment epithelium (RPE) layer on FAF**(A)**, multifocal leakage on FA and ICGA **(B-C)**, and subfoveal subretinal fluid (SRF) on OCT**(D)**. **(E-H)** The left eye of a 48-year-old male who used topical steroid cream for skin problems. The FAF shows hyperautofluorescence inferotemporal of the optic disc **(E)**, and hot spots indicating leakage are seen on FA and ICGA accompanied by SRF on OCT **(F-H)**. **(I-L)** The right eye of 56-years-old male who did not report the use of steroids. FAF shows central hyperautofluorescence corresponding to hyperfluorescent leakage on FA and ICGA **(I-K)**, and a flat SRF accumulation on OCT**(L)**.

Photodynamic therapy

For this study, PDT treatment was performed with reduced settings, either with half-dose or half-time as compared to the original settings described for neovascular age-related macular degeneration, depending on the preference of the treating physician.^{28, 29} Before treatment, the pupils were dilated (with 1.0% tropicamide and 2.5% phenylephrine). Verteporfin (Visudyne[®]; 3 mg/m² (for the half-dose PDT) and 6 mg/m² (for the half-time PDT)) was intravenously administered, with an infusion time of 10 minutes. At 15 minutes after the start of the infusion, an anesthetic eye drop was applied (oxybuprocaine 0.4% or equivalent), a contact lens (Volk[®] PDT lens) was positioned on the affected eye, and a laser beam was focused on the area to treat of which the spot size was based on hyperfluorescence as seen on mid-phase (approximately 10 minutes) ICGA. The PDT was performed with standard 50

J/cm² fluency, a PDT laser wavelength of 689 nm, and a treatment duration of 83 seconds in patients treated with half-dose PDT, and 42 seconds in the half-time PDT.

Definition of the outcomes

Effectiveness of the PDT was based on the anatomical recovery as seen on OCT, defined as a complete absence of SRF. Furthermore, we compared the VA and the CRT before and after treatment in each patient, and between the (sub)groups. Additionally, we analyzed the period of time needed to achieve a complete resolution of SRF between the cases and controls. To evaluate the effectiveness of PDT over time, we analyzed the number of recurrences, and also the number of additional treatments that each patient received until the end of the study.

Statistical analysis

Statistical analyses were performed using IBM SPSS software for Windows version 20. For comparisons of continuous numerical data in demographic characteristics and study outcome measures we performed a dependent t-test, an independent t-test or a Mann-Whitney U test as appropriate. Categorical data were analyzed using a Chi-square test. Furthermore, two survival analyses were performed and Kaplan-Meier survival plots were generated comparing the cases with the controls. The following events were used; 'complete resolution of SRF after 1 PDT treatment' and 'complete resolution of SRF at final follow-up'. A two-sided *P* value of less than 0.05 was considered statistically significant.

Results

Patient characteristics

Demographics

Thirty-five eyes of 33 patients (mean age at time of PDT treatment: 55 ± 11.7 years) with corticosteroid-associated chronic CSC, and 88 eyes of 84 patients (mean age at time of PDT treatment: 52 ± 11.1 years) who did not report any use of corticosteroids were included in this study (**Table 1**). General characteristics including age, gender, reported duration of complaints, elapsed time between treatment and first control visit, baseline VA, and mean CRT as measured on OCT at baseline did not differ significantly between the steroid-users and the non-steroid users (**Table 1**).

Among the 33 patients with reported (previous) use of steroids, 9 (27%) patients used corticosteroid cream, 9 (27%) patients reported nasal spray containing steroids, 7 (21%) patients used oral corticosteroids, 4 (12%) patients used steroids by an inhaler, 1 (3%) patient received illegal corticosteroid injections for professional bodybuilding, and the remaining 3 (9%) patients reported (previous) use of steroids via more than one way of administration. The corticosteroid use was continued before, during, and after PDT treatment in 16 (46%) of 35 eyes.

Table 1. Patient demographics in cases and controls

	Cases	Controls	P-value
Eyes (patients)	35 (33)	88 (84)	Not applicable
Gender (m/f)	24/ 11	72 / 16	0.109
Age ^a [range] in years	54.6 [31-80]	52.0 [29-81]	0.285
VA pre-therapy in ETDRS letters (SD)	69 (14)	74 (13)	0.065
CRT before therapy (SD)	381.3 μ m (111)	374.9 μ m (116)	0.782
Duration of complaints in weeks ^b [range]	38.8 [3.1-706.9]	30.3 [3.7-566.0]	0.445
Half-dose PDT / Half-time PDT	30 / 5	82 / 6	0.190

^a Age at the time of photodynamic therapy treatment

^b Median number of weeks between the start of the complaints and therapeutic intervention ETDRS; Early Treatment Diabetic Retinopathy Study, PDT; Photodynamic Therapy, SD; Standard Deviation, VA; Visual Acuity

Optical coherence tomography

At the first control visit after PDT (on average 7.4 ± 2.8 weeks after treatment in the cases, and 7.9 ± 2.9 weeks after treatment in the controls) 22 (63%) eyes of the steroid-associated chronic CSC patients, and 40 (45%) eyes of the controls showed a complete absence of SRF on OCT. Moreover, a clear reduction of SRF was seen in 26% (n=9) of the steroid-associated patients, and in 28% (n=25) of the non-steroid associated controls. During follow-up this reduction led to a complete absence of SRF in 2 (22%) of these cases, and in 4 (16%) eyes of these controls. In 3 (9%) out of 35 steroid-associated eyes with chronic CSC, and 17 (19%) out of the 88 eyes of controls with chronic CSC no changes in SRF were observed on OCT at the first control visit. One eye with steroid-associated chronic CSC (3%) and 6 (7%) eyes in the control group showed an increase in SRF.

When comparing the resolution of SRF using a survival analysis, there was a trend for subjects in the corticosteroid-associated chronic CSC group to have a faster full resolution of SRF as compared to the controls (**Figure 2**).

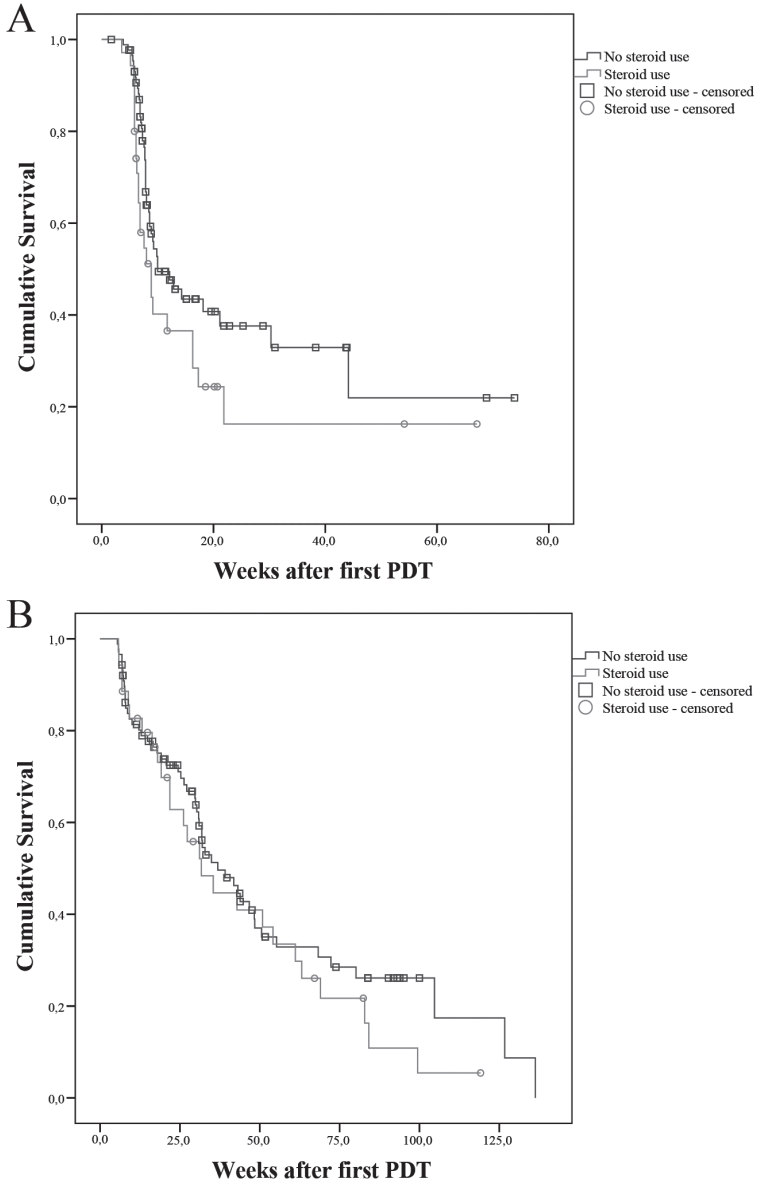


Figure 2.

Kaplan-Meier curves showing the cumulative fraction in treated chronic central serous chorioretinopathy patients. **A.** Endpoint: 'Full resolution of subretinal fluid (SRF) after 1 photodynamic therapy'; median duration before SRF fully resolved in cases: 8.9 weeks [95% CI: 6.4-11.3] and controls: 10.0 weeks [95% CI: 5.2-14.8], ($p = 0.064$) **B.** Endpoint: 'Complete resolution of SRF at final follow-up'; median duration before SRF fully resolved in cases: 31.7 weeks [95% CI:18.6-44.8] and controls: 36.8 weeks [95% CI:25.5-48.2], ($p = 0.344$)

A reduction in CRT was seen in both groups at the first and final follow-up after treatment (**Table 2**). There was no significant difference in the mean reduction of CRT between both groups at final follow up (steroid users (n=21); $114.1 \pm 143.9 \mu\text{m}$, non-steroid users (n=46); $109.4 \pm 109.7 \mu\text{m}$, $p = 0.883$, independent t-test).

During follow-up, a recurrence of SRF on OCT was seen in 6 (25%) of the 24 patients with steroid-associated chronic CSC, and in 9 (20%) of the 44 patients with non-steroid associated chronic CSC who initially showed a good response (absence of SRF on OCT) after PDT. At the final visit (on average 48.4 ± 31.4 weeks post-therapy in cases, and 49.6 ± 49.7 weeks post-therapy in controls) SRF had completely resolved in 26 (74%) out of 35 eyes with steroid-associated chronic CSC, of which 5 (19%) eyes had received additional treatments that consisted of either a second PDT, conventional laser therapy of the hot spot, high-density subthreshold micropulse laser treatment, intravitreal bevacizumab or a combination of the aforementioned treatments (mean number of additional treatments; 1.8 (range 1 – 3)). In the control group, 53 (60%) eyes had complete absence of SRF at final follow-up. Of these eyes 18 (34%) eyes received additional treatment consisting of either a second PDT treatment, high-density subthreshold micropulse laser treatment, intravitreal bevacizumab, intravitreal aflibercept or a combination of the aforementioned treatments (mean number of additional treatments; 1.7 (range 1 – 4)). Of the eyes with SRF on OCT at the last available visit (9 (26%) eyes in the steroid-associated cases, and 35 (40%) eyes in the controls), 18 eyes received additional treatment (2 (22%) eyes in the cases, and 16 (46%) eyes in the controls).

Patients with suspected neovascularisation

In both groups a subretinal choroidal neovascularisation (CNV) was suspected during follow-up in 3 eyes (9%) in the steroid-associated chronic CSC group, and 4 eyes (5%) in the controls, for which intravitreal anti-vascular growth factor treatment (anti-VEGF) was initiated. One of these patients initially responded well to the first PDT treatment with absence of SRF on OCT, followed by recurrence of the SRF. After anti-VEGF therapy 2 eyes (29%) had complete resolution of SRF, and 5 eyes (71%) had persistent SRF. Re-evaluation of the baseline imaging showed small lesions on OCT, FA or ICG that retrospectively could indicate a subtle pre-existent occult CNV or a small polypoidal choroidal vasculopathy (PCV) at baseline in 4 eyes (57%). The mean age of the 7 patients suspected to have a CNV or PCV during follow-up was 64 years, which was significantly older as compared to the general group (mean age; 52 years, , $p = 0.006$, independent t-test). None of these patients had evidence of drusen on ophthalmoscopy, OCT, and FA.

Visual acuity

The mean VA increased significantly after PDT treatment in the steroid-associated chronic CSC group when comparing the VA pre-PDT (69 ± 14 ETDRS letters) to the VA at the first control visit after treatment (76 ± 13 ETDRS letters) ($p < 0.001$, independent t-test). This was also the case in the non-steroid associated patient group (VA before treatment; 74 ± 13 ETDRS letters, VA after treatment; 75 ± 13 ETDRS letters, $p = 0.014$, independent t-test). At the last available visit the mean VA was comparable between cases (72 ± 18 ETDRS letters ($n = 21$)), and controls (71 ± 14 ETDRS letters ($n=45$)) (Table 2). Of those patients in the case group who showed a full resolution of SRF ($n=24$), the VA was improved significantly after the PDT (VA pre-PDT: 70 ± 15 ETDRS letters; VA post-PDT: 78 ± 13 ETDRS letters, $p = 0.001$). This was also the case in control eyes with a full SRF resolution ($n=44$) after the PDT (VA pre-PDT: 72 ± 15 ETDRS letters; VA post-PDT: 78 ± 13 ETDRS letters, $p = 0.001$). No significant differences were found in treatment response on OCT and visual outcome when dividing the group of steroid users into a group of patients who continued the use of steroids (oral, cutaneous crème, nasal spray, inhaler or a combination) during the study period (46% of 35 cases), and a group of patients who stopped the use of steroids during therapy (54%) (**Table 3**). In particular, of the 6 eyes of 5 patients who continued the use of oral corticosteroids during the PDT treatment, 4 (67%) eyes showed a complete resolution of SRF on OCT after PDT treatment at last available visit.

Table 2. Comparison of variables of interest at visit pre- and post-photodynamic therapy in cases and controls

	Cases	Controls	P-value
CRT pre-therapy in μm (SD)	381.1 (111) (n=35)	374.9 (116) (n=88)	0.782
CRT at first follow-up^a in μm (SD)	290.9 (121) (n=35)	282.4 (81) (n=88)	0.655
CRT at final follow-up^b in μm (SD)	289.4 (114) (n=21)	261.7 (54) (n=46)	0.298
VA pre-therapy in ETDRS letters (SD)	69 (14) (n=35)	74 (13) (n=88)	0.065
VA at first follow-up in ETDRS letters ^a (SD)	76 (13) (n=35)	75 (13) (n=88)	0.499
VA at final follow-up in ETDRS letters ^b (SD)	72 (18) (n=21)	71 (14) (n=45)	0.943

^a Average number of weeks between therapeutic intervention and first follow-up in the steroid group: 7.4 weeks, in the non-steroid group: 7.9 weeks ($p=0.445$)

^b Average number of weeks between therapeutic intervention and final follow-up in the steroid group: 48.4 weeks, in the non-steroid group: 49.6 weeks ($p=0.886$)

CRT; Central Retinal Thickness, ETDRS; Early Treatment of Diabetic Retinopathy Study, SD: Standard Deviation, VA; Visual Acuity

Table 3. Comparison of central retinal thickness and visual acuity between patients who continued corticosteroid use during photodynamic therapy (PDT) and those who ceased corticosteroid treatment before PDT.

	Steroids were continued	Steroids were ceased	P-value
CRT pre-therapy in μm (SD)	405.0 (98) (n=16)	361.0 (119) (n=19)	0.249
CRT at first follow-up ^a (SD)	286.3 (103) (n=16)	294.7 (137) (n=19)	0.841
CRT at final follow-up ^b (SD)	227.9 (107) (n=11)	203.1 (125) (n=10)	0.638
VA pre-therapy in ETDRS letters (SD)	66 (14) (n=16)	71 (14) (n=19)	0.285
VA at first follow-up in ETDRS letters ^a (SD)	74 (14) (n=16)	78 (11) (n=19)	0.272
VA at final follow-up in ETDRS letters ^b (SD)	69 (23) (n=11)	75 (12) (n=10)	0.434

^a Average number of weeks between therapeutic intervention and first follow-up in patients who continued corticosteroid treatment : 8.0 weeks, in patients who stopped corticosteroids: 6.9 weeks ($p=0.265$)

^b Average number of weeks between therapeutic intervention and final follow-up in patients who continued corticosteroid treatment: 23.6 weeks, in patients who stopped corticosteroids: 21.7 weeks ($p=0.801$)

CRT; Central Retinal Thickness, ETDRS; Early Treatment of Diabetic Retinopathy Study, SD; Standard Deviation, VA; Visual Acuity

Discussion

This study suggests that the current or recent use of corticosteroids in chronic CSC does not adversely affect the response to PDT. No significant differences were seen between the corticosteroid-associated chronic CSC cases and the controls regarding the treatment response on OCT and on visual outcome.

Current literature reports an improvement of retinal anatomy and VA in 70-100% of chronic CSC after PDT treatment.^{17-20, 30, 31} The success rate of PDT treatment, defined as a complete absence of SRF on OCT, found in the present study is lower than those reported in previous studies. A possible explanation could be that our study evaluated a phenotypically different patient group. Previous studies have differentiated acute and chronic CSC either based on the duration of presence of SRF, or based on phenotypic characteristics. However, thus far no consensus exists on how to define chronicity in CSC.^{1, 32} Where some authors consider a duration of presence of SRF up to 2-3 months as typical for acute CSC,^{3, 8-10, 32} which implicates that if the SRF accumulation would exist longer than 3 months one can speak of a chronic CSC, others argue that CSC becomes chronic after a duration of more than 6 months.^{33, 34} Also, division based on the extensity of abnormalities as seen on multimodal imaging has been described, and Wang et al. demonstrated that in case of a subretinal detachment of more than 4 months, irreversible atrophy in the macula may already ensue.¹⁶ Therefore, in the current study chronic CSC patients were included not only based on a disease duration of more than 3 months, but also on the presence of features indicative of chronicity on multimodal imaging: presence of SRF in the macula on OCT, and irregular diffuse and/or multifocal hyperfluorescent areas in the posterior pole, corresponding to irregular RPE window defects with or without obvious hot spots of leakage on FA, with one or more corresponding hyperfluorescent areas on ICGA.²⁵ In contrast to acute CSC, chronic CSC patients have (and often present with) more widespread abnormalities on multimodal imaging.^{3, 8, 12-14} Although, the current study included cases who seemed to have a follow-up less than 3 months before receiving an intervention, all patients presented phenotypic features that confirmed chronicity. It is likely that the short follow-up time was caused by lack of information about the exact moment of onset of symptoms.

In our study, no differences were found in efficacy of PDT in chronic CSC patients who ceased the corticosteroids in comparison to the patients who had to continue corticosteroids. Lee et al. previously found a treatment response with absence of SRF in 100% of the cases, using either full-dose or half-time PDT, in a retrospective study of 9 steroid-associated CSC patients.³⁵ In this study 5 of the 9 patient discontinued the steroid use, which could be of influence on the response.³⁵ The findings in our study are encouraging as they suggest that the continuation of corticosteroid treatment, if inevitable for other medical indications, does not preclude a favourable response to PDT. It is unclear through which pathophysiological mechanisms corticosteroid use is associated with chronic CSC. For instance, it is still unknown whether corticosteroids are required to develop chronic CSC in the first place, or

if the use of corticosteroids is merely an additional trigger for a subclinical disease state that is already present. The use of corticosteroids is postulated to induce platelet aggregation and vasoconstriction and suppress vasodilators (e.g. nitric oxide and prostaglandins).^{23, 27, 36} Consequently, this may lead to microthrombus formation, which may alter choroidal perfusion and vascular permeability.^{23, 27, 36} On the other hand, corticosteroids do not have the same effect in every patient; Han et al. for example demonstrated that the choroidal thickening seen in steroid-induced CSC seems to be more an exceptional rather than a dose-dependent response, that may be selectively present in vulnerable individuals.³⁷ Choroidal congestion and hyperpermeability appear to be present in chronic CSC patients using corticosteroids as well as in those who do not. PDT may be an effective treatment in both patient subgroups as it is presumed to induce a remodeling of the choroidal vasculature, supposedly through selective vascular occlusion due to damage to choroidal endothelial cells and subsequent thrombotic events of the choriocapillaris that cause a decrease in choroidal thickness, a reduction in choroidal vascular hyperpermeability and leakage through the RPE, and a restoration in the fluid balance in the subretinal space.^{38, 39} PDT using standard settings (verteporfin dose of 6 mg/m², fluency of 50 J/cm², treatment time of 83 seconds), has been associated with adverse effects such as choroidal ischaemia, RPE atrophy, and CNV formation,^{4, 17, 40-42} although a 4-year follow-up study in chronic CSC has not found any adverse effects using this treatment in 46 eyes with chronic CSC.⁴³ PDT using reduced settings has commonly been adopted as this strategy appears to be equally effective and potentially safer compared to standard settings.^{4, 17, 40, 44, 45} However, retrospective evaluation of the baseline imaging in our study showed that of 7 patients who were suspected to have a CNV or PCV during follow-up, 4 patients had small lesions that were suspect for CNV or PCV. These lesions, however, were very subtle and easily overlooked even by experienced ophthalmologists. In the remaining 3 patients, who had no suspect lesions at baseline, it remains unclear if the PDT with reduced settings may have triggered further growth of a possible concealed small CNV. This would indicate that the CNV or the PCV could have been primarily associated with CSC-like changes before PDT was performed, as reported previously.^{46, 47} Therefore, chronic CSC patients should be monitored closely for possible occult CNV and/or PCV, especially elderly patient with a chronic CSC phenotype, and in case of non-response to PDT the initial diagnosis should be re-evaluated.

In conclusion, this study shows that PDT is an effective treatment in patients suffering from steroid-associated chronic CSC, and suggests that the efficacy is comparable to PDT in patients with chronic CSC who do not use corticosteroids. Although the pathophysiological mechanism may not be identical in both patient groups, it is not reflected in the overall treatment outcome of PDT. Therefore, PDT can also be offered as a treatment strategy in patients who are (or previously have been) on corticosteroid treatment.


References

1. Liew G, Quin G, Gillies M, Fraser-Bell S. Central serous chorioretinopathy: a review of epidemiology and pathophysiology. *Clin Experiment Ophthalmol* 2013;41(2):201-14.
2. Gemenetzi M, De Salvo G, Lotery AJ. Central serous chorioretinopathy: an update on pathogenesis and treatment. *Eye (Lond)* 2010;24(12):1743-56.
3. Wang M, Munch IC, Hasler PW, et al. Central serous chorioretinopathy. *Acta Ophthalmol* 2008;86(2):126-45.
4. Nicholson B, Noble J, Forooghian F, Meyerle C. Central serous chorioretinopathy: update on pathophysiology and treatment. *Surv Ophthalmol* 2013;58(2):103-26.
5. von Winning CH, Oosterhuis JA, Renger-van Dijk AH, et al. Diffuse retinal pigment epitheliopathy. *Ophthalmologica* 1982;185(1):7-14.
6. Polak BC, Baarsma GS, Snyers B. Diffuse retinal pigment epitheliopathy complicating systemic corticosteroid treatment. *Br J Ophthalmol* 1995;79(10):922-5.
7. Spaide RF, Campeas L, Haas A, et al. Central serous chorioretinopathy in younger and older adults. *Ophthalmology* 1996;103(12):2070-9; discussion 9-80.
8. Eandi CM, Ober M, Iranmanesh R, et al. Acute central serous chorioretinopathy and fundus autofluorescence. *Retina* 2005;25(8):989-93.
9. Quin G, Liew G, Ho IV, et al. Diagnosis and interventions for central serous chorioretinopathy: review and update. *Clin Experiment Ophthalmol* 2013;41(2):187-200.
10. Yannuzzi LA. Central serous chorioretinopathy: a personal perspective. *Am J Ophthalmol* 2010;149(3):361-3.
11. Spaide RF, Hall L, Haas A, et al. Indocyanine green videoangiography of older patients with central serous chorioretinopathy. *Retina* 1996;16(3):203-13.
12. Guyer DR, Yannuzzi LA, Slakter JS, et al. Digital indocyanine green videoangiography of central serous chorioretinopathy. *Arch Ophthalmol* 1994;112(8):1057-62.
13. Prunte C, Flammer J. Choroidal capillary and venous congestion in central serous chorioretinopathy. *Am J Ophthalmol* 1996;121(1):26-34.
14. Piccolino FC, Borgia L. Central serous chorioretinopathy and indocyanine green angiography. *Retina* 1994;14(3):231-42.
15. Loo RH, Scott IU, Flynn HW, Jr., et al. Factors associated with reduced visual acuity during long-term follow-up of patients with idiopathic central serous chorioretinopathy. *Retina* 2002;22(1):19-24.
16. Wang MS, Sander B, Larsen M. Retinal atrophy in idiopathic central serous chorioretinopathy. *Am J Ophthalmol* 2002;133(6):787-93.
17. Lai TY, Chan WM, Li H, et al. Safety enhanced photodynamic therapy with half dose verteporfin for chronic central serous chorioretinopathy: a short term pilot study. *Br J Ophthalmol* 2006;90(7):869-74.
18. Nicolo M, Zoli D, Musolino M, Traverso CE. Association between the efficacy of half-dose photodynamic therapy with indocyanine green angiography and optical coherence tomography findings in the treatment of central serous chorioretinopathy. *Am J Ophthalmol* 2012;153(3):474-80 e1.

19. Rouvas A, Stavrakas P, Theodossiadis PG, et al. Long-term results of half-fluence photodynamic therapy for chronic central serous chorioretinopathy. *Eur J Ophthalmol* 2012;22(3):417-22.
20. Valmaggia C, Haueter I, Niederberger H. Photodynamic therapy in the treatment of persistent central serous chorioretinopathy: a two-year follow-up. *Klin Monbl Augenheilkd* 2012;229(4):323-6.
21. Haimovici R, Koh S, Gagnon DR, et al. Risk factors for central serous chorioretinopathy: a case-control study. *Ophthalmology* 2004;111(2):244-9.
22. Yannuzzi LA. Type A behavior and central serous chorioretinopathy. *Trans Am Ophthalmol Soc* 1986;84:799-845.
23. Bouzas EA, Karadimas P, Pournaras CJ. Central serous chorioretinopathy and glucocorticoids. *Surv Ophthalmol* 2002;47(5):431-48.
24. Miki A, Kondo N, Yanagisawa S, et al. Common variants in the complement factor H gene confer genetic susceptibility to central serous chorioretinopathy. *Ophthalmology* 2014;121(5):1067-72.
25. de Jong EK BM, Schellevis RL, Bakker B, Mohr JK, Fauser S, Keunen JEE, Hoyng CB, den Hollander AI & Boon CJF Chronic central serous chorioretinopathy is associated with genetic variants implicated in age-related macular degeneration. *Ophthalmology* 2015;122(3):562-70.
26. Schubert C, Pryds A, Zeng S, et al. Cadherin 5 is regulated by corticosteroids and associated with central serous chorioretinopathy. *Hum Mutat* 2014;35(7):859-67.
27. Tsai DC, Chen SJ, Huang CC, et al. Risk of central serous chorioretinopathy in adults prescribed oral corticosteroids: a population-based study in Taiwan. *Retina* 2014;34(9):1867-74.
28. Tsai MJ, Hsieh YT. Half-time photodynamic therapy for central serous chorioretinopathy. *Optom Vis Sci* 2014;91(9):1140-5.
29. Liu CF, Chen LJ, Tsai SH, et al. Half-dose verteporfin combined with half-fluence photodynamic therapy for chronic central serous chorioretinopathy. *J Ocul Pharmacol Ther* 2014;30(5):400-5.
30. Lim JI, Glassman AR, Aiello LP, et al. Collaborative retrospective macula society study of photodynamic therapy for chronic central serous chorioretinopathy. *Ophthalmology* 2014;121(5):1073-8.
31. Fujita K, Imamura Y, Shinoda K, et al. One-year outcomes with half-dose verteporfin photodynamic therapy for chronic central serous chorioretinopathy. *Ophthalmology* 2015;122(3):555-61.
32. Daruich A, Matet A, Dirani A, et al. Central serous chorioretinopathy: Recent findings and new physiopathology hypothesis. *Prog Retin Eye Res* 2015;48:82-118.
33. Yannuzzi LA, Slakter JS, Gross NE, et al. Indocyanine green angiography-guided photodynamic therapy for treatment of chronic central serous chorioretinopathy: a pilot study. *Retina* 2003;23(3):288-98.
34. Smretschnig E, Ansari-Shahrezaei S, Hagen S, et al. Half-fluence photodynamic therapy in chronic central serous chorioretinopathy. *Retina* 2013;33(2):316-23.
35. Lee TG, Kim JE. Photodynamic therapy for steroid-associated central serous chorioretinopathy. *Br J Ophthalmol* 2011;95(4):518-23.
36. Caccavale A, Romanazzi F, Imperato M, et al. Central serous chorioretinopathy: a pathogenetic model. *Clin Ophthalmol* 2011;5:239-43.

37. Han JM, Hwang JM, Kim JS, et al. Changes in choroidal thickness after systemic administration of high-dose corticosteroids: a pilot study. *Invest Ophthalmol Vis Sci* 2014;55(1):440-5.
38. Schlotzer-Schrehardt U, Viestenz A, Naumann GO, et al. Dose-related structural effects of photodynamic therapy on choroidal and retinal structures of human eyes. *Graefes Arch Clin Exp Ophthalmol* 2002;240(9):748-57.
39. Ma J, Meng N, Xu X, et al. System review and meta-analysis on photodynamic therapy in central serous chorioretinopathy. *Acta Ophthalmol* 2014;92(8):e594-601.
40. Reibaldi M, Cardascia N, Longo A, et al. Standard-fluence versus low-fluence photodynamic therapy in chronic central serous chorioretinopathy: a nonrandomized clinical trial. *Am J Ophthalmol* 2010;149(2):307-15 e2.
41. Aggio FB, Roisman L, Melo GB, et al. Clinical factors related to visual outcome in central serous chorioretinopathy. *Retina* 2010;30(7):1128-34.
42. Colucciello M. Choroidal neovascularization complicating photodynamic therapy for central serous retinopathy. *Retina* 2006;26(2):239-42.
43. Silva RM, Ruiz-Moreno JM, Gomez-Ulla F, et al. Photodynamic therapy for chronic central serous chorioretinopathy: a 4-year follow-up study. *Retina* 2013;33(2):309-15.
44. Chan WM, Lai TY, Lai RY, et al. Safety enhanced photodynamic therapy for chronic central serous chorioretinopathy: one-year results of a prospective study. *Retina* 2008;28(1):85-93.
45. Boni C, Kloos P, Valmaggia C, Department of Ophthalmology CHSGSGS. New guidelines in the treatment of persistent central serous chorioretinopathy: PDT with half-dose verteporfin. *Klin Monbl Augenheilkd* 2012;229(4):327-30.
46. Fung AT, Yannuzzi LA, Freund KB. Type 1 (sub-retinal pigment epithelial) neovascularization in central serous chorioretinopathy masquerading as neovascular age-related macular degeneration. *Retina* 2012;32(9):1829-37.
47. Yang LH, Jonas JB, Wei WB. Conversion of central serous chorioretinopathy to polypoidal choroidal vasculopathy. *Acta Ophthalmol* 2015;93(6):e512-4.





CHAPTER 4.3

The PLACE trial - Comparing half-dose photodynamic therapy (PDT) with high-density subthreshold micropulse laser (HSML) treatment in patients with chronic central serous chorioretinopathy (CSC): study protocol for a randomized controlled trial

Myrte B. Breukink, Susan M. Downes, Giuseppe Querques, Elon H.C. van Dijk, Anneke I. den Hollander, Rocio Blanco-Garavito, Jan. E.E. Keunen, Eric H. Souied, Robert E. MacLaren, Carel B. Hoyng, Sascha Fauser & Camiel J.F. Boon

Published in: *Trials*. 2015;21;16:419

Background and rationale

Chronic central serous chorioretinopathy

Central serous chorioretinopathy (CSC) is a relatively common early-onset eye disease, characterized by an accumulation of leaked serous fluid under the retina, causing a detachment of the neuroretina. This subretinal fluid (SRF) leakage results from dysfunction of the retinal pigment epithelium (RPE), and the presence of choroidal congestion and thickening and hyperpermeability of the choroid, implies an important role for choroidal abnormalities as an underlying cause for RPE dysfunction and SRF leakage in CSC.¹⁻⁴

Two main subtypes of CSC are generally distinguished: acute and chronic CSC.¹⁻⁷ Patients with acute CSC present with sudden and marked central vision loss, because of SRF leakage in the macula due to a focal leak in the RPE that is visible on fluorescein angiography. Acute CSC generally has a favorable prognosis because the SRF often disappears spontaneously within 2-3 months, with either complete or almost complete recovery of vision. In contrast, chronic CSC is typically not self-limiting and SRF persists for more than 3 months. Also, chronic CSC patients present at an older age, with a disease onset that is generally experienced as less sudden, and bilaterality in chronic CSC is common.⁸ A history of acute CSC and/or an episode of acute vision loss compatible with acute CSC is present only rarely in chronic CSC patients,^{2,8} which also points to a distinction between acute and chronic CSC. Patients with the chronic CSC phenotype have more diffuse multifocal leakage on fluorescein and indocyanine green (ICG) angiography, as well as irregularly distributed widespread RPE changes associated with varying degrees of more indistinct leakage on angiography (**Figure 1**). Persistent serous neuroretinal detachments can cause progressive and irreversible photoreceptor damage, resulting in a poorer visual prognosis of chronic CSC as compared to acute CSC.^{2,9,10} The etiology of CSC is largely unknown, but the use of corticosteroids is a risk factor, and possibly elevated cortisol levels, stress, “type A” personality, and pregnancy are also possible risk factors.^{1,11-14} The incidence of CSC is approximately 6 times higher in men than in women,¹ although this male-to-female proportion seems to be less pronounced in chronic CSC and steroid-associated CSC. Recently, single nucleotide polymorphisms in the *Complement Factor H* and *ARMS2* have been found to be associated with chronic CSC.^{15,16}

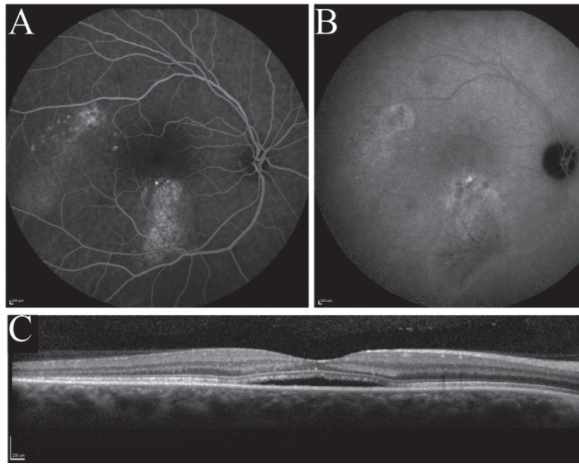


Figure 1

Multimodal imaging in chronic central serous chorioretinopathy. Examples of fluorescein angiography (FA), indocyanine green (ICG) angiography and spectral-domain optical coherence tomography (SD-OCT) in chronic central serous chorioretinopathy (chronic CSC). (A-C) Right eye of a patient with chronic CSC with more widespread leakage on FA (A) corresponding with hyperfluorescent areas on ICG angiography (B) and SRF on SD-OCT (C)

A prolonged neuroretinal detachment in the macula leads to progressive and permanent central visual loss due to photoreceptor atrophy. In addition, Piccolino et al. described the occurrence of not only SRF, but also intraretinal fluid accumulations, posterior cystoid degeneration, in prolonged neuroretinal detachments in severe chronic CSC cases.¹⁷ Nicolo et al. have shown that this posterior cystoid degeneration is associated with a poorer response to photodynamic therapy (PDT),^{17,18} A loss of visual acuity with image distortion, loss of colour and contrast vision may have a significant impact on a patient's personal and professional life. Early diagnosis and treatment is important to try to improve the visual outcome and quality of life, as long-term follow-up studies have shown that the natural course of chronic CSC often results in permanent visual loss.^{3,9,10,19-25} Therefore, several treatment options have emerged in an attempt to accelerate the resolution of SRF accumulation, and to improve the visual outcome in patients with chronic CSC. Treatment within 4 months after the onset of the disease has been advocated by several authors, based on the observation that permanent visual loss may result from prolonged duration of disease.^{2,3} Photoreceptor atrophy in the fovea may occur, even after successful reattachment of the retina, after a duration of symptoms of approximately 4 months.⁹ To date there is no international consensus on the optimal treatment protocol of chronic CSC.

Photodynamic therapy in chronic central serous chorioretinopathy

A number of retrospective studies suggests that in 70-100% of CSC patients treatment with PDT, using the photosensitizing drug verteporfin (Visudyne®), is effective in reducing SRF, with an improvement of retinal anatomy, visual acuity,^{18,26-30} as well as retinal sensitivity.³¹⁻³⁵ PDT treatment has been developed originally as treatment for neovascular age-related macular degeneration, on which there are extensive data available.^{36, 37} There are several other retinal diseases for which PDT with verteporfin is successfully used as an off-label treatment, such as choroidal hemangioma and polypoidal choroidal vasculopathy.³⁷

PDT with Visudyne® (verteporfin for injection) is a two-stage procedure which first requires the intravenous administration of verteporfin, followed by the administration of non-thermal red light into the affected eye. Verteporfin is transported in the plasma primarily by lipoproteins. Once verteporfin is activated by light in the presence of oxygen, highly reactive, short-lived singlet oxygen and reactive oxygen radicals are generated. Verteporfin appears to accumulate preferentially in abnormal neovascularization (which is not present in chronic CSC), but also in the choroidal vasculature. The latter mechanism is of special interest in the treatment of chronic CSC, because CSC primarily affects the choroidal circulation, resulting in multifocal areas of choroidal vascular hyperpermeability that may finally result in the accumulation of SRF. The therapeutic effect of PDT in chronic CSC is thought to result from short-term choriocapillaris hypoperfusion and long-term choroidal vascular remodelling, leading to reduction in choroidal congestion, vascular hyperpermeability, and extravascular leakage.³⁸⁻⁴⁰

As mentioned previously, there is no international consensus on the optimal treatment protocol of chronic CSC. Nevertheless, PDT has emerged as the treatment of choice in many centres worldwide, based on the high rate of anatomic success, the increase of visual acuity, improvement in retinal sensitivity, and an excellent safety profile reported in many retrospective studies.^{3, 41-43} The PDT strategies that are generally used are either with half the dose of verteporfin and full fluency (energy) of laser treatment, half the fluency level and the full dose of verteporfin, or half the treatment time using the full dose of verteporfin and full fluency, as compared to the original protocol that was used for neovascular age-related macular degeneration. These PDT strategies that use either half-dose of half-fluency treatment have been developed because a combination of the dosage and fluency that was originally used for the treatment of neovascular age-related macular degeneration showed a potentially higher risk of developing choroidal ischemia and retinal atrophic changes.^{36, 44-46} The half-dose or half-fluency PDT strategies, however, have been shown to be safe and effective in relatively large retrospective studies and one non-controlled non-randomized prospective study by Chan et al. in chronic CSC patients with sufficient follow-up periods.^{3, 27, 29, 41}

Therefore, tailoring the therapy to obtain the maximal treatment effect with minimal toxicity is essential in treating patients with CSC. By reducing the dose of verteporfin, studies have demonstrated that the potential retinal damage caused by PDT can be minimized while the photodynamic effects in inducing choroidal vasculature changes required for treating CSC remain sufficient.^{2,3,18,26-30,41, 47} None of the patients treated with this half-dose PDT protocol experienced any systemic adverse event (AE) associated with verteporfin infusion.²⁷ In several relatively large retrospective studies on half-dose PDT in CSC, none of the patients had any subjective or objective drop in vision immediately after PDT, nor at subsequent follow-up visits.^{18, 26-30} This “safety-enhanced” protocol with half-dose verteporfin appeared to be one of the safest and effective treatment options in patients with active chronic CSC.^{23,41} In conclusion, a relatively large body of well-documented retrospective studies indicates that half-dose PDT is able to yield positive functional and anatomic outcomes while at the same time reducing the potential AEs associated with conventional PDT with full-dose verteporfin.

High-density subthreshold micropulse laser therapy (HSML) as an alternative treatment in chronic central serous chorioretinopathy

There are several retrospective studies that indicate that HSML therapy may be effective in 41-58% of CSC patients.^{18,48} HSML treatment using a 810 nm wavelength is an established treatment option for a broad range of retinal diseases.⁴⁹ In this treatment, no photosensitizing drug is needed. This relatively new laser treatment modality may prevent damage to the neural retina that occurs in conventional (non-PDT) laser techniques by raising the temperature of the RPE below the protein-denaturation-threshold so that the thermal wave that reaches the neural retina is insufficient to cause neither damage nor a clinically visible end-point (opacified retina). It is different from subthreshold continuous wave in that more energy can be delivered to the RPE without neuroretinal damage using multiple short pulses. In contrast, in the continuous wave mode of conventional laser therapy, the laser energy is delivered with a single pulse with a duration of exposure of 0.1-0.5 s, most of the energy is absorbed by the RPE and the heat energy is transferred to the neurosensory retina leading to transient retinal swelling (visible end-point). As a result, conventional laser application in the macula may cause damage to the neuroretina and RPE, leading to central scotomas and possibly loss of visual acuity. Previous studies have shown that conventional laser treatment in CSC, in contrast to HSML treatment and half-dose PDT treatment, does not improve visual acuity, may cause photoreceptor damage, and may induce choroidal neovascularisation.³ Recently, studies using a relatively new 577 nm wavelength micropulse laser in subthreshold mode have also shown possible efficacy in the treatment of chronic CSC.^{50,51}

Outline of proposed clinical trial

The PLACE study is a superiority study, because retrospective studies suggest that the rate of anatomical and functional success of PDT treatment might be higher than the success of

HSML treatment. Therefore, half-dose PDT treatment arm is challenged against a treatment arm of HSML treatment.

In this study, we want to define treatment success not only on the basis of structural parameters (anatomic success, e.g. absence of SRF after treatment), but also based on functional vision-related endpoints, which are most important from a patient's perspective. These functional vision-related endpoints will include best-corrected visual acuity (BCVA), retinal sensitivity on microperimetry and score on a validated visual function questionnaire (the NEI-VFQ-25 questionnaire).^{52,53}

With the results of this study we hope to establish a strong scientific foundation for further research on the optimal treatment of patients with chronic CSC to improve the visual outcome and quality of life of this relatively frequently occurring eye disease.

Objectives

Primary objective

To investigate whether treatment of chronic CSC patients with macular SRF on optical coherence tomography (OCT) with half-dose PDT results in more eyes with absence of SRF on OCT as compared to HSML treatment.

Secondary objectives

To investigate the clinical outcome comparing half-dose PDT treatment with HSML treatment in patients with SRF due to active leakage in chronic CSC, based on evaluation of BCVA, retinal sensitivity on microperimetry, and subjective success score on the NEI-VFQ-25 questionnaire.

Methods/Design

Summary of trial design

This study is a multicenter, prospective, randomized, controlled, open-label study that will compare the efficacy and safety of two treatments in patients with chronic CSC. The first group of patients will receive half-dose PDT treatment. The second group of patients will receive 810 nm HSML treatment. Each patient will receive at least one treatment, but may be eligible to receive a second treatment during follow-up (**Figure 2**), which will be the same type of treatment as the first treatment: either half-dose PDT treatment or HSML treatment.

Potential eligible patients will be identified in one of five specialist ophthalmology trial sites, each led by one of the principal investigators (PIs).

Fundus photographs, fluorescein angiograms, ICG angiograms and OCT images collected at the screening visit will be sent to a central reading center (CRC). The CRC will review these images to confirm subject eligibility based on the characteristics specified in the inclusion and exclusion criteria. Once eligibility has been confirmed by the CRC, all other inclusion and exclusion criteria have been met at the baseline visit, and informed consent has been obtained, patients will be enrolled in the trial.

There are nine examinations that will be performed at the baseline assessment, 6-8 weeks after treatment (at evaluation visit 1, and - if applicable, if a second treatment is required - at evaluation visit 2), and at the final visit (7-8 months after start of the treatment). The 6 *anatomical* assessments include ophthalmoscopy, fundus photography, OCT, autofluorescence imaging, fluorescein angiography, and ICG angiography. The 3 *functional* assessments include visual acuity measurement, microperimetry, and a questionnaire on vision-related functioning.

Enrolled patients will be randomized at a 1:1 ratio to receive either half-dose PDT treatment or HSML treatment.

The total number of visits per patient is 5 (in case of 1 required treatment) or 7 (in case of 2 required treatments). The duration of participant participation within the study is 7-8 months (**Figure 2**).

Overview of assessments in the trial:

1. Ophthalmoscopy

This examination will be performed by one of the ophthalmologists to confirm the diagnosis. To perform ophthalmoscopy the pupils will have to be dilated with 1.0% tropicamide and 2. % phenylephrine.

2. Fundus photography

The fundus photography will be taken with a Topcon TRC-50 series fundus camera. The photographs will be taken with a 50°-field centred on the area of the macula.

3. Optical coherence tomography (OCT) imaging

Patients will be examined by non-invasive OCT imaging. OCT shows the different layers of the retina and is the imaging modality of choice to visualize subretinal and intraretinal fluid, for instance in chronic CSC. This examination is performed in mydriasis (dilated pupils). OCT imaging will be carried out with a Spectralis HRA+OCT (Heidelberg Engineering, Heidelberg, Germany).

4. Fundus autofluorescence imaging

Fundus autofluorescence is a non-invasive imaging technique that is able to register changes of autofluorescence intensity in the retina, for instance due to accumulation of lipofuscin in the RPE. Fundus autofluorescence imaging will be carried out with a Spectralis HRA+OCT (Heidelberg Engineering, Heidelberg, Germany).

5 & 6. Fluorescein and indocyanine green (ICG) angiography

To perform fluorescein and ICG angiography, intravenous injection of fluorescein and ICG is required. During the angiography procedure, both (fluorescein and ICG) dyes may be injected at the same time or separately. Fluorescein reveals the retinal vasculature and may show areas of fluid leakage through the RPE, whereas the ICG dye images the choroidal vasculature. The visualization of both the retinal vasculature and RPE permeability (by fluorescein angiography) and choroidal vasculature (by ICG angiography) is essential to image the areas of abnormal anatomy and leakage that may guide treatment. Images of the study eye are taken at set times: 0-1 minutes (several images covering the arterial and venous filling phases), 3 minutes, 6 minutes, 10 minutes, 15 minutes, and 20 minutes. Images of the non-study eye will be taken at 1 minute, 6 minutes, and 20 minutes. All images will be acquired with Spectralis HRA+OCT (Heidelberg Engineering, Heidelberg, Germany).

7. *Best-corrected visual acuity (BCVA)*

BCVA will be assessed for both eyes at all evaluation visits. To measure BCVA, early treatment diabetic retinopathy study (ETDRS) visual acuity testing charts will be used at a distance of 4 meters.

8. *Microperimetry*

All patients will be examined by non-invasive microperimetry. This technique is able to measure retinal sensitivity to light, and follow-up pre- and post-treatment changes in retinal sensitivity at predetermined loci in the macula. By using a reliable eye tracking system, this microperimetry system is able to exactly locate the areas of retina that have been tested previously, in order to ensure testing of identically the same area at follow-up. Microperimetry according to a standard protocol take 5-8 minutes for each eye, and will be performed with non-dilated pupils.

9. *Questionnaires*

Each participant will be asked to complete a quality of life questionnaire based on national eye institute visual function questionnaire (NEI-VFQ-25),⁵³ and the Cohen stress questionnaire.^{52,54} NEI-VFQ-25 is a reliable and validated 25-item version of the 51-item national eye institute visual function questionnaire.⁵⁵ The questionnaire is especially useful in settings such as clinical trials, where interview length is an important consideration. The Cohen stress questionnaire is a validated questionnaire indicating the stress level patients have been exposed to during the month before disease onset.

There will be standard operating procedures (SOPs) available to all investigators involved in the trial as well as in the trial master file for each of the described examinations.

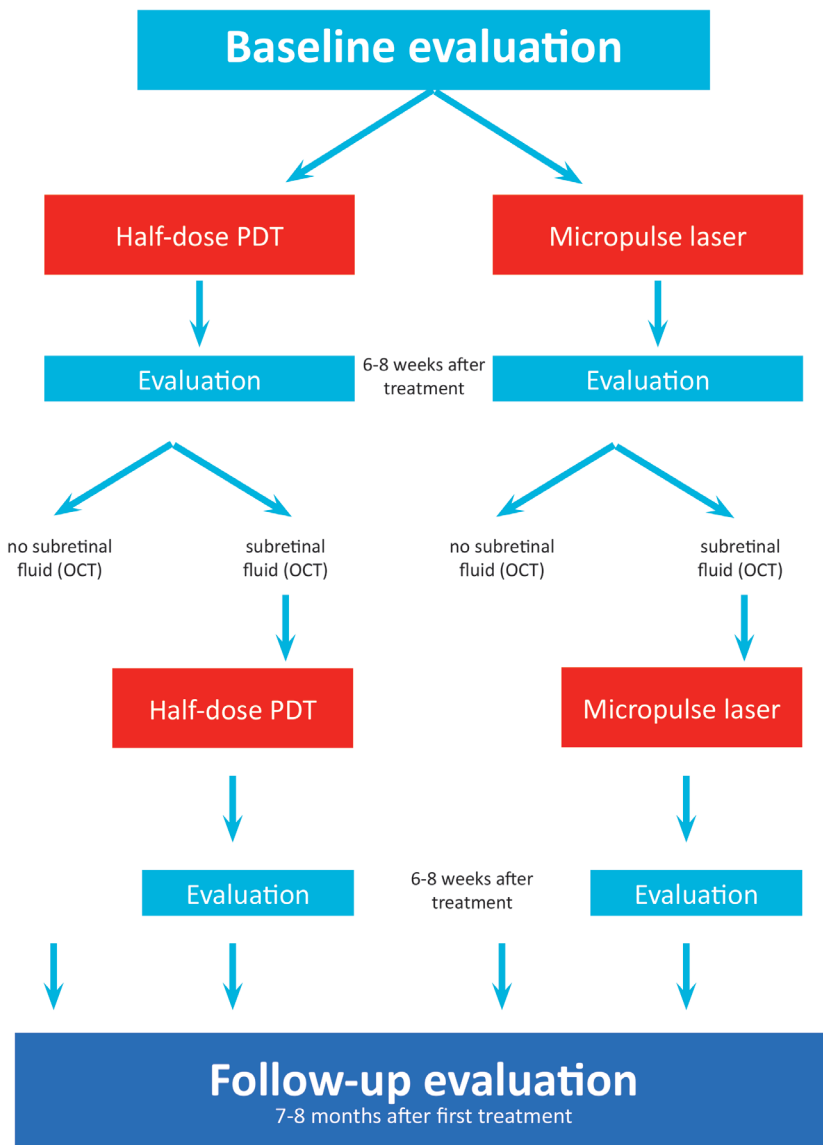


Figure 2.
Study flow chart

Primary and secondary endpoints

Primary endpoint

The primary endpoint of this study is to assess if there is a difference between the efficacy of half-dose PDT treatment versus HSML treatment in patients with chronic CSC. The assessment of this efficacy will be based on the anatomical effect on OCT: absence of SRF versus persistent SRF, 6-8 weeks after treatment. After all, the absence or presence of fluid under the retina on the OCT scan is a direct reflection of the activity of the disease in these patients.

Secondary endpoints

As secondary endpoints, we will mainly look at 3 parameters that reflect the patient's vision-related functioning. These three parameters are: a standardized measurement of BCVA according to the ETDRS standards, a standardized measurement of sensitivity of the macula with microperimetry, and standardized assessment of the patient's vision-related quality of life using a validated questionnaire, the NEI-VFQ-25.

The secondary endpoints that will be assessed as a reflection of functional improvement after treatment include:

- Number of second treatments needed in each treatment arm
- Mean change from baseline in ETDRS BCVA in the study eye at 6-8 weeks after treatment visit 1 and at 7-8 months after treatment visit 1, among the two treatment modalities
- Mean change from evaluation visit 1 in ETDRS BCVA in the study eye at final evaluation (7-8 months after treatment visit 1), among those who required one treatment and those who required a second treatment, and among the two treatment modalities overall
- Mean change from baseline in retinal sensitivity on microperimetry in the study eye at 6-8 weeks after treatment visit 1 and at 7-8 months after treatment visit 1 among the two treatment modalities
- Mean change from baseline in the NEI-VFQ-25 questionnaire at 6-8 weeks after treatment visit 1 and at 7-8 months after treatment visit 1 among the two treatment modalities
- An absence of SRF on evaluation with OCT scanning as compared to HSML treatment at 7-8 months follow-up after successful treatment (after treatment visit 1; "success" defined as an absence of SRF on OCT at 6-8 weeks after treatment)

Trial participants

Overall description of trial participants

This study will enrol subjects with chronic CSC with active leakage of fluid under the retina as evidenced on OCT scanning and further supported by findings on fluorescein angiography and ICG angiography, in at least one eye. If both eyes are eligible, then the eye with the longer duration of disease will be used as the study eye, except in cases where the disease is present for more than 18 months. In the latter case, which is an exclusion criterion, the other eye will be eligible for inclusion if the disease is active for less than 18 months. If the non-study eye also has active disease, the choice to treat and the type of treatment in this eye may be chosen freely at the discretion of the responsible ophthalmologist.

Before enrolment, each subject must meet all of the following inclusion criteria and none of the exclusion criteria, and agree to comply with the study requirements including completion of all of the study visits.

Inclusion criteria

- Male and female patients ≥ 18 years of age who are able to give written informed consent
- Active chronic CSC
- Subjective visual loss > 6 weeks, interpreted as onset of active disease
- SRF that includes the fovea on OCT scanning at baseline examination.
Note: SRF does not have to include fovea on OCT to be eligible for treatment at control visit 1, as long as there is persistent SRF in the macula, which is interpreted as persistently active disease.
- Hyperfluorescent areas on ICG angiography
- ≥ 1 ill-defined hyperfluorescent leakage areas on fluorescein angiography with RPE window defect(s) that are compatible with chronic CSC

Exclusion criteria

The participant may not enter the study if any of the following apply:

- Any previous treatments for active CSC in the study eye
- Current treatment with corticosteroids (topical or systemic), corticosteroid use within 3 months before possible start of trial treatment, or anticipated start of corticosteroid treatment within the first 7-8 months from the start of the trial period
- Evidence of other diagnosis that can explain serous SRF or visual loss
- BCVA < 20/200 (Snellen equivalent)
- Profound chorioretinal atrophy in central macular area on ophthalmoscopy and OCT
- Myopia > 6D
- Visual loss and/or serous detachment on OCT < 6 weeks
- Continuous and/or progressive visual loss > 18 months or serous detachment on OCT > 18 months
- No hyperfluorescence on ICG angiography
- Intraretinal edema on OCT
- (relative) contraindications for PDT treatment (pregnancy, porphyria, severely disturbed liver function). Pregnancy will not be routinely tested in female patients, but the possibility of pregnancy will be discussed during eligibility screening
- (relative) Contraindications for fluorescein angiography or ICG angiography (known allergies especially against shellfish, previous reactions)
- Soft drusen in treated eye or fellow eye, signs of choroidal neovascularization on ophthalmoscopy and/or fluorescein angiography/ICG angiography

Study procedures

Screening and eligibility assessment

Identification of potential participants

Potential participants with chronic CSC will be identified in the participating trial sites, after being referred to the department by the general practitioner (GP) or referring ophthalmologists from other hospitals. Before screening, a visual acuity measurement, dilated ophthalmoscopy, fundus photography, OCT of the retina and choroid, autofluorescence imaging, and fluorescein and ICG angiography will already have been performed in most patients as part of standard clinical care. These examinations constitute most of the baseline examinations, and therefore do not have to be repeated if screening and randomisation is performed within 2 weeks after these examinations. Screening and baseline examinations/enrolment are performed on the same day if possible. The maximum duration allowed between screening and randomisation is 2 weeks.

In addition to the examinations mentioned previously, the following information will be collected from patients who have been consented, at the baseline assessment, at control visit 1 and - if applicable - control visit 2, and at the follow-up visit at 7-8 months after treatment visit 1.

- Demographic details: the date of birth, gender, race, smoking and drinking habits will be recorded on case report forms (CRFs).
- Medical history: details of any history of disease or surgical interventions will be recorded on CRFs.
- Concomitant medication: all over-the-counter or prescribed medication, vitamins, and/or herbal supplements will be recorded on CRFs.

Informed consent

The study will be discussed with the subject. The patient information sheet will be given to the patient at the screening visit, and the patient will be asked to contact us if he/she is willing to take part. A subject wishing to participate must give written informed consent prior to any study-related procedures or change in treatment. The participant must personally sign and date the latest approved version of the informed consent form before any study-specific procedures are performed. Written and verbal versions of the participant information and informed consent will be presented to the participants, detailing the exact nature of the study, the implications and constraints of the protocol, the known side effects, and any risks involved in taking part. It will be clearly stated that the participant is free to withdraw from the study at any time for any reason without prejudice to future care, and with no obligation to give the reason for withdrawal.

The participant will be allowed as much time as wished to consider the information, and the opportunity to question the investigator, their GP or other independent parties to decide whether they will participate in the study. Written informed consent will then be obtained by means of participant dated signature and dated signature of the person who presented and obtained the informed consent. The person who obtained the consent must be suitably qualified and experienced, and have been authorised to do so by the chief/principal investigator. A copy of the signed informed consent will be given to the participants. The original signed form will be retained at the study site, and an additional copy will remain in the patient notes.

Randomisation

Subject numbers will be assigned sequentially as each subject enters the study.

The subjects will be assigned study treatment by a web based random numbers generator using block randomisation without minimization. This application will be specially designed for this study by the Department of Epidemiology, Biostatistics and Health Technology Assessment of the Radboud University Nijmegen Medical Center (Nijmegen, the Netherlands). Randomisation will be performed at the same visit as the baseline visit. The randomisation schedule is designed by a statistician, and the randomisation codes are kept in the CRF and in the digital database of the Clinical Research Center Nijmegen (www.CRCN.nl).

Interventions

Half-dose PDT treatment

For this intervention the patients need dilated pupils (with 1.0% tropicamide and 2.5% phenylephrine). All patients will get an intravenous infusion of 3 mg/m² verteporfin (Visudyne®) (half-dose) is over 10 minutes. At exactly 15 minutes after the start of the infusion, an anaesthetic eye drop is given (oxybuprocaine 0.4% or equivalent), a contact lens (a Volk® PDT lens) is positioned on the affected eye, and the aiming beam of the laser is focused on the treatment area. The magnification factor is taken into account in the settings of the PDT machine. The area of treatment is chosen, with the area of the aiming beam corresponding to the area of the subsequent laser spot area. The area that has to be treated is determined based on those hyperfluorescent area(s) on mid-phase (approximately 10 minutes) ICG angiography that correspond(s) to SRF accumulation in the macula on the OCT scan and hyperfluorescent “hot spots” on the mid-phase (approximately 3 minutes) fluorescein angiogram. The spot size will be defined based on the diameter of the hyperfluorescent area on ICG angiography plus 1mm (**Figure 3**). The edge of treatment spot has to be *at least 200 µm away from the optic disc rim*. The PDT treatment is performed with standard 50 J/cm² fluency, a PDT laser wavelength of 689 nm, and a standard treatment duration of 83 seconds. Care must be taken to treat at *exactly* 15 minutes after the start of the infusion, to maximize the localization of the effect of treatment to the choroid and minimize possible

damage to the adjacent retinal structures. The PDT treatment must take place at least 45 minutes after ICG angiography has been performed.

HSML treatment

For this intervention the patients need dilated pupils (with 1.0% tropicamide and 2.5% phenylephrine). An anaesthetic eye drop is given (oxybuprocaine 0.4% or equivalent), and a contact glass (for instance a Volk® area centralis lens) is positioned on the affected eye. HSML treatment with an 810 nm diode laser will be performed of the areas identified on mid-phase ICG angiography. Multiple confluent, adjacent (non-overlapping) laser spots will be applied, covering the leakage area on mid-phase ICG angiography. The number of spots and number of zones treated depends on the extent of the leakage area(s) on mid-phase ICG. The area that has to be treated is determined based on those hyperfluorescent area(s) on mid-phase (approximately 10 minutes) ICG angiography that correspond(s) to SRF accumulation in the macula on the OCT scan and hyperfluorescent “hot spots” on the mid-phase (3 minutes) fluorescein angiogram (**Figure 3**). The treatment will consist of small adjacent laser spots covering the designated area *keeping a distance of 500 µm from the foveal centre (corresponding to a laser-free circular zone of 1000 µm diameter centred on the fovea)*.

The following HSML treatment settings will be used: a power of 1800 mW*, a duty cycle of 5%, frequency of 500 Hz, exposure time of 0.2 s per spot, a spot size of 125 µm, with a minimal distance of the spot from the fovea of 500 µm.^{48,56}

* Subthreshold treatment is desired, meaning that no visible reaction due to laser treatment has to be seen in the retina. In virtually all patients, a power of 1800 mW will not produce a visible discoloration of the retina after application of a laser spot with the aforementioned settings. If retinal discoloration is seen at a power of 1800 mW (corresponding to suprathreshold treatment), for instance in patients with darkly pigmented fundi, the power will be reduced with steps of 300 mW until there is no visible reaction. The first laser “test” spot will always be applied just outside the macular area.

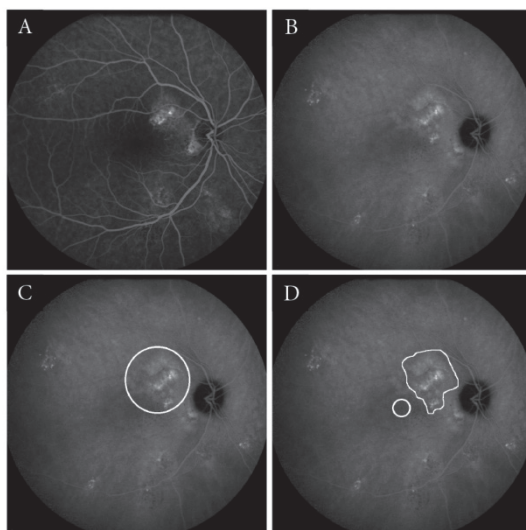


Figure 3.

Examples of areas treated in photodynamic therapy and micropulse laser treatment. Examples of imaging features on fluorescein angiography (FA) and indocyanine green angiography (ICG) angiography in chronic central serous chorioretinopathy (chronic CSC), and the corresponding treatment areas for photodynamic therapy (PDT) and high-density subthreshold micropulse laser treatment (HSML). **A-B** FA of the right eye of a patient showing hyperfluorescent “hot spots,” indicating leakage inferior of the fovea (**A**). On ICG angiography, an area of hyperfluorescence, which corresponds to the hyperfluorescent area on the FA, is seen (**B**). **C-F** An example of a PDT spot (white circle) overlapping the hyperfluorescent area on the ICG angiography plus 1 mm as described in the protocol (**C**). HSML treatment scheme that would apply to the same eye, in which only the central foveal area is excluded for treatment (white circle). The hyperfluorescent area on the ICGA is treated with numerous, nonoverlapping adjacent laser spots (white area) (**D**)

Retreatment criteria and considerations

At evaluation visit 1, at 6-8 weeks after treatment visit 1, an OCT scan of the retina will be performed, among other imaging examinations. If there still is SRF present in the macular area, a second treatment according to the protocol will be performed within 3 weeks after this evaluation visit 1.

This second treatment (either half-dose PDT or HSML treatment) will again be guided by the hyperfluorescent area(s) on ICG angiography that correspond(s) to SRF accumulation in the macula on the OCT scan and hyperfluorescent “hot spots” on the mid-phase (approximately 3 minutes) fluorescein angiogram.

In cases where there is no more SRF under the fovea but there is persistent fluid within the macular area encircled by the optic disc and temporal retinal vascular arcade, retreatment will be performed. The rationale behind this second treatment is that the persistent fluid may be interpreted as an incomplete treatment response, because SRF accumulation indicates ongoing disease activity due to choroidal vascular hyperpermeability and fluid leakage through the RPE.

Note: if a patient did not require retreatment at evaluation visit 1 (= 6-8 weeks after treatment visit 1) according to the protocol, but returns with visual symptoms in the period between evaluation visit 1 and the follow-up visit at 7-8 months, a regular clinical examination should be performed that includes at least a measurement of visual acuity, ophthalmoscopy, and OCT scan to determine whether SRF has reoccurred. If there is evidence of recurrence of SRF on OCT (and therefore disease activity), these findings should be noted in the CRF. In these cases, additional evaluations compatible with evaluation visit 2 should be performed, and the patient should be planned for treatment visit 2 (max. 2-3 weeks after evaluation visit 2). Further considerations adhere to the retreatment criteria described above.

However, no treatment is allowed if the patient has already been treated twice (either with two half-dose PDT treatments or two HSML treatments) according to the trial protocol between evaluation visit 1/2 and follow-up visit (7-8 months after treatment visit 1). There are no data on the usefulness of more than 2 half-dose PDT treatments in the same patient with persistent chronic CSC. Some authors argue that more than 2 PDT treatments in the same eye may increase the risk of complications such as choroidal ischemia and the formation of choroidal neovascularization. In the case of HSML treatment, there also are no reports to suggest that more than 2 treatments may be useful. That is why a maximum amount of two of the same treatments is allowed within the trial period. After completion of the trial (at follow-up visit, 7-8 months after treatment visit 1), treatment may be considered and the treatment modality may be chosen at the discretion of the treating ophthalmologist.

Definition of end of trial

The end of trial is the date on which the last included participant has received the last follow-up visit (7-8 months after treatment 1).

Discontinuation and withdrawal of participants from study treatment

Each participant has the right to withdraw from the study at any time. In addition, the investigator may discontinue a participant from the study at any time if the investigator considers it necessary for any reason including:

- Ineligibility (either arising during the study or retrospective having been overlooked at screening)
- Significant protocol deviation
- Significant non-compliance with study requirements
- An AE which requires discontinuation of the study medication or results in inability to continue to comply with study procedures
- Consent withdrawn
- Lost to follow-up

- Pregnancy before evaluation visit 1 or 2 (which is a relative contraindication for angiography). Pregnancy will not be routinely tested in female patients, but the possibility of pregnancy will be discussed during eligibility screening.

Patients suffering from a vision-threatening AE will also be withdrawn from the study. Withdrawal from the study will result in exclusion of the data from analysis from those participants, except if adherence to the protocol and follow-up examinations were sufficient to allow inclusion in the analysis. The reason for withdrawal will be recorded in the CRF.

If the participant is withdrawn due to an AE, the investigator will make arrangements for follow-up visits or telephone calls until the AE has resolved or stabilised.

Sample size calculations showed the need of 78 participants per treating arm to find significant values. In case of a withdrawal a replacing subject will be included. This could cause a delay of the end of the trial but is not relevant for the outcomes. All subjects withdrawn from this study will return to normal consultation at their ophthalmologist of choice.

Safety reporting

Adverse event reporting period

The reporting period during which AEs must be reported is the period from enrolment to the end of the study period (24 months). All unresolved AEs must be followed by the trial monitor in contact with the chief investigator and principal investigators until the events are resolved, the patient is lost to follow-up, or the AE is otherwise explained. At the last scheduled study visit, the trial nurse will instruct each patient to report any subsequent event(s) that the patient, or the patient's personal physician, believes might reasonably be related to prior study treatment. Such events should be reported to the (previous) treating ophthalmologist at the department of ophthalmology of the trial site after the trial has ended. Patients who withdraw early from the study will be contacted by trial staff 30 days after their last visit, if the patient gives permission to do so, to ascertain whether any AEs have occurred.

Definition of adverse events/reactions

An *adverse event (AE)* or adverse experience is:

Any untoward medical occurrence in a patient or clinical investigation participants administered a medicinal product, which does not necessarily have to have a causal relationship with this treatment (the study medication).

An AE can therefore be any unfavourable and unintended sign (including an abnormal laboratory finding), symptom or disease temporally associated with the use of the study medication, whether or not considered related to the study medication.

In the case of an *adverse reaction (AR)*, a causal relationship between a study medication and an AE is at least a reasonable possibility, i.e., the relationship cannot be ruled out.

All cases judged by either the reporting medically qualified professional or the sponsor as having a reasonable suspected causal relationship to the study medication qualify as adverse reactions.

All untoward and unintended responses to a medicinal product related to any dose.

ARs could include for instance: nausea, hypertension, lower back pain, headache, arthralgia, intravenous injection site reactions (in the case of PDT), cough, pharyngitis, pneumonia, fever and flu-like symptoms, hypersensitivity and allergy reactions, vaso-vagal reactions, atrial fibrillation, angina, and sunburn after sunlight exposure in the first two days after PDT treatment.

Procedures for recording adverse events/reactions

All AEs occurring during the study observed by the investigator or reported by the participant, whether or not attributed to study medication, will be recorded on the CRF. The following information will be recorded: description, date of onset and end date, severity, assessment of relatedness to study medication, other suspect drug or device and action taken. Follow-up information should be provided as necessary. AEs considered related to the study medication as judged by a medically qualified investigator or the sponsor will be followed until resolution or the event is considered stable. AEs considered related to the study procedure as judged by a qualified investigator or the sponsor will be followed until resolution or the event is considered stable. All related AEs that result in a participant's withdrawal from the study or are present at the end of the study, should be followed up if the patient gives consent to do so, until a satisfactory resolution occurs.

It will be left to the investigator's clinical judgment whether or not an AE is of sufficient severity to require the participant's removal from the trial. A participant may also voluntarily withdraw from treatment due to what he or she perceives as an intolerable AE. If either of these occurs, the participant must undergo an end of study assessment and be given appropriate care under medical supervision until symptoms cease or the condition becomes stable.

The relationship of AEs to the study medication will be assessed by a medically qualified investigator and if necessary discussed with the chief investigator. Any pregnancy occurring during the clinical study and the outcome of the pregnancy fathered by trial participants, should be recorded and followed up for congenital abnormality or birth defect.

Definitions of serious adverse events/reactions

A *serious adverse event (SAE)* is any untoward medical occurrence that at any dose:

- Results in death,
- Is life-threatening, note: the term "life-threatening" in the definition of "serious" refers to an event in which the participant was at risk of death at the time of the event; it does not refer to an event which hypothetically might have caused death if it were more severe.
- Requires inpatient hospitalisation or prolongation of existing hospitalisation,
- Results in persistent or significant disability/incapacity, or is a congenital anomaly/birth defect.
- Other important medical events. Note: other events that may not result in death, are not life threatening, or do not require hospitalisation, may be considered a SAE when, based upon appropriate medical judgement, the event may jeopardise the patient and may require medical or surgical intervention to prevent one of the outcomes listed above. In this trial, these events are mainly vision-related.

Vision-threatening adverse events/reactions

An AE is considered to be vision-threatening and is a reportable SAE if it meets one or more of the following criteria:

- It caused a decrease in visual acuity of >30 letters (compared with the last assessment of visual acuity prior to the most recent treatment) within the follow-up period of 7-8 months.
- It required surgical intervention
- In the investigator's opinion, it may require medical intervention to prevent permanent loss of vision. Causes for such vision-related AEs could include for instance: RPE tears, subretinal haemorrhage, choroidal neovascularization.

A *serious adverse reaction (SAR)* is an adverse event (expected or unexpected) that is both serious and, in the opinion of the reporting investigator, believed with reasonable probability to be due to one of the study treatments, based on the information provided.

A *suspected unexpected serious adverse reaction (SUSAR)* is a serious adverse reaction, the nature or severity of which is not consistent with the applicable product information (e.g. Investigator's brochure for an unapproved investigational product or summary of product characteristics for an approved product).

Reporting procedures for serious adverse events

The data monitoring committee (DMC) will undertake to review all SAEs for the study. The DMC may hold electronic meetings. The DMC will meet at intervals and consider:

- Occurrence and nature of adverse events
- Whether additional information on adverse events is required
- Consider taking appropriate action where necessary to halt trials
- Act / advise on incidents occurring between meetings that require rapid assessment (e.g. SUSARs)

All SAEs will be reported to the DMC within one working day of discovery or notification of the event. All SAE information will be recorded on an SAE form, which will be sent electronically to members of the DMC. Additional information received for a case (follow-up or corrections to the original case) will be detailed on a new SAE form. After receiving the SAE report within one working day, the medical monitor will review possible SAEs weekly, and the DMC has a meeting every 3 months to review the SAEs, if present. The chief investigator will also report all SUSARs to the competent authorities (TOL / CCMO in the Netherlands, Bfarm in Germany, and ANSM (Agence Nationale de Sécurité du Médicament et des Produits de Santé) in France, the ethics committees concerned, and the host NHS trust in the UK. Fatal or life-threatening SUSARs will be reported within 7 days and all other SUSARs within 15 days. The chief investigator will also inform all investigators concerned of relevant information about SUSARs that could adversely affect the safety of participants.

Trial safety group / data monitoring committee

The DMC will conduct a review of all SAEs for the study reported every 3 months and cumulatively, if present. The aims of this review include:

- To pick up any trends, such as increases in unexpected/expected events, and take appropriate action
- To seek additional advice or information from investigators where required
- To evaluate the risk of the trial continuing and take appropriate action where necessary
- To act or advise, through the chairman or other medical monitors, on incidents occurring between meetings that require rapid assessment

This committee, which is based in the coordinating centre in Nijmegen, will receive SAEs within one working day, and will analyse the available safety data and study data in a meeting every 3 months, if present.

Statistics

Description of statistical methods

Univariate analysis:

Analysis for the primary endpoint

The purpose of this study is to identify the difference between the efficacy of the two treatment modalities based on the anatomical effect on OCT scan (absence of SRF versus still SRF visible). As we expect one treatment to be superior to the other, this study is designed to be a superiority study. Statistical analysis on the primary parameter will be performed by analyzing the relative risk by using a cross-table comparing evaluation at 6-8 weeks after treatment with baseline.

Multivariate analysis:

Analysis for the secondary endpoints

For the secondary endpoints, the following analyses will be performed:

- Compare anatomic results based on OCT scan (absence of SRF versus persistent SRF) at evaluation point 1 compared to baseline
- Number of subsequent treatments needed in each treatment arm
- Compare mean change from baseline in ETDRS BCVA in the study eye at 6-8 weeks after treatment and at the end evaluation, among the two treatment modalities.
- Compare mean change from evaluation point 1 in ETDRS BCVA in the study eye at final evaluation among those with subsequent and those without subsequent treatment among the two treatment modalities
- Compare mean change from baseline in retinal sensitivity in the study eye at 6-8 weeks after treatment among the two treatment modalities.
- Compare mean change from baseline in the NEI-VFQ-25 questionnaire at 6-8 weeks after treatment among the two treatment modalities.

The first two analyses will be performed by the use of a cross-table. Furthermore, the continuous secondary variables will be analyzed using an ANCOVA model with baseline as and treatment as factor. For categorical secondary endpoints, a chi-square test will be performed. In addition a logistic model with baseline as covariate and treatment as factor will be performed. The change from baseline in the NEI-VFQ-25 questionnaire results will be summarized descriptively.

Interim analysis

A formal interim analysis will be performed when 78 participants received the first evaluation 6-8 weeks after treatment. Statistical analysis on the primary parameter will be performed by analyzing the relative risk by using a cross-table comparing evaluation at 6-8 weeks after treatment with baseline.

Number of participants

Total number of patients: 156 patients (see table “distribution of subjects per site”)

Justification of sample size:

For HSML, an anatomic success rate of approximately 50%, defined as no SRF on OCT, after 6-8 weeks may be estimated based on retrospective studies.^{48,57} For half-dose PDT approximately 80% anatomic success may be estimated.^{18,26-35} taking such a difference of 30% in treatment success into account, a power calculation indicates that one would need 40 patients per treatment arm (power: 80%, α : 0.05). However, when we also correct for factors such as positive publication bias and our own empiric treatment experience, we expect to find a difference in treatment success rate of approximately 22% in favour of half-dose PDT. If we take one interim analysis into account according to the O’Brien-Fleming method, 78 patients per treatment arm would be required (power: 80%, α : 0.05).

Distribution of subjects per site

	Netherlands (Nijmegen/Leiden)	Oxford (UK)/ Cologne (Germany)/Paris (France)
Group 1*	50 subjects	28 subjects
Group 2*	50 subjects	28 subjects

*group 1 (78 patients): half-dose PDT with Visudyne®

*group 2 (78 patients): HSML

The level of statistical significance

For the primary endpoint, the overall null hypothesis is:

H_0 : probabilities of success are the same in both treatment arms ($\pi_1 = \pi_2$)

versus

H_1 : probabilities of success are different in the treatment arms ($\pi_1 \neq \pi_2$)

For statistical testing the significance level will be 0.05 unless specified otherwise.

Criteria for the termination of the trial.

The DMC will perform a review of the study data every 3 months. The study may be terminated prematurely on the recommendation of the DMC. Reasons for premature termination of the trial may include:

- Early solid statistical evidence that the investigational medicinal product (IMP) is significantly better than the comparator.
- Early evidence that one or both treatments are harmful.

*Ethics**Declaration of Helsinki*

The chief investigator will ensure that this study is conducted in accordance with the principles of the 2008 declaration of Helsinki.

ICH guidelines for good clinical practice

The investigator will ensure that this study is conducted in full conformity with relevant regulations and with the ICH guidelines for good clinical practice (CPMP/ICH/135/95) July 1996.

Approvals

The protocol, informed consent form, participant information sheet, and any proposed advertising material was submitted and written approval was obtained at the appropriate research ethics committees (REC) (see list below), regulatory authorities, and host institution(s). This trial has been internationally registered at Clinicaltrials.gov (NCT01797861; <http://clinicaltrials.gov/>). List of research ethical committees that have approved the study protocol at the different sites:

1. Commissie Mensgebonden Onderzoek (CMO) Regio Arnhem-Nijmegen approved the protocol for;
 - Radboud University Medical Center, Nijmegen, the Netherlands
 - Leiden University Medical Center, Leiden, the Netherlands

2. Ethik Kommission Universität zu Köln approved the protocol for:
 - University Hospital Cologne, Cologne, Germany

3. Health Research Authority National Research Ethics Service (NRES) Committee South Central – Oxford A approved the protocol for:
 - Oxford Eye Hospital, Oxford, United Kingdom

4. Comité de Protection des Personnes Ile de France V approved the protocol for:
 - University Paris Est Creteil, Paris, France

Discussion

To establish the optimal treatment for chronic CSC, a eye disease associated with potentially severe visual disability, a multicenter prospective randomized controlled trial is mandatory but currently lacking. The proposed study is the first multicenter prospective randomized controlled trial that compares half-dose PDT with HSML treatment with regard to their ability to reduce SRF accumulation in chronic CSC, and their ability to improve the quality of vision. We have chosen for half-dose PDT treatment instead of half-fluency PDT treatment, a reduction of the dose of verteporfin rather than the fluency of the laser treatment appears preferable because dose reduction may reduce possible systemic side effects of PDT treatment, such as lower back pain and photosensitivity of the skin in the first days after treatment,⁵⁸ while having an efficacy comparable to half-fluency PDT.^{59,60}

HSML treatment has been chosen as the treatment of choice in the control arm for a number of reasons. First, sham (no treatment) was studied by Chan and co-workers in the acute form of CSC, who showed a large difference in anatomic and functional outcome (complete resolution of SRF) between the half-dose PDT and placebo group.⁶¹ As it is well-established that prolonged leakage of SRF under the macula due to chronic CSC may lead to permanent visual loss, it is not desirable to include comparison with sham in our study.^{8-10,20,25,61-66} HSML treatment of CSC has been shown to be effective and safe in 41-58% of patients in smaller, retrospective studies.^{18,48,57} The safety and efficacy of HSML treatment has also been reported in various other retinal diseases.⁴⁹ In contrast, it has been shown that conventional laser treatment of focal leakage point on fluorescein angiography in CSC does not result in a better visual outcome.^{3,41} Also, conventional laser treatment in CSC has a higher risk of complications than HSML and half-dose PDT, including vision loss, scotoma, decreased color vision, decreased contrast sensitivity, and choroidal neovascularisation.^{2,41,67} The 810 nm HSML laser modality was chosen instead of the 577 nm wavelength, because at the time of the start of the study relatively little had been published on the safety and efficacy of 577 nm HSML, and experimental studies between 810 nm and 532 nm micropulse laser strategies have not shown obvious differences in histological effect.⁶⁸

References

1. Liew G, Quin G, Gillies M, Fraser-Bell S. Central serous chorioretinopathy: a review of epidemiology and pathophysiology. *Clin Experiment Ophthalmol*. 2013;41(2):201-14.
2. Wang M, Munch IC, Hasler PW, Prunte C, Larsen M. Central serous chorioretinopathy. *Acta Ophthalmol*. 2008;86(2):126-45.
3. Gemenetzi M, De Salvo G, Lotery AJ. Central serous chorioretinopathy: an update on pathogenesis and treatment. *Eye (Lond)*. 2010;24(12):1743-56.
4. Nicholson B, Noble J, Forooghian F, Meyerle C. Central serous chorioretinopathy: update on pathophysiology and treatment. *Surv Ophthalmol*. 2013;58(2):103-26. doi:10.1016/j.survophthal.2012.07.004.
5. von Winning CH, Oosterhuis JA, Renger-van Dijk AH, Hornstra-Limburg H, Polak BC. Diffuse retinal pigment epitheliopathy. *Ophthalmologica* 1982;185(1):7-14.
6. Polak BC, Baarsma GS, Snyers B. Diffuse retinal pigment epitheliopathy complicating systemic corticosteroid treatment. *Br J Ophthalmol*. 1995;79(10):922-5.
7. Spaide RF, Hall L, Haas A, Campeas L, Yannuzzi LA, Fisher YL et al. Indocyanine green videoangiography of older patients with central serous chorioretinopathy. *Retina*. 1996;16(3):203-13.
8. Spaide RF, Campeas L, Haas A, Yannuzzi LA, Fisher YL, Guyer DR et al. Central serous chorioretinopathy in younger and older adults. *Ophthalmology*. 1996;103(12):2070-9; discussion 9-80.
9. Wang MS, Sander B, Larsen M. Retinal atrophy in idiopathic central serous chorioretinopathy. *Am J Ophthalmol*. 2002;133(6):787-93.
10. Loo RH, Scott IU, Flynn HW, Jr., Gass JD, Murray TG, Lewis ML et al. Factors associated with reduced visual acuity during long-term follow-up of patients with idiopathic central serous chorioretinopathy. *Retina*. 2002;22(1):19-24.
11. Yannuzzi LA. Central serous chorioretinopathy: a personal perspective. *Am J Ophthalmol*. 2010;149(3):361-3.
12. Bouzas EA, Karadimas P, Pournaras CJ. Central serous chorioretinopathy and glucocorticoids. *Surv Ophthalmol*. 2002;47(5):431-48.
13. Tsai DC, Chen SJ, Huang CC, Chou P, Chung CM, Chan WL et al. Risk of central serous chorioretinopathy in adults prescribed oral corticosteroids: a population-based study in Taiwan. *Retina*. 2014;34(9):1867-74.
14. Conrad R, Geiser F, Kleiman A, Zur B, Karpawitz-Godt A. Temperament and character personality profile and illness-related stress in central serous chorioretinopathy. *ScientificWorldJournal*. 2014;2014:631687.
15. de Jong EK BM, Schellevis RL, Bakker B, Mohr JK, Fauser S, Keunen JEE, Hoyng CB, den Hollander AI & Boon CJF Chronic central serous chorioretinopathy is associated with genetic variants implicated in age-related macular degeneration. *Ophthalmology*. 2015;122(3):562-70.
16. Miki A, Kondo N, Yanagisawa S, Bessho H, Honda S, Negi A. Common variants in the complement factor H gene confer genetic susceptibility to central serous chorioretinopathy. *Ophthalmology*. 2014;121(5):1067-72.


17. Piccolino FC, De La Longrais RR, Manea M, Cicinelli S. Posterior cystoid retinal degeneration in central serous chorioretinopathy. *Retina*. 2008;28(7):1008-12.
18. Nicolo M, Zoli D, Musolino M, Traverso CE. Association between the efficacy of half-dose photodynamic therapy with indocyanine green angiography and optical coherence tomography findings in the treatment of central serous chorioretinopathy. *Am J Ophthalmol*. 2012;153(3):474-80 e1.
19. Levine R, Brucker AJ, Robinson F. Long-term follow-up of idiopathic central serous chorioretinopathy by fluorescein angiography. *Ophthalmology*. 1989;96(6):854-9.
20. Bujarborua D. Long-term follow-up of idiopathic central serous chorioretinopathy without laser. *Acta Ophthalmol Scand*. 2001;79(4):417-21.
21. Wong R, Chopdar A, Brown M. Five to 15 year follow-up of resolved idiopathic central serous chorioretinopathy. *Eye (Lond)*. 2004;18(3):262-8.
22. Gilbert CM, Owens SL, Smith PD, Fine SL. Long-term follow-up of central serous chorioretinopathy. *Br J Ophthalmol*. 1984;68(11):815-20.
23. Stewart JM. Half dose verteporfin PDT for central serous chorioretinopathy. *Br J Ophthalmol*. 2006;90(7):805-6.
24. Brancato R, Scialdone A, Pece A, Coscas G, Binaghi M. Eight-year follow-up of central serous chorioretinopathy with and without laser treatment. *Graefes Arch Clin Exp Ophthalmol*. 1987;225(3):166-8.
25. Otsuka S, Ohba N, Nakao K. A long-term follow-up study of severe variant of central serous chorioretinopathy. *Retina*. 2002;22(1):25-32.
26. Lai TY, Chan WM, Li H, Lai RY, Liu DT, Lam DS. Safety enhanced photodynamic therapy with half dose verteporfin for chronic central serous chorioretinopathy: a short term pilot study. *Br J Ophthalmol*. 2006;90(7):869-74.
27. Chan WM, Lai TY, Lai RY, Tang EW, Liu DT, Lam DS. Safety enhanced photodynamic therapy for chronic central serous chorioretinopathy: one-year results of a prospective study. *Retina*. 2008;28(1):85-93.
28. Valmaggia C, Haueter I, Niederberger H. Photodynamic therapy in the treatment of persistent central serous chorioretinopathy: a two-year follow-up. *Klin Monbl Augenheilkd*. 2012;229(4):323-6.
29. Rouvas A, Stavarakas P, Theodossiadis PG, Stamatou P, Milia M, Giannakaki E et al. Long-term results of half-fluence photodynamic therapy for chronic central serous chorioretinopathy. *Eur J Ophthalmol*. 2012;22(3):417-22.
30. Jirattanasopa P, Ooto S, Tsujikawa A, Yamashiro K, Hangai M, Hirata M et al. Assessment of macular choroidal thickness by optical coherence tomography and angiographic changes in central serous chorioretinopathy. *Ophthalmology*. 2012;119(8):1666-78.
31. Senturk F, Karacorlu M, Ozdemir H, Karacorlu SA, Uysal O. Microperimetric changes after photodynamic therapy for central serous chorioretinopathy. *Am J Ophthalmol*. 2011;151(2):303-9 e1.
32. Fujita K, Shinoda K, Imamura Y, Matsumoto CS, Mizutani Y, Mizota A et al. Correlation of integrity of cone outer segment tips line with retinal sensitivity after half-dose photodynamic therapy for chronic central serous chorioretinopathy. *Am J Ophthalmol*. 2012;154(3):579-85.

33. Fujita K, Yuzawa M, Mori R. Retinal sensitivity after photodynamic therapy with half-dose verteporfin for chronic central serous chorioretinopathy: short-term results. *Retina*. 2011;31(4):772-8.
34. Boni C, Kloos P, Valmaggia C, Department of Ophthalmology CHSGSGS. New guidelines in the treatment of persistent central serous chorioretinopathy: PDT with half-dose verteporfin. *Klin Monbl Augenheilkd*. 2012;229(4):327-30.
35. Wu ZH, Lai RY, Yip YW, Chan WM, Lam DS, Lai TY. Improvement in multifocal electroretinography after half-dose verteporfin photodynamic therapy for central serous chorioretinopathy: a randomized placebo-controlled trial. *Retina*. 2011;31(7):1378-86.
36. Photodynamic therapy of subfoveal choroidal neovascularization in age-related macular degeneration with verteporfin: one-year results of 2 randomized clinical trials--TAP report. Treatment of age-related macular degeneration with photodynamic therapy (TAP) Study Group. *Arch Ophthalmol*. 1999;117(10):1329-45.
37. Chan WM, Lim TH, Pece A, Silva R, Yoshimura N. Verteporfin PDT for non-standard indications--a review of current literature. *Graefes Arch Clin Exp Ophthalmol*. 2010;248(5):613-26.
38. Chan WM, Lam DS, Lai TY, Tam BS, Liu DT, Chan CK. Choroidal vascular remodelling in central serous chorioretinopathy after indocyanine green guided photodynamic therapy with verteporfin: a novel treatment at the primary disease level. *Br J Ophthalmol*. 2003;87(12):1453-8.
39. Schlotzer-Schrehardt U, Viestenz A, Naumann GO, Laqua H, Michels S, Schmidt-Erfurth U. Dose-related structural effects of photodynamic therapy on choroidal and retinal structures of human eyes. *Graefes Arch Clin Exp Ophthalmol*. 2002;240(9):748-57. .
40. Schmidt-Erfurth U, Laqua H, Schlotzer-Schrehard U, Viestenz A, Naumann GO. Histopathological changes following photodynamic therapy in human eyes. *Arch Ophthalmol*. 2002;120(6):835-44.
41. Quin G, Liew G, Ho IV, Gillies M, Fraser-Bell S. Diagnosis and interventions for central serous chorioretinopathy: review and update. *Clin Experiment Ophthalmol*. 2013;41(2):187-200.
42. Vasconcelos H, Marques I, Santos AR, Melo P, Pires I, Figueira J et al. Long-term chorioretinal changes after photodynamic therapy for chronic central serous chorioretinopathy. *Graefes Arch Clin Exp Ophthalmol*. 2013;251(7):1697-705.
43. Lim JI, Glassman AR, Aiello LP, Chakravarthy U, Flaxel CJ, Spaide RF et al. Collaborative retrospective macula society study of photodynamic therapy for chronic central serous chorioretinopathy. *Ophthalmology*. 2014;121(5):1073-8.
44. Lai TY, Chan WM, Lam DS. Transient reduction in retinal function revealed by multifocal electroretinogram after photodynamic therapy. *Am J Ophthalmol*. 2004;137(5):826-33.
45. Lee PY, Kim KS, Lee WK. Severe choroidal ischemia following photodynamic therapy for pigment epithelial detachment and chronic central serous chorioretinopathy. *Jpn J Ophthalmol*. 2009;53(1):52-6. .
46. Tzekov R, Lin T, Zhang KM, Jackson B, Oyejide A, Orilla W et al. Ocular changes after photodynamic therapy. *Invest Ophthalmol Vis Sci*. 2006;47(1):377-85.
47. Maruko I, Iida T, Sugano Y, Ojima A, Ogasawara M, Spaide RF. Subfoveal choroidal thickness after treatment of central serous chorioretinopathy. *Ophthalmology*. 2010;117(9):1792-9.

48. Lanzetta P, Furlan F, Morgante L, Veritti D, Bandello F. Nonvisible subthreshold micropulse diode laser (810 nm) treatment of central serous chorioretinopathy. A pilot study. *Eur J Ophthalmol.* 2008;18(6):934-40.
49. Sivaprasad S, Elagouz M, McHugh D, Shona O, Dorin G. Micropulsed diode laser therapy: evolution and clinical applications. *Surv Ophthalmol.* 2010;55(6):516-30.
50. Yadav NK, Jayadev C, Mohan A, Vijayan P, Battu R, Dabir S et al. Subthreshold micropulse yellow laser (577 nm) in chronic central serous chorioretinopathy: safety profile and treatment outcome. *Eye (Lond).* 2015;29(2):258-65.
51. Lavinsky D, Palanker D. Nondamaging photothermal therapy for the retina: initial clinical experience with chronic central serous retinopathy. *Retina.* 2015;35(2):213-22.
52. <http://www.centervue.com/product.php?id=639>.
53. Mangione CM, Lee PP, Gutierrez PR, Spritzer K, Berry S, Hays RD et al. Development of the 25-item National Eye Institute Visual Function Questionnaire. *Arch Ophthalmol.* 2001;119(7):1050-8.
54. Cohen S, Kamarck T, Mermelstein R. A global measure of perceived stress. *J Health Soc Behav.* 1983;24(4):385-96.
55. Finger RP, Fleckenstein M, Holz FG, Scholl HP. Quality of life in age-related macular degeneration: a review of available vision-specific psychometric tools. *Qual Life Res.* 2008;17(4):559-74.
56. Gupta B, Elagouz M, McHugh D, Chong V, Sivaprasad S. Micropulse diode laser photocoagulation for central serous chorio-retinopathy. *Clin Experiment Ophthalmol.* 2009;37(8):801-5.
57. Chen SN, Hwang JF, Tseng LF, Lin CJ. Subthreshold diode micropulse photocoagulation for the treatment of chronic central serous chorioretinopathy with juxtafoveal leakage. *Ophthalmology.* 2008;115(12):2229-34.
58. Schnurrbusch UE, Jochmann C, Einbock W, Wolf S. Complications after photodynamic therapy. *Arch Ophthalmol.* 2005;123(10):1347-50.
59. Nicolo M, Eandi CM, Alovisi C, Grignolo FM, Traverso CE, Musetti D et al. Half-fluence versus half-dose photodynamic therapy in chronic central serous chorioretinopathy. *Am J Ophthalmol.* 2014;157(5):1033-7.
60. Kim YK, Ryoo NK, Woo SJ, Park KH. Comparison of visual and anatomical outcomes of half-fluence and half-dose photodynamic therapy in eyes with chronic central serous chorioretinopathy. *Graefes Arch Clin Exp Ophthalmol.* 2015.
61. Chan WM, Lai TY, Lai RY, Liu DT, Lam DS. Half-dose verteporfin photodynamic therapy for acute central serous chorioretinopathy: one-year results of a randomized controlled trial. *Ophthalmology.* 2008;115(10):1756-65.
62. Kanyange ML, De Laey JJ. Long-term follow-up of central serous chorioretinopathy (CSCR). *Bulletin de la Societe belge d'ophtalmologie.* 2002(284):39-44.
63. Ladas ID, Rouvas AA, Apostolopoulos M, Brouzas D, Karagiannis DA, Georgalas I et al. Diffuse retinal pigment epitheliopathy: treatment with laser photocoagulation. *Eur J Ophthalmol.* 2004;14(4):315-20.
64. Levecq L, Hoebeke M, Guagnini AP, Snyers B. [Diffuse retinal epitheliopathy: study of 30 eyes]. *Bulletin de la Societe belge d'ophtalmologie.* 2003(288):55-62.

65. Yannuzzi LA, Slakter JS, Kaufman SR, Gupta K. Laser treatment of diffuse retinal pigment epitheliopathy. *Eur J Ophthalmol.* 1992;2(3):103-14.
66. Piccolino FC, de la Longrais RR, Ravera G, Eandi CM, Ventre L, Abdollahi A et al. The foveal photoreceptor layer and visual acuity loss in central serous chorioretinopathy. *Am J Ophthalmol.* 2005;139(1):87-99. doi:10.1016/j.ajo.2004.08.037.
67. Yap EY, Robertson DM. The long-term outcome of central serous chorioretinopathy. *Arch Ophthalmol.* 1996;114(6):689-92.
68. Yu AK, Merrill KD, Truong SN, Forward KM, Morse LS, Telander DG. The comparative histologic effects of subthreshold 532- and 810-nm diode micropulse laser on the retina. *Invest Ophthalmol Vis Sci.* 2013;54(3):2216-24.





CHAPTER 4.4

The use of eplerenone in therapy-resistant chronic central serous chorioretinopathy.

Myrte B. Breukink, Anneke I. den Hollander, Jan E.E. Keunen, Camiel J.F. Boon & Carel B. Hoyng

Published in: *Acta Ophthalmology*. 2014;92(6):e488-90

An inappropriate activation of the mineralocorticoid receptor, found in the vasculature (endothelial and smooth muscle cells), has been recently suggested to underlie the pathogenesis of CSC.^{1,2} This study also suggested a reduction of subretinal fluid (SRF) in 2 patients by systemic use of eplerenone, a selective mineralocorticoid receptor antagonist, implying that eplerenone could even be a promising alternative treatment.

Here we report the treatment outcome with oral eplerenone in 5 patients suffering from chronic CSC, who experienced persistent SRF on spectral-domain optical coherence tomography (OCT) for at least 9 months, and responded insufficiently to previous treatments.

Oral administration of eplerenone 25 mg/day was started at baseline. At the start of week 2, eplerenone was increased to 50 mg/day, and completely stopped at the end of week 5, according to the previously described protocol.¹

A fixed follow-up protocol was used with visits scheduled at baseline, 1 week, 3 weeks, 5 weeks and a final examination after 10 weeks.

The five patients (3 males) had a mean age of 55 years (range 41–64 years), and two patients had bilateral active chronic CSC. None of the patients had a history of steroid use.

A full reduction of SRF on OCT was seen in patient 1 (**Figure 1A**). In this patient, there was only a minor increase in visual acuity (VA), which is most likely the result of the prolonged detachment of the neurosensory retina, causing irreversible damage to the photoreceptors.⁴ Patient 2 initially had a decrease of SRF but then relapsed after cessation of the eplerenone-treatment (**Figure 1B**). Patient 3 showed a decrease of subfoveal SRF, but showed an increase of SRF inferior of the fovea (**Figure 1C**). Patient 4 had no change in SRF, nor a clear effect on VA (**Figure 1D**). Patient 5 had bilateral active disease, in which one eye first had a decrease of SRF which then returned to baseline-level, whereas an increase of SRF occurred in the other eye (**Figure 1E**).

The use of eplerenone did not influence the hyperfluorescent pattern, typical for chronic CSC, seen in all patients on fluorescein angiography and indocyanine green angiography. None of the patients showed a change in subfoveal choroidal thickness on enhanced-depth-imaging-OCT during the course of the study, and systemic parameters remained within normal range in all patients.

Curative therapeutic options for chronic CSR are scarce and the current leading options consist of PDT, conventional laser treatment, and micropulse laser treatment, with anatomical success rates ranging from 60 up to 100%.⁵ A lack of response to these treatment modalities is not uncommon. Zhao and colleagues described that an overstimulation of

the mineralocorticoid receptor in a rat model caused dilation of the choroidal vasculature and choroidal thickening,¹ similar to clinical observations in chronic CSC. The same group recently presented promising results in 13 patients with CSC, showing a full reduction of SRF in 25% of the patients at 1 month and 67% at 3 months after use of eplerenone.⁵

However, the current pilot study indicates that eplerenone has a beneficial effect only in a minority of patients with long-standing treatment-resistant chronic CSC. The precise role of an inappropriate activation of the mineralocorticoid receptor in chronic CSC, therefore, remains controversial.

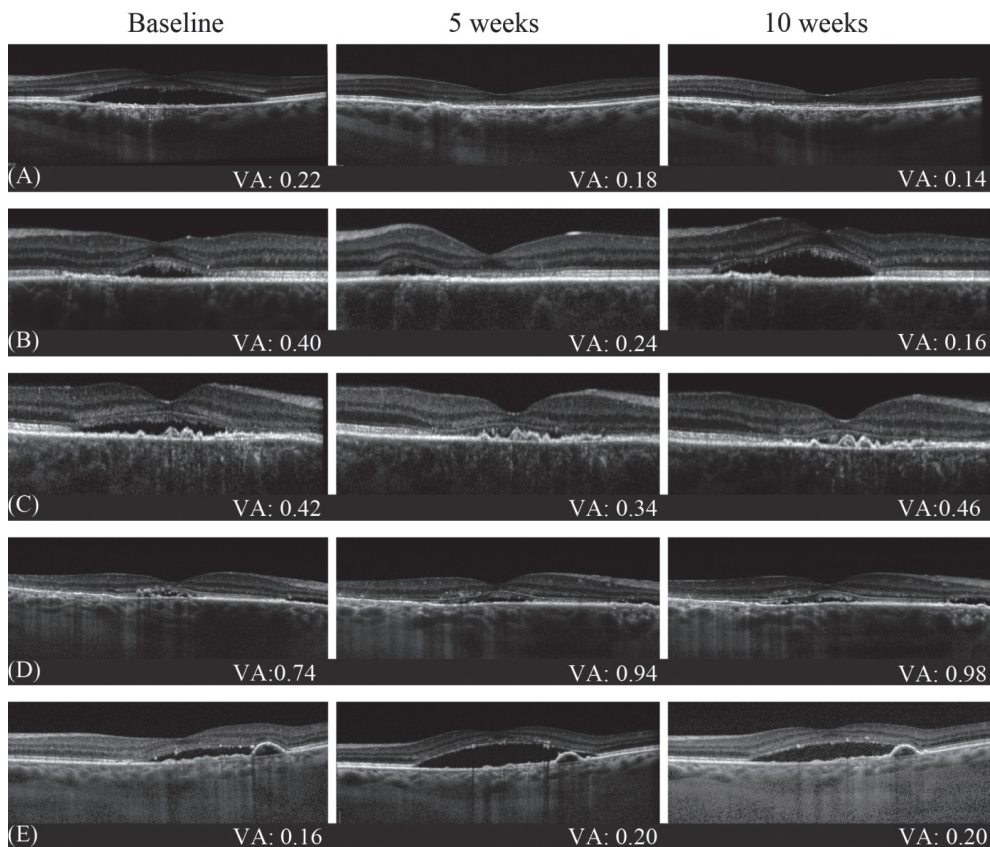




Figure 1.

Enhanced depth optical coherence tomography (OCT) imaging of the most illustrative eye and corresponding visual acuity (VA) (logMAR) of the five patients. **(A)** The left eye of patient 1 demonstrated a complete reduction of subretinal fluid (SRF) at 5 weeks, which was maintained after 10 weeks and accompanied by a slight increase in VA. **(B)** The left eye of patient 2 with central SRF at baseline showed a reduction of SRF at week 5, an increase above baseline at week 10 (after stopping eplerenone), and an increase in VA. **(C)** The right eye of patient 3 showed an almost complete reduction in subfoveal SRF, which appeared stable over time, the VA was also stable. **(D)** In patient 4, the SRF remained unchanged at follow-up, with a mild decline in VA. **(E)** The left eye of patient 5 showed an increase in SRF at 5 and 10 weeks as compared with baseline, accompanied by a decrease in VA. In all patients, the choroidal thickness did not show a significant change over time.

References

1. Zhao M, Celerier I, Bousquet E, et al. Mineralocorticoid receptor is involved in rat and human ocular chorioretinopathy. *J Clin Invest* 2012;122(7):2672-9.
2. Daruich A, Matet A, Dirani A, et al. Central serous chorioretinopathy: Recent findings and new physiopathology hypothesis. *Prog Retin Eye Res* 2015;48:82-118
3. Wang MS, Sander B, Larsen M. Retinal atrophy in idiopathic central serous chorioretinopathy. *Am J Ophthalmol* 2002;133(6):787-93.
4. Quin G, Liew G, Ho IV, et al. Diagnosis and interventions for central serous chorioretinopathy: review and update. *Clin Experiment Ophthalmol* 2013;41(2):187-200.
5. Bousquet E, Beydoun T, Zhao M, et al. Mineralocorticoid receptor antagonism in the treatment of chronic central serous chorioretinopathy: a pilot study. *Retina* 2013;33(10):2096-102.





CHAPTER 5

General discussion

General discussion

Many studies on chronic central serous chorioretinopathy (CSC) have been undertaken in the past decades. However, the precise pathogenesis and the optimal therapeutic approach for patients with CSC still remain largely obscure. The main purpose of this thesis was to investigate and assess whether genetic factors play a role in chronic CSC, to delineate the clinical characteristics and prognosis, and to analyse possible treatment options in chronic CSC. In this general discussion the major findings of this thesis are reviewed and placed into a broader perspective, evaluating the clinical relevance and future implications.

5.1 Epidemiology of chronic central serous chorioretinopathy

With a reported incidence of at least 9.9 cases per 100.000 men and 1.7 per 100.000 women,¹ CSC is considered the fourth most common macular disease.² The higher male to female ratio is more evident in the acute form as compared to the chronic form, but still strikingly present in chronic CSC. Also, the mean age at presentation appears to be higher in chronic CSC patients.³ There is limited information about the precise incidence of CSC among different ethnic groups. Tsai et al. reported a incidence of 21 cases per 100.000 men, and 15 cases per 100.000 women in a Taiwanese population,⁴ which is consistent with the suspected higher frequency in Asians as compared to other ethnic groups. In addition, some studies suggest an increased frequency among Caucasians and Hispanics as compared to African Americans.^{3, 5} These findings suggest variations of the CSC incidence among various ethnic groups.^{3, 5} Also, acute CSC with bilateral and multifocal leakage is reported more frequently in the Asian population than in other ethnic groups.^{3, 6}

Risk factors

Chronic CSC is a multifactorial disease. Although the precise pathogenesis is uncertain, several risk factors have been described in association with CSC. The most commonly reported risk factors include the male gender and the use of corticosteroids.^{3, 7}

Thus far it is unclear why the incidence of CSC is much higher in men. An explanation may lie in the hormonal differences between men and women. Higher levels of testosterone are present in men as compared to women.⁸ A decline in the levels of testosterone in males is seen in the advanced adulthood.⁸ Vice versa, a small increase of the testosterone levels occurs in the female population after entering the menopause.⁹ Interestingly, these changes appear to be in line with the differences in age at onset between the genders: male CSC patients tend to be younger at onset than female CSC patients.³ Besides the differences in testosterone levels between the genders, higher levels of testosterone have been reported in individuals with type A personality,¹⁰ an additional risk factor associated with CSC (**Table 1, Chapter 1**). A person with a type A personality exhibits a simple preponderance of the following personality traits; a competitive drive, a sense of urgency, an aggressive nature,

and a hostile temperament.¹¹ Also, androgen receptors and messenger RNA for 5-alpha-reductase, the enzyme responsible for the conversion of testosterone to the more potent dihydrotestosterone, are found in the human retinal pigment epithelium (RPE).¹² This, and recent studies suggesting a positive effect of the use of 5-alpha reductase inhibitors in CSC patients,¹³ support the thought of a possible involvement of testosterone as a risk factor to develop CSC.

Not only testosterone is an interesting candidate to be of influence in the pathogenesis of CSC. Endogenous as well as exogenous steroids are also strongly associated with CSC. For example, CSC has been described in patients with Cushing's disease, a disorder that is characterized by hypercortisolism.¹⁴⁻¹⁸ Also, the use of corticosteroids via various application forms has been reported to be a major risk factor of CSC, with reported odd ratios up to 37.1 to develop CSC when using corticosteroids.^{7, 19-22}

Theoretically, one may expect to find increased levels of testosterone and/or cortisol in patients suffering from CSC. However, the relatively small studies that have been conducted on this subject thus far show indifferent results. Where 24h urine samples have shown elevated cortisol levels in chronic CSC patients,^{23, 24} these results were not observed in single serum measurements during set times.^{25, 26} These discrepancies could be explained by hormonal fluctuations between individuals during the day. In addition, testosterone levels appear to be within the normal range in patients with chronic CSC.²⁵ Although no clear change in serum levels of testosterone and/or cortisol has been found, it is possible that more acute changes, rather than a chronic elevation, influence and trigger the underlying disease mechanism. This may explain the patients that present with separate attacks either provoked by episodes of corticosteroid therapy or periods of stress. It is also possible that chronic CSC patients are more sensitive and have an impaired response at the level of the choroid and/or RPE to normal serum levels of cortisol and/or testosterone.

5.2 Clinical presentation

In general, two forms of CSC can be identified: acute CSC and chronic CSC. This distinction is often based on the period of time during which subretinal fluid (SRF) is present. In the case of long-standing SRF accumulation, the nomenclature changes from acute to chronic. In this definition, no consensus exists about the duration of the presence of the SRF accumulation that differentiates acute from chronic CSC.^{2, 27, 28} Arbitrarily, this period is set somewhere between 3 and 6 months in most publications.³ The second method of differentiation between acute and chronic CSC, which was also used in this thesis, is based on the presence and extent of anatomical changes on multimodal imaging including optical coherence tomography (OCT), fundus autofluorescence (FAF), fluorescein angiography (FA), and indocyanine green angiography (ICGA). Acute CSC is characterized by a focal leakage spot on FA, beneath a macular neurosensory retinal detachment.^{2, 28, 29} This so called 'hot spot' indicates leakage at the level of the RPE.^{5, 27, 28} Chronic CSC shows more

diffuse RPE changes, with single or multifocal areas of leakage on FA and ICGA.^{2, 27, 28} In chronic CSC, the SRF on OCT is often more shallow as compared to acute CSC, in addition the SRF tends to persist, although it can wax and wane multiple times.^{30, 31} Additionally, ICGA characteristically demonstrates widespread hyperfluorescent areas of choroidal congestion and hyperpermeability which are more extensive in chronic CSC than in acute CSC.^{2, 28, 32-34} However, debate exists about the accuracy of the differentiation into acute and chronic CSC, and some argue that these represent two separate disease entities. It is unclear if uncomplicated acute CSC can eventually evolve into chronic CSC with diffuse RPE changes. Support for this connection is found in case reports and case series.^{3, 35} Larger studies are necessary to evaluate both CSC entities and possible their possible association. Despite the fact that a certain overlap exists in clinical presentation, the prognosis and clinical course appear to differ considerably.

Most patients with the acute form of CSC generally recover spontaneously and tend to have a good visual prognosis.^{3, 36, 37} In contrast, we have shown that chronic CSC is generally a progressive chorioretinopathy with a negative impact on the visual outcome (**Chapter 3.1**). The progressive nature of chronic CSC is also reflected on multimodal imaging. A gradually progressive decrease in central foveal thickness was seen on optical coherence tomography (OCT). Also, on follow-up the FA often showed an increase of hyperfluorescent atrophic RPE changes and an increased number of hot spots of leakage in many patients. Our data show a marked decrease in reported vision-related quality of life in this chronic CSC cohort when compared to healthy individuals (**Chapter 3.1**).

Chronic CSC typically presents with SRF on OCT, with areas of leakage on FA and ICGA. Multimodal imaging using these diagnostic tools has enabled a faster and more accurate diagnosis. However, a striking resemblance in phenotype may exist between chronic CSC and other retinal diseases, such as neovascular age-related macular degeneration (AMD) (**Chapter 1**). Establishing the right diagnosis is important to provide patients with an accurate prognosis and an optimal treatment if required. Re-evaluation of the initial imaging at inclusion is important in patients who developed an obvious choroidal neovascularization (CNV) at follow-up in one of our studies, showed lesions suggestive for a very early stage of CNV that may have already been present and slumbering at the time of first examination (**Chapter 4.1**). Clinical characteristics that were in retrospect suggestive of small, early CNV were a shallow RPE detachment, more diffuse (instead of focal hot spot) leakage on FA, and a hyperfluorescent branching network on ICGA. In contrast to chronic CSC, which is treated with half-dose PDT, CNV is primarily treated with anti-VEGF injections.³⁸ Therefore, in case of non-response to treatment, the physician should always reconsider the diagnosis, whether it is CNV simulating chronic CSC or vice versa.

The imaging methods FA and ICGA provide dynamic 2-dimensional information about the retinal and choroidal vasculature, the OCT is able to provide 3-dimensional information. The non-invasive character of OCT as compared to FA and ICGA is a big advantage of this

technique. However, OCT, FA, and ICGA visualize different aspects of the disease and are thus complementary in the clinical assessment of CSC. For instance, FA can show the extent of RPE changes and the number of hot spots of leakage through a dysfunctional RPE outer blood-retinal barrier.³⁹ ICGA is able to visualize choroidal changes such as diffuse choroidal hyperfluorescent leakage that is typical of chronic CSC.^{28, 32, 40} These choroidal changes on ICGA correlate with choroidal thickening and other abnormalities on enhanced depth OCT imaging.⁴¹⁻⁴⁴ In addition, FA and ICGA can better visualize lesions suspect for CNV and/or polypoidal choroidal vasculopathy (PCV).

In chronic CSC, OCT is mainly used to monitor the SRF accumulation. Interestingly, multimodal imaging characteristics are not only pivotal to establish a correct diagnosis, but may also be of prognostic value, for instance with regard to the likelihood of response to treatment. Differences in the optical density ratio of the SRF accumulation in serous neuroretinal detachment were recently demonstrated to be a valuable tool to differentiate chronic CSC from PCV, again two entities that may be strikingly similar and may have partly overlapping pathophysiology.⁴⁵⁻⁴⁷ In longstanding serous neuroretinal detachments, subretinal hyperreflective material on SD-OCT in chronic CSC can appear and may become increasingly prominent.⁴⁸ In **Chapter 3.2**, we used a semi-automated OCT analysis technique to show that differences in these OCT characteristics seem to be present between patients who respond well to half-dose PDT treatment, and patients who have a poor response to half-dose PDT treatment. The skewedness, a measure for the symmetry of the histogram of pixel intensity values, showed a trend to be higher in patients who responded better to half-dose PDT as compared to patients who had poor response to PDT treatment. The median pixel intensity of the SRF accumulation was lower in the group with complete absence of SRF after treatment. Subretinal debris, such as accumulation of shed photoreceptor outer segments that are less efficiently phagocytised by a dysfunctional RPE, gives rise to a higher pixel intensity in OCT. Our findings suggest that chronic CSC patients with a higher pixel intensity in the SRF on OCT are less likely to achieve complete SRF resolution after half-dose PDT. A possible explanation may be that the higher intensity is a reflection of longstanding and more inactive disease that may be less sensitive to treatment.

Besides retinal OCT scanning, we investigated the novel OCT-based application of OCT angiography (OCTA), also known as split-spectrum amplitude decorrelation angiography. This technique detects movements of blood cells in the retinal and choroidal vessels, and is thus able to visualize retinal and choroidal vasculature and neovascular changes non-invasively.⁴⁹ OCTA enables the visualization of the inner plexus of retinal vessels, which is also seen in the early phase of FA. Additionally, OCTA can visualize the deeper retinal plexus because specific vascular layers can be selected in the depth resolved OCT volume and because the presence of overlying vessels does not mask the underlying vessels.⁵⁰ It therefore complements the current diagnostic methods, and can be of use in the differentiation between small CNV and/or PCV, that can present with a typical branching vascular network on OCTA, and chronic

CSC in which no neovascular network is present. Also, OCTA offers the opportunity to non-invasively expand our knowledge of the physiology of the retina in health and disease. We showed that OCTA is also able demonstrate typical changes in the choriocapillary flow pattern, showing choriocapillary hypoperfusion and hyperperfusion of the area in CSC that corresponded to areas affected by SRF accumulation, which was not always clearly visible using the invasive techniques of FA and ICGA (**Chapter 3.3**). This is consistent with results of earlier studies using FA, ICGA and conventional OCT, showing focal filling defects in the choriocapillaris with dilated and tortuous feeding arterioles and dilated venules.^{10, 28-30} Areas of irregular choriocapillary texture on OCTA partially co-located to areas with late staining on ICGA. Hot spots of choroidal hyperpermeability and leakage visible on ICGA were in close proximity to abnormalities interpreted as relative choriocapillary ischemia on OCTA. These results suggest that focal choriocapillary ischemia with surrounding hyperperfusion may lead to SRF leakage in chronic CSC. This is an interesting finding, supporting one of the suggested hypotheses on CSC pathophysiological mechanisms: in this hypothesis, it is postulated that due to choroidal/choriocapillary vasoconstriction and capillary occlusion, a reduction in vascular bed occurs. The combination of a higher resistance and increased blood viscosity, which may for instance result from relative endogeneous hypercortisolism, can result in sectorial hypoperfusion and an increased endoluminal pressure in the surrounding tissue. Together with chronic hypoxic damage, a breakdown in the continuity of the RPE outer blood-retinal-barrier may occur,³¹ leading to SRF leakage with a serous neuroretinal detachment in CSC.^{32, 33}

5.3 Genetic findings

Familial occurrence of CSC,^{51, 52} as well as interracial differences in the prevalence of chronic CSC suggest a role for genetic factors in CSC.³⁻⁵

In one of the first genetic studies ever in CSC, we have found several genetic factors that are associated with chronic CSC. First of all, we have found an association with a variant in the *age-related macular susceptibility 2 (ARMS2)* gene (**Chapter 2.1**). Specific polymorphisms in the *ARMS2* gene are well known to be associated with AMD.^{53, 54} Interestingly, the reported association of the *ARMS2* SNP (rs10490924) with AMD appears to have an opposite effect compared to the effect that we found in chronic CSC. Where the *ARMS2* variant is risk-conferring for AMD, we found that it is protective for chronic CSC. Based on specific phenotypic characteristics we stratified patients into different groups ranging from typical chronic CSC patients with bilateral disease, typical chronic CSC patients with unilateral involvement, to atypical chronic CSC patients that show overlap with or are similar to a form of AMD (**Chapter 2.1**). Intriguingly, differences between these groups are not only present on a phenotypic level, but can also be found at a genetic level. When comparing the first two groups, no significant difference in minor allele frequency of the tested SNP was found. However, when comparing the typical CSC subgroups with the more atypical patients, a

significant difference in allele frequency in the *ARMS2* SNP was demonstrated. The atypical subgroup consisted of patients in which the phenotype showed considerable overlap with other macular diseases such as AMD. Interestingly, the minor allele frequencies found in this group were similar to those normally observed in AMD, with the same direction of effect seen in AMD as opposed to typical CSC.

In addition, this *ARMS2* SNP has been previously associated to the subtype of PCV with a branching vascular network.^{55, 56} However, no significant association was found with the form of PCV without a branching network. Especially clinical features of PCV without a branching network show a large overlap with the CSC phenotype,^{47, 57, 58} and it is not uncommon for PCV patients to report an episode of CSC in their medical history.⁵⁹ The presence of a branching vascular network, possibly indicating an early CNV, on the other hand, shows more overlap with the neovascular subtype of AMD, illustrating the phenotypical overlap between these macular diseases. Therefore, Miki et al. hypothesized that there may be a functional role of *ARMS2* at the level of the RPE and/or choroid that may contribute to the formation of branching network vessels in PCV and/or CNV in AMD.⁵⁵ Indeed, recent studies have shown that the *ARMS2* protein interacts with components of the extracellular matrix, and is strongly expressed in the regions around the capillaries and intercapillary pillars of the choroid.⁶⁰

Associations found with other SNPs in our study on genetic risk factors in chronic CSC also pointed towards the involvement of the extracellular matrix, although significance was lost after correcting for multiple testing (**Chapter 2.1**). The extracellular matrix provides structural and biochemical support to surrounding cells in human tissue. Changes in this matrix in the choroidal vessels and Bruch's membrane could lead to either more rigidity of these structures, or an increased elasticity as compared with the healthy population. In the situation of an increased rigidity of the vessels, an increase in choroidal vascular resistance could occur, inducing an increase in local vascular blood pressure. On the other hand, an increased elasticity could result in a local impairment of the vascular pressure wave propagation that usually supports the flow of blood through the vessels. This could eventually lead to congestion of blood in the choroidal vasculature. Either way, decompensation at the level of the choroid may occur, and possibly lead to fluid leakage. The choroid is significantly thickened in CSC patients as compared to controls on enhanced depth OCT, and areas of choroidal congestion and hyperpermeability have been described on ICGA. Therefore, choroidal congestion appears to be a plausible mechanism causing the fluid leakage.

Besides the rs10490924 *ARMS2* SNP, we also found that the *CFH* rs1061170 / Y402H SNP is significantly associated with chronic CSC. Again, as with *ARMS2*, an opposite effect was found for this association as compared to AMD.⁵³ A study in a Japanese cohort and a Greek population also identified associations between CSC and common *complement factor H* (*CFH*) polymorphisms.^{61, 62} *CFH* plays an important role as an inhibitor of the complement system, which is an essential part of the innate immune system.⁶³ It complements the ability

of antibodies and phagocytic cells to clear pathogens such as bacteria from the human body. The complement system consists of a number of proteins that are normally found in the blood as inactive precursors. Activation of these precursors is necessary to create an appropriate immune response, which is normally directed against the invading pathogens. Disturbances in the complement system can lead to an underactivation, resulting in an increased susceptibility to pathogens, or to a harmful overactivation, which can inadvertently damage self-cells. Activation of the complement system proceeds through one of three possible pathways; the classical pathway, the lectin pathway or the alternative pathway. Each of these pathways eventually initiates a cascade in which the complement system becomes activated, activating the C3 convertase, followed by C5 convertase activation, leading to terminal pathway activity (**Figure 1**).

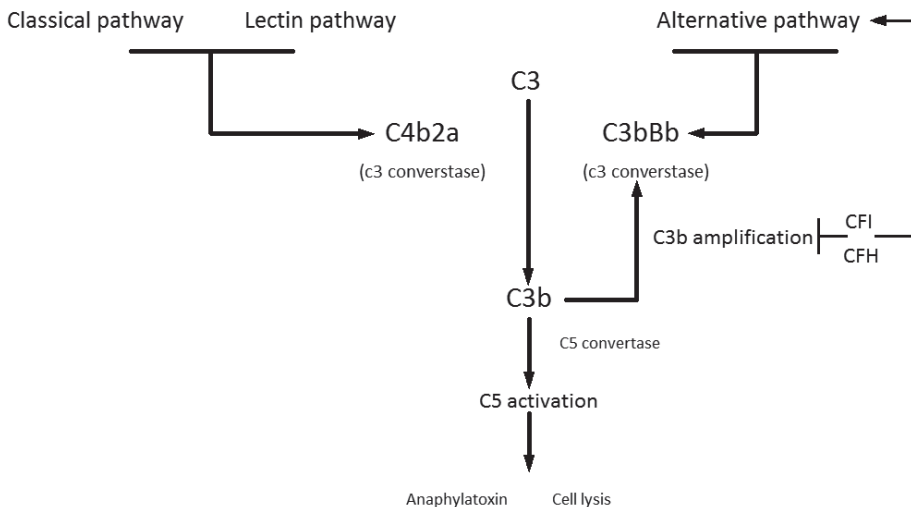


Figure1.

Schematic illustration of the activation and function of C3 as a central player in the complement system.

The complement activity is strongly regulated by several inhibitory proteins. For AMD it is suggested that the alternative pathway plays the most important role in the pathogenesis. CFH is a potent inhibitor of the alternative pathway of the complement system by acting on 3 different steps. CFH not only influences the decay of C3 convertase, but is also competitive toward factor B and is a cofactor to allow cleavage of C3b into an inactive form. In AMD, changes in the CFH protein appear to result in an overactive complement system, with proven elevated serum levels of complement. The overactivity of the complement system in AMD results in inflammation at the level of the Bruch's membrane and RPE. Furthermore, an altered alternative complement pathway activity, extravasation of complement-related proteins, and deposition of terminal complement membrane attack complexes, may all lead

to RPE damage and dysfunction. Damage of the RPE outer blood-retinal barrier could thus result for instance from (a combination of) complement dysfunction, abnormalities in the underlying extracellular matrix, and a dysfunctional, hyperpermeable thickened choroid. When the RPE outer blood-retinal barrier is disrupted focally or more diffusely, this opens the gates to possible subretinal leakage, resulting the classical clinical picture of a serous neuroretinal detachment. Also, *CFH* binds and interacts with adrenomedulin, which has been shown to induce vasodilatation of the choroid, increase microvascular permeability, and affect the choroidal blood flow. However, our findings in **Chapter 2.1** show opposite effects in the association of several *CFH* SNPs in the chronic CSC population as compared to AMD. To date no clinical information regarding the serum levels of the complement system exist in chronic CSC. Therefore, it is unclear if and how the *CFH* SNPs affect the activity of the complement system. It might therefore be possible that an impaired complement system rather than an overactive one as in AMD underlies CSC.

Our identification of *CFH* SNPs in association with chronic CSC is not the only lead that points towards an involvement of the complement system. Interestingly, we also found an association with genetic variations of the *complement 4 (C4)* gene (**Chapter 2.2**). Different from *CFH*, *C4* acts through the classical and lectin pathways. The *C4* gene encodes the *C4* protein, of which two variants have been described (*C4A* and *C4B*), differing in only four amino acids.⁶⁴ The gene lies within the *RP-C4-CYP21-TNX* (*RCCX*) locus situated within the major histocompatibility complex region III (MHCIII) on chromosome 6 of the human genome.⁶⁵ The MHC region contains an elevated level of genomic copy number (GCN) variations that are presumably present to increase the immunological diversity.⁶⁶ These duplications and deletions have led to the formation of haplotypes containing variable copies of the *RCCX* module in the human population.^{66, 67} Haplotypes containing two or more duplications of the *RCCX* locus show extensive variability in their gene build-up, generally with complete duplications of the *C4* gene.^{67, 68} Our study showed that *C4B* genomic copy numbers were significantly lower in chronic CSC patients compared to healthy controls. Carrying no copies of *C4B* conferred significant risk of chronic CSC, whereas three copies of *C4B* significantly decreased the risk of chronic CSC (**Chapter 2.2**). Associations of *C4B* copy number variations with several ocular diseases and autoimmune disorders (e.g. Vogt-Koyanagi-Harada disease and Behçet's disease), have been described in previous studies. In Vogt-Koyanagi-Harada disease, a T-cell-mediated auto-immune response against melanocytes occurs, resulting in a diffuse choroiditis. On OCT patients can present with an ocular phenotype consisting of an SRF accumulation in the fundus, and a thickened choroid. Furthermore, FA classically demonstrates widespread, pinpoint areas of leakage throughout the fundus.⁶⁹ Hou et al. described a decreased expression of serum *C4* and a decreased frequency of high *C4* gene copy number in patients with Vogt-Koyanagi-Harada disease. Although we did not see the same effect concerning the *C4* gene copy numbers in the chronic CSC patients, it may be possible that serum *C4* is also abnormal in CSC. In addition, several studies have reported a

positive linear correlation between serum C4 and *C4* genomic copy number, which suggests that a lower number of *C4B* copies in chronic CSC leads to lower systemic C4B levels. It should be noted, however, that although the phenotypes of chronic CSC and Vogt-Koyanagi-Harada disease show a certain phenotypical overlap, the treatment of Vogt-Koyanagi-Harada disease consists of long term use of high-dose corticosteroids in contrast to CSC which is aggravated by corticosteroids, suggesting another pathophysiological pathway.

In addition to the aforementioned associations, Banlaki et al. discovered an association between the genomic copy number of *C4B* and cortisol release after adrenocorticotrophic hormone (ACTH) stimulation. This link to the hypothalamic-pituitary-adrenal (HPA)-axis is of increased interest as chronic CSC has been associated with stress, endogenous hypercortisolism and the use of corticosteroids. Stress on its own has a strong influence on the HPA-axis and increases ACTH release. Banlaki et al. found that low copy numbers of *C4B* were associated with hyperactivity of the HPA-axis. Patients with a low *C4B* genomic copy number responded with a higher cortisol response after ACTH stimulation. To date, various small studies have evaluated the cortisol levels in chronic CSC patients, thusfar without finding a clear indication for a chronic elevated cortisol level. Although a possible association of the cortisol levels and chronic CSC is at present uncertain, it is possible that patients with chronic CSC generally have normal cortisol levels, but respond differently to stimulation of the HPA axis. The low *C4B* copy numbers observed in our chronic CSC patients may support this hypothesis.

It is unknown how increased levels of cortisol can link to SRF accumulation. Interestingly, Zhao et al. have introduced an idea of a possible involvement of the glucocorticoid receptor (GR) and the mineralocorticoid receptor (MR). The MR is typically expressed in kidney cells, but is also present in the retina and in the choroidal vessels.⁷⁰ Based on the association of CSC with corticosteroids, it was postulated that inappropriate/excessive occupancy of the MR by glucocorticoids may occur in the choroid of CSC patients. A rat model was used to investigate the short-term effects of MR activation in choroidal vasculature after intravitreal injection of corticosteroids. They found that the injection of corticosteroids resulted in a thickening of the choroid within 24 hours. In addition, an injection of aldosterone, a classic MR ligand, also induced choroid thickening and vasodilatation of the choriocapillaris and choroidal vessels. It appears that a mechanism involving the K⁺ channel KCa2.3 is involved in the MR-induced choroidal thickening promoted by aldosterone.⁷¹ The clinical information gathered from human studies support the idea that CSC starts with abnormalities at the level of the choroid. Therefore, the findings in this rat model may translate well to the human model, and local MR activation by endogenous or exogenous glucocorticoids may be involved in the underlying disease mechanism. These findings have also resulted in clinical studies that are described in the section 5.4 *Treatment of chronic central serous chorioretinopathy*.

In another study, a connection between corticosteroids and the *Cadherin 5* gene was found to be associated with CSC in male patients.⁷² Cadherin 5 is the major cell-cell adhesion molecule in the vascular endothelium. Functional studies illustrated that prednisolone in cultured endothelial cells and human organ cultures, and triamcinolone in mice *in vivo*,

significantly reduced the expression of *Cadherin 5* mRNA. It is suggested that this results in an increased vascular permeability *in vivo*, possibly explaining the vascular changes as seen in the choroid of CSC patients.⁷² However, the latter described association was only found in male patients of the study cohort, and no correction for multiple testing was performed, indicating that the relevance of these findings should be further investigated.

5.4 Treatment of chronic central serous chorioretinopathy

Studies suggest that the persistence of serous SRF longer than four months may finally result in permanent atrophic damage of the neuroretina.² These findings, and the progressive nature of chronic CSC and its negative impact on the vision-related quality of life that we describe in **Chapter 3.1**, emphasizes the need for an effective treatment in this patient group. The primary aim of treatment in CSC is to restore visual acuity and image quality, and to eliminate metamorphopsia. With serous SRF accumulation in the macula being the principal vision-threatening feature, treatment should aim to achieve a complete resolution of macular SRF, thus inducing a re-attachment of the neurosensory retina. A wide range of different treatments have been used in CSC patients over the past decades, with various results (**Table 1**). Unfortunately, virtually all of these therapeutic options have been described in a retrospective study setting in clinically variable CSC patients (ranging from acute to chronic CSC). Therefore, there is still much controversy regarding the optimal treatment strategy in CSC.

Table 1. An overview of therapeutic interventions described in central serous chorioretinopathy

Conventional thermal laser treatment	Argon laser ^{37, 73-75}
Photodynamic therapy (PDT)	Standard settings PDT ⁷⁶ Half-dose PDT ⁷⁷ Half-fluency PDT ^{78, 79} Half-time PDT ⁸⁰
High-density subthreshold micropulse laser treatment and selective retina therapy laser	Wavelength: 810 nm ⁸¹ Wavelength: 577 nm ⁸² Wavelength: 527 nm ⁸³
Anti-vascular endothelial growth factor treatment	Ranibizumab ⁸⁴ Bevacizumab ⁸⁵ Aflibercept ⁸⁶
Systemic treatment	Carbonic anhydrase inhibitors ⁸⁷ Beta-blockers ⁸⁸ Treatment against <i>H. pylori</i> infection ^{89, 90} Glucocorticoidreceptor antagonists ⁹¹ Anti-platelets ⁹² Antimetabolites ⁹³ 5 α -reductase inhibitors ¹³ Aldosterone/mineralocorticoid receptor antagonists ^{70, 71}

One of the most frequently used treatment options in the past has been conventional laser photocoagulation treatment of the hot spots of leakage based on FA.^{37, 73-75} This approach is largely based on the idea that the primary problem in chronic CSC occurs on the level of the RPE, as suggested by the focal or diffuse leakage seen on FA. Conventional laser photocoagulation, often using an Argon laser, has been shown to have a positive effect on the hastening the resolution of the SRF accumulation, especially in the acute CSC phenotype with obvious focal leakage.³⁷ However, due to the localized thermal damage, side effects such as (para)central scotoma and iatrogenic CNV can occur, particularly if performed in the juxtafoveal area.^{3, 94, 95} A way to bypass these side effects, was made possible by the introduction of the High-density subthreshold micropulse laser (HSML) and selective retina therapy. In HSML, a laser is used to deliver a high-density pattern of repetitive multiple short low energy pulses, selectively targeting the RPE without inducing a visible laser burn.⁹⁶ HSML laser can either be used to only treat the hot spots of leakage seen on FA, or to apply high-density laser treatment on all hyperfluorescent areas in the posterior pole seen on ICGA. Both 810nm and 577 nm HSML treatment has been described in acute and chronic CSC. A study using a HSML treatment with a wavelength of 810 nm evaluated the macular thickness as a primary outcome. Eleven eyes of ten symptomatic CSC patients, that had SRF for at least three months, were included. They found a reduction of the maximum macular thickness in 72.7% of the cases after treatment.⁸¹ Scholz et al. used HSML treatment with a 577 nm wavelength. In this study 38 eyes of 38 CSC patients were included. A response to treatment at the final follow-up (5 months after treatment) was seen in 74% of the eyes, defined as a reduction of SRF (50%) or a complete absence of SRF (24%). The authors also note that although a confluent treatment was performed, several patients needed a repetition of the treatment.⁸² Finally, selective retina therapy with a wavelength of 527 nm demonstrated a positive effect especially in acute CSC patients up to 100% reduction of SRF on OCT, but less promising results in patients with chronic CSC.^{83, 97}

Another laser-based treatment, photodynamic therapy (PDT), is probably the most commonly used treatment for chronic CSC at present. PDT was originally developed to treat neovascular AMD,^{98, 99} and is used as an off-label treatment in CSC. In PDT the photosensitive drug verteporfin (Visudyne®) is administered intravenously and activated in the eye by a laser light with a wavelength ranging between 689-693 nm. The activation of verteporfin results in a cascade of events finally causing endothelial vascular damage and vessel occlusion in the choriocapillaris/choroid.^{3, 100} There is an ongoing debate on whether to perform FA-guided or ICGA-guided PDT treatment. Multimodal imaging has demonstrated that abnormalities are often more pronounced and more extensive in the choroid of CSC patients as compared to the RPE, indicating that the choroid is the primarily affected structure in CSC, many consider ICGA-guided treatment the method of choice.^{77, 101-103} The exact mechanism through which PDT treatment influences the choroid is not fully known, but it is thought to mainly target the choroid. A possible explanation is that PDT results in selective local choroidal damage, which causes short-term choriocapillaris

hypoperfusion and long-term choroidal restructuring. This remodelling is thought to reduce choroidal congestion, hyperpermeability, and extravascular leakage.^{3, 104, 105} Two follow-up studies, with 4 and 5 years of follow-up respectively, have shown that the use of the original settings (6 mg/m² of verteporfin with a laser fluency of 50 J/cm²) in CSC patient appears to be effective and safe.^{76, 106} In the study with 4-years of follow-up a complete resolution of SRF was achieved in 93% of the subjects, and a significant improvement of visual acuity was seen. No systemic or ocular side effects were registered.⁷⁶ However, rare but serious side effects such as choriocapillary non-perfusion and atrophy, secondary CNV, RPE atrophy and subsequent visual loss have been described with these full settings.^{3, 101} Because of these reported side effects, and since the aim of treatment for CSC is not neovascular vessel closure but rather a decrease in leakage and hyperpermeability from existing choroidal vessels with subsequent resorption of fluid,¹⁰¹ reduced settings have been introduced in the treatment of CSC patients. Reduction of the settings can be induced either by using half the normal dose of verteporfin (3 mg/m²: half-dose PDT); by reducing the fluency to 25 J/cm² - half-fluency PDT - or by limiting the treatment time to 42 seconds: half-time PDT. A recent meta-analysis reported that the use of half-dose PDT resulted in a significant improvement of visual acuity, and kept central macular thickness significantly lower as compared to a placebo group.¹⁰⁷ Also, the proportion of eyes with a complete resolution of SRF was 18.4 fold higher in the half-dose PDT group as compared to the placebo group based on the combined data from mostly retrospective studies.¹⁰⁷⁻¹¹⁰ The use of half-fluency PDT also results in a significant improvement of the visual acuity. Complete resorption of the SRF has been reported in 81-100% of chronic CSC patients.^{78, 79, 101, 111} Interestingly, one study found that half-fluence PDT resulted in less choriocapillaris nonperfusion (seen on ICGA), as compared to standard-fluence PDT (0% versus 44%).⁷⁹ The success rate of half-dose PDT treatment in our study, in which we used a strict definition of 'success' as a complete absence of SRF on OCT after a single half-dose PDT treatment, was 63%, which is lower than reported in previous retrospective studies on PDT in chronic CSC. A possible explanation may relate to the fact that 25% of the included patients had previously received a treatment (excluding PDT) for chronic CSC before being enrolled in our treatment protocol. It is currently unknown if there is a difference in success rate between half-dose, half-fluency, or half-time PDT treatment for CSC. In a study by Nicolo et al., a higher success rate with a complete resolution of SRF after 12 months was found for half-dose as compared to half-fluency PDT (100% vs 84%),¹¹² but other studies did not find a significant difference between half-dose PDT and half-fluency or half-time PDT.^{113, 114} Therefore, it may be preferable at present to use half-dose PDT to treat CSC, to reduce the likelihood of verteporfin-associated side effects, as we did in the PLACE trial (**Chapter 4.3**) in which half-dose PDT is compared to HSML treatment in chronic CSC. There are several other chorioretinal diseases besides CSC for which PDT with verteporfin is successfully used as an off-label treatment, such as choroidal haemangioma and PCV.⁹⁸

Besides laser interventions, several systemic treatment options have been suggested for CSC (**Table 1**). Unfortunately, most of the published studies that investigated

other systemic treatments included relatively small sample sizes and were retrospective, with a resulting poor quality of scientific evidence.³¹ A recently introduced and possible promising approach involves the use of oral treatment with MR antagonists. This approach is based on the previously described finding that an overstimulation of the MR in a rat model causes dilatation of the choroidal vasculature and choroidal thickening, similar to clinical observations in chronic CSC.⁷¹ The use of spironolactone, a competitive MR antagonist, has been reported in a case series of 18 patients. The use of 50 mg daily for up to three months resulted in a decrease in SRF (119 μm) and reduced central foveal thickness was found (118 μm), accompanied by an increase of visual acuity from 0.32 at baseline to 0.20 after 3 months.¹¹⁵ Also, the use of oral eplerenone, a selective MR antagonist, during a treatment period of 1-3 months was investigated in 13 patients with CSC of at least 4-month duration. A complete resolution of SRF was seen in 25% of the patients after 1 month of eplerenone treatment, and 67% at 3 months after use of eplerenone, which is lower than most success rates reported for PDT.⁷⁰ The same group that introduced the thought of the use of eplerenone, recently presented novel retrospective results in 54 eyes.¹¹⁶ The eyes had either persistent SRF that lasted longer than 4 months, or recurrent SRF that lasted longer than 2 months, compatible with the diagnosis of chronic CSC. A complete resolution of SRF was seen in 38% and 50% of the eyes at 3 and 6 months, respectively. In these studies it was not clearly described into which category persistent or recurrent CSC these eyes could be categorized, but is unclear if this classification would have any consequence.¹¹⁶ Large multicenter prospective, randomized, controlled trials evaluating the use of eplerenone and spironolactone are currently lacking. Therefore, in this thesis we only tested eplerenone in a pilot setting in chronic CSC patients who were previously treatment-resistant to other therapies (**Chapter 4.4**). In this patient population beneficial effects were only noticed in a minority of the patients.

Corticosteroids and PDT treatment

A strong association exists between the use of corticosteroids and chronic CSC.⁷ It is generally advised to stop corticosteroids in CSC patients if medically possible, although it is unknown what the likelihood is that cessation of corticosteroids can lead to a resolution of CSC. The question arises as to whether patients with clear corticosteroid-associated chronic CSC respond in the same way to PDT treatment as patients without any history of corticosteroid use. If different, it could not only influence the clinical practice in these patients, but can also give rise to new insights into the pathogenesis. The retrospective study we performed however, showed no differences in response to PDT treatment in patients with chronic CSC that was or was not associated with corticosteroid use (**Chapter 4.2**). The findings in our study are encouraging as they suggest that the continuation of corticosteroid treatment, if inevitable for other medical indications, does not exclude a favorable response to PDT. However, it should be emphasized that cessation of corticosteroid use, if possible, can also lead to full resolution of SRF, and should always be endeavoured before further treatment

is initiated. Our findings may also suggest a similar pathophysiological mechanism between chronic CSC patients using corticosteroids and patients who have no reported history of corticosteroid use. It is more likely that the corticosteroids provoke chronic CSC in patients, for instance by exceeding a certain vulnerability threshold. The same mechanism could exist in patients without any reported use of corticosteroids. In these cases a systemic rise of endogenous 'steroids' such as cortisol may be the cause of exceeding a similar threshold, although more research is definitely needed to test this hypothesis.

Prospective treatment approach using half-dose PDT and HSML

In this thesis we reviewed a treatment protocol using up to two half-dose PDT treatments in chronic CSC, followed by HSML if there was no complete resolution of SRF after previous PDT treatment. The success rates of the PDT treatment in this study cohort were found to be lower as compared to previous studies on PDT in chronic CSC (**Chapter 4.1**). Previous studies have described success rates that generally fall between 81% and 100%.^{78, 101, 117-119} Four studies included patients with symptomatic CSC for at least 6 months. In 3 studies evaluation took place 1 month after half-dose PDT treatment, one study reporting complete resolution of SRF on OCT in 100% versus 85% and 87% of cases in the other studies¹¹⁷⁻¹¹⁹ One study had a second evaluation moment at final follow-up (14.2 ± 5.8 months): at this time point absence of SRF on OCT in the macula was seen in as much as 92% of the study eyes. Another study looked at the results after one half-dose PDT treatment and found a complete resolution of SRF on OCT in 86% of all eyes.⁷⁸ During follow-up, recurrence of SRF on OCT was reported in 14% of the eyes, in which case the eyes were retreated with half-dose PDT. At the end of the follow-up (minimum of 12 months and a maximum of 40 months) all eyes had absence of SRF on OCT.⁷⁸ Our study found treatment success, defined as an absence of the SRF on OCT after treatment in 63% of cases after 1 half-dose PDT treatment. However, the retrospective character of most of the current studies on half-dose PDT make a one-to-one comparison difficult. Not only are there differences in the follow-up time, but there may also be a positive publication bias for studies which found higher success rates. In addition, it is possible that these differences can be explained by different definitions of chronic CSC. The definition of the chronic CSC phenotype, as used in this thesis, is not yet universally accepted. Many studies still distinguish acute from chronic CSC based on the period in which SRF is present. In our study, however, we defined active chronic CSC by active leakage of fluid under the retina as evidenced on spectral domain OCT and further supported by hyperfluorescent area (s) on ICGA or/and ≥ 1 ill-defined leakage area(s) on FA. Therefore, it is possible that other groups have included milder phenotypes that are more prone to show spontaneous resolution of the SRF accumulation or are more likely to show a favorable treatment response to PDT. In addition, 25% of the included patients in our study had previously received a treatment (excluding PDT) for chronic CSC before being enrolled in our treatment protocol, which indicates that we included relatively severe chronic CSC cases. We observed that a second half-dose PDT treatment, in patients with persistent SRF after the first PDT treatment, resulted in a complete resolution in 67%

of these patients. Only 20% of the eyes that received 2 half-dose PDT treatments prior to HSML treatment responded with complete resolution of SRF on OCT after HSML treatment. As we did not study HSML as primary treatment we are unable to compare our results to the current literature on HSML treatment in CSC patients.

The PLACE trial: a prospective, multicenter randomized controlled treatment trial for chronic central serous chorioretinopathy

A recent meta-analysis of 25 studies with a total of 1098 participants concluded that of the interventions for CSC studied to date, PDT or HSML treatment appear the most promising to study in prospective randomized controlled trials.¹²⁰ Although current literature appears to be in favor of PDT treatment as compared to HSML treatment, no large multicenter prospective randomized controlled treatment trials have thus far been performed that compare PDT to HSML treatment. Furthermore, besides this lack of prospective studies, there are no long-term studies (>12 months) recording visual function, recurrence rate, benefit of possible re-treatments, and the rate of adverse events after single or multiple treatments.³ In this thesis we introduce the PLACE-trial (**Photodynamic therapy versus micropulse laser treatment in chronic central serous chorioretinopathy**) (**Chapter 4.3**). In this multicenter prospective randomized controlled treatment trial (clinicaltrials.gov identifier: NCT01797861; EUDRACT number 2012-004555-36), half-dose PDT and HSML are compared as treatments for chronic CSC. Since half-dose PDT appears to be more promising for chronic CSC according to current, largely retrospective literature, a superiority design was chosen for this study protocol. Currently, this investigator-initiated trial is conducted in 5 different tertiary university clinics, in 4 different European countries (Radboud University Medical Center, Nijmegen, the Netherlands; Leiden University Medical Center, Leiden, the Netherlands; University Eye Clinic of Cologne, Cologne, Germany; Oxford University Eye hospital, Oxford, United Kingdom; University Eye Clinic of Créteil, University of Paris Est Créteil, Paris, France). A total of 156 chronic CSC patients, with active leakage of fluid under the retina as evidenced on OCT scanning and further supported by findings on FA and ICGA, in at least one eye, will be recruited. Extensive phenotyping based on multimodal imaging including fundus photography, OCT of the retina and choroid, autofluorescence imaging, FA and ICGA will be performed. With this extensive phenotyping a more homogeneous chronic CSC study group can be included in this treatment trial. After inclusion the patients will be randomized into the two treatment arms: half-dose PDT or HSML treatment. A complete ophthalmological examination with visual acuity measurement, microperimetry, vision-related quality of life (NEI VFQ-25) and stress questionnaires, will be performed at baseline; 6-8 weeks after first treatment; 6-8 weeks after a second treatment (if necessary); and at the final follow-up visit at 7-8 months after first treatment. The primary endpoint of this study is to assess if there is a difference between the efficacy, based on the absence or persistence of SRF on OCT, of half-dose PDT treatment versus HSML treatment in patients with chronic CSC. In addition, we have added a number of functional secondary outcome parameters.

The results of this study will not only provide information about whether half-dose PDT is indeed superior to HSML treatment on an anatomical level, but also with regard to functional parameters including visual acuity, microperimetry, and vision-related quality of life. In addition, the extensive multimodal imaging performed will enable us to look for phenotypical features that may predict response to treatment. In addition, the influence of treatment on the anatomy of the ocular tissue may be evaluated. Finally, this prospective study protocol generates a unique, well-comparable dataset providing information regarding epidemiological factors, and long-term clinical outcome (both anatomical and functional) in chronic CSC.

5.5 Final remarks and future perspectives

In conclusion, the findings reported in this thesis illustrate that genetic factors may provide important clues towards a better understanding of the etiology of chronic CSC. We have shown that genetic factors are involved in the susceptibility to the disease, despite the fact that environmental factors such as corticosteroids also appear to play an important role in CSC. New methods to discover additional genetic risk factors, such as a genome-wide association study or whole exome/genome sequencing, and functional studies to determine the effect of the genetic findings are necessary to further investigate the network of genetic factors and molecular pathways involved in CSC. Such approaches may not only lead to further new insights into the pathophysiology of chronic CSC, but may also identify new preventive and therapeutic targets. For example, complement modulation treatment, which is already being studied for geographic AMD,¹²¹⁻¹²³ may prove to be an interesting treatment option for CSC.

We have also demonstrated the importance of detailed phenotyping to obtain reliable results, not only for study purposes, but also for clinical practice. A pilot classification to differentiate between typical and more atypical cases of chronic CSC was introduced. Interestingly, differences found between these phenotypic groups also translated into differences on a genetic level. The phenotype thought to be atypical for chronic CSC, showed more overlap with AMD not only on a phenotypic level, but also on a genetic level. Therefore, further research should be initiated to study the similarities and differences between chronic CSC and AMD.

To date, no uniformity regarding the treatment of chronic CSC exists due to the lack of well-designed prospective randomized controlled trials. In contrast to acute CSC, for which an initial watch and wait policy may be appropriate, chronic CSC patients should receive adequate treatment. A broad spectrum of treatment modalities is being or has been used in chronic CSC, with variable success. A recent meta-analysis concluded that currently the most promising treatment modalities are PDT and HSML treatment.¹²⁰ To determine if and which of these two therapeutic approaches may be superior, we designed the first prospective randomized controlled trial for chronic CSC that compares half-dose PDT with

HSML treatment. The results of these studies will potentially lead to the establishment of a best-practice treatment guideline to treat chronic CSC.

References

1. Kitzmann AS, Pulido JS, Diehl NN, et al. The incidence of central serous chorioretinopathy in Olmsted County, Minnesota, 1980-2002. *Ophthalmology* 2008;115(1):169-73.
2. Wang M, Munch IC, Hasler PW, et al. Central serous chorioretinopathy. *Acta Ophthalmol* 2008;86(2):126-45.
3. Daruich A, Matet A, Dirani A, et al. Central serous chorioretinopathy: Recent findings and new physiopathology hypothesis. *Prog Retin Eye Res* 2015.
4. Tsai DC, Chen SJ, Huang CC, et al. Epidemiology of idiopathic central serous chorioretinopathy in Taiwan, 2001-2006: a population-based study. *PLoS One* 2013;8(6):e66858.
5. Liew G, Quin G, Gillies M, Fraser-Bell S. Central serous chorioretinopathy: a review of epidemiology and pathophysiology. *Clin Experiment Ophthalmol* 2013;41(2):201-14.
6. How AC, Koh AH. Angiographic characteristics of acute central serous chorioretinopathy in an Asian population. *Ann Acad Med Singapore* 2006;35(2):77-9.
7. Haimovici R, Koh S, Gagnon DR, et al. Risk factors for central serous chorioretinopathy: a case-control study. *Ophthalmology* 2004;111(2):244-9.
8. Boss L, Kang DH, Marcus M, Bergstrom N. Endogenous sex hormones and cognitive function in older adults: a systematic review. *West J Nurs Res* 2014;36(3):388-426.
9. Milman LW, Sammel MD, Barnhart KT, et al. Higher serum total testosterone levels correlate with increased risk of depressive symptoms in Caucasian women through the entire menopausal transition. *Psychoneuroendocrinology* 2015;62:107-13.
10. Zumoff B, Rosenfeld RS, Friedman M, et al. Elevated daytime urinary excretion of testosterone glucuronide in men with the type A behavior pattern. *Psychosom Med* 1984;46(3):223-5.
11. Yannuzzi LA. Type A behavior and central serous chorioretinopathy. *Retina* 2012;32 Suppl 1:709.
12. Rocha EM, Wickham LA, da Silveira LA, et al. Identification of androgen receptor protein and 5 α -reductase mRNA in human ocular tissues. *Br J Ophthalmol* 2000;84(1):76-84.
13. Forooghian F, Meleth AD, Cukras C, et al. Finasteride for chronic central serous chorioretinopathy. *Retina* 2011;31(4):766-71.
14. Carvalho-Recchia CA, Yannuzzi LA, Negrao S, et al. Corticosteroids and central serous chorioretinopathy. *Ophthalmology* 2002;109(10):1834-7.
15. Bouzas EA, Scott MH, Mastorakos G, et al. Central serous chorioretinopathy in endogenous hypercortisolism. *Arch Ophthalmol* 1993;111(9):1229-33.
16. Giovansili I, Belange G, Affortit A. Cushing disease revealed by bilateral atypical central serous chorioretinopathy: case report. *Endocr Pract* 2013;19(5):e129-33.
17. Wakakura M, Ishikawa S. Central serous chorioretinopathy complicating systemic corticosteroid treatment. *Br J Ophthalmol* 1984;68(5):329-31.
18. Wakakura M, Song E, Ishikawa S. Corticosteroid-induced central serous chorioretinopathy. *Jpn J Ophthalmol* 1997;41(3):180-5.
19. Bouzas EA, Karadimas P, Pournaras CJ. Central serous chorioretinopathy and glucocorticoids. *Surv Ophthalmol* 2002;47(5):431-48.

20. Fardin B, Weissgold DJ. Central serous chorioretinopathy after inhaled steroid use for post-mycoplasmal bronchospasm. *Br J Ophthalmol* 2002;86(9):1065-6.
21. Khairallah M, Kahloun R, Tugal-Tutkun I. Central serous chorioretinopathy, corticosteroids, and uveitis. *Ocul Immunol Inflamm* 2012;20(2):76-85.
22. Chang YS, Weng SF, Chang C, et al. Associations between topical ophthalmic corticosteroids and central serous chorioretinopathy: a taiwanese population-based study. *Invest Ophthalmol Vis Sci* 2015;56(6):4083-9.
23. Haimovici R, Rumelt S, Melby J. Endocrine abnormalities in patients with central serous chorioretinopathy. *Ophthalmology* 2003;110(4):698-703.
24. Shang Q, Liu C, Wei S, et al. [Determination of cortisol in plasma and 24-hour urine of patients with central serous chorioretinopathy]. [*Zhonghua yan ke za zhi*] Chinese journal of ophthalmology 1999;35(4):297-9.
25. Tufan HA, Gencer B, Comez AT. Serum cortisol and testosterone levels in chronic central serous chorioretinopathy. *Graefes Arch Clin Exp Ophthalmol* 2013;251(3):677-80.
26. Zakir SM, Shukla M, Simi ZU, et al. Serum cortisol and testosterone levels in idiopathic central serous chorioretinopathy. *Indian J Ophthalmol* 2009;57(6):419-22.
27. Yannuzzi LA. Central serous chorioretinopathy: a personal perspective. *Am J Ophthalmol* 2010;149(3):361-3.
28. Eandi CM, Ober M, Iranmanesh R, et al. Acute central serous chorioretinopathy and fundus autofluorescence. *Retina* 2005;25(8):989-93.
29. Quin G, Liew G, Ho IV, et al. Diagnosis and interventions for central serous chorioretinopathy: review and update. *Clin Experiment Ophthalmol* 2013;41(2):187-200.
30. von Winning CH, Oosterhuis JA, Renger-van Dijk AH, et al. Diffuse retinal pigment epitheliopathy. *Ophthalmologica* 1982;185(1):7-14.
31. Nicholson B, Noble J, Forooghian F, Meyerle C. Central serous chorioretinopathy: update on pathophysiology and treatment. *Surv Ophthalmol* 2013;58(2):103-26.
32. Guyer DR, Yannuzzi LA, Slakter JS, et al. Digital indocyanine green videoangiography of central serous chorioretinopathy. *Arch Ophthalmol* 1994;112(8):1057-62.
33. Prunte C, Flammer J. Choroidal capillary and venous congestion in central serous chorioretinopathy. *Am J Ophthalmol* 1996;121(1):26-34.
34. Piccolino FC, Borgia L. Central serous chorioretinopathy and indocyanine green angiography. *Retina* 1994;14(3):231-42.
35. Bujarborua D. Long-term follow-up of idiopathic central serous chorioretinopathy without laser. *Acta Ophthalmol Scand* 2001;79(4):417-21.
36. Klein ML, Van Buskirk EM, Friedman E, et al. Experience with nontreatment of central serous choroidopathy. *Arch Ophthalmol* 1974;91(4):247-50.
37. Gemenetzi M, De Salvo G, Lotery AJ. Central serous chorioretinopathy: an update on pathogenesis and treatment. *Eye (Lond)* 2010;24(12):1743-56.
38. Lally DR, Gerstenblith AT, Regillo CD. Preferred therapies for neovascular age-related macular degeneration. *Curr Opin Ophthalmol* 2012;23(3):182-8.


39. Maumenee AE. Macular diseases: clinical manifestations. *Trans Am Acad Ophthalmol Otolaryngol* 1965;69:605-13.
40. Yannuzzi LA, Slakter JS, Gross NE, et al. Indocyanine green angiography-guided photodynamic therapy for treatment of chronic central serous chorioretinopathy: a pilot study. *Retina* 2003;23(3):288-98.
41. Imamura Y, Fujiwara T, Margolis R, Spaide RF. Enhanced depth imaging optical coherence tomography of the choroid in central serous chorioretinopathy. *Retina* 2009;29(10):1469-73.
42. Jirattanasopa P, Ooto S, Tsujikawa A, et al. Assessment of macular choroidal thickness by optical coherence tomography and angiographic changes in central serous chorioretinopathy. *Ophthalmology* 2012;119(8):1666-78.
43. Yang L, Jonas JB, Wei W. Optical coherence tomography-assisted enhanced depth imaging of central serous chorioretinopathy. *Invest Ophthalmol Vis Sci* 2013;54(7):4659-65.
44. Kim YT, Kang SW, Bai KH. Choroidal thickness in both eyes of patients with unilaterally active central serous chorioretinopathy. *Eye (Lond)* 2011;25(12):1635-40.
45. Baek J, Park YH. Optical density ratio in the subretinal fluid: differentiating chronic central serous chorioretinopathy and polypoidal choroidal vasculopathy. *Am J Ophthalmol* 2015;159(2):386-92.
46. Yang LH, Jonas JB, Wei WB. Conversion of central serous chorioretinopathy to polypoidal choroidal vasculopathy. *Acta Ophthalmol* 2015.
47. Park HS, Kim IT. Clinical characteristics of polypoidal choroidal vasculopathy associated with chronic central serous chorioretinopathy. *Korean J Ophthalmol* 2012;26(1):15-20.
48. Wang M, Sander B, la Cour M, Larsen M. Clinical characteristics of subretinal deposits in central serous chorioretinopathy. *Acta Ophthalmol Scand* 2005;83(6):691-6.
49. Jia Y, Tan O, Tokayer J, et al. Split-spectrum amplitude-decorrelation angiography with optical coherence tomography. *Opt Express* 2012;20(4):4710-25.
50. Spaide RF, Fujimoto JG, Waheed NK. Optical coherence tomography angiography. *Retina* 2015;35(11):2161-2.
51. Oosterhuis JA. Familial central serous retinopathy. *Graefes Arch Clin Exp Ophthalmol* 1996;234(5):337-41.
52. Weenink AC, Borsje RA, Oosterhuis JA. Familial chronic central serous chorioretinopathy. *Ophthalmologica* 2001;215(3):183-7.
53. Fritsche LG, Chen W, Schu M, et al. Seven new loci associated with age-related macular degeneration. *Nat Genet* 2013;45(4):433-9, 9e1-2.
54. Klein RJ, Zeiss C, Chew EY, et al. Complement factor H polymorphism in age-related macular degeneration. *Science* (80-) 2005;308(5720):385-9.
55. Miki A, Honda S, Kondo N, Negi A. The association of age-related maculopathy susceptibility 2 (ARMS2) and complement factor H (CFH) variants with two angiographic subtypes of polypoidal choroidal vasculopathy. *Ophthalmic Genet* 2013;34(3):146-50.
56. Tanaka K, Nakayama T, Mori R, et al. Associations of complement factor H (CFH) and age-related maculopathy susceptibility 2 (ARMS2) genotypes with subtypes of polypoidal choroidal vasculopathy. *Invest Ophthalmol Vis Sci* 2011;52(10):7441-4.

57. Sakurada Y, Kubota T, Imasawa M, et al. Role of complement factor H I62V and age-related maculopathy susceptibility 2 A69S variants in the clinical expression of polypoidal choroidal vasculopathy. *Ophthalmology* 2011;118(7):1402-7.
58. Yannuzzi LA, Freund KB, Goldbaum M, et al. Polypoidal choroidal vasculopathy masquerading as central serous chorioretinopathy. *Ophthalmology* 2000;107(4):767-77.
59. Koizumi H, Yamagishi T, Yamazaki T, Kinoshita S. Relationship between clinical characteristics of polypoidal choroidal vasculopathy and choroidal vascular hyperpermeability. *Am J Ophthalmol* 2013;155(2):305-13 e1.
60. Kortvely E, Hauck SM, Duetsch G, et al. ARMS2 is a constituent of the extracellular matrix providing a link between familial and sporadic age-related macular degenerations. *Invest Ophthalmol Vis Sci* 2010;51(1):79-88.
61. Miki A, Kondo N, Yanagisawa S, et al. Common variants in the complement factor H gene confer genetic susceptibility to central serous chorioretinopathy. *Ophthalmology* 2014;121(5):1067-72.
62. Moschos MM, Gazouli M, Gatziofias Z, et al. Prevalence of the complement factor H and Gstm1 genes polymorphisms in patients with central serous chorioretinopathy. *Retina* 2016;36(2):402-7.
63. Boon CJ, van de Kar NC, Klevering BJ, et al. The spectrum of phenotypes caused by variants in the CFH gene. *Mol Immunol* 2009;46(8-9):1573-94.
64. Yu CY, Belt KT, Giles CM, et al. Structural basis of the polymorphism of human complement components C4A and C4B: gene size, reactivity and antigenicity. *The EMBO journal* 1986;5(11):2873-81.
65. Szilagyi A, Fust G. Diseases associated with the low copy number of the C4B gene encoding C4, the fourth component of complement. *Cytogenetic and genome research* 2008;123(1-4):118-30.
66. Olsson LM, Holmdahl R. Copy number variation in autoimmunity--importance hidden in complexity? *European journal of immunology* 2012;42(8):1969-76.
67. Chung EK, Yang Y, Rennebohm RM, et al. Genetic sophistication of human complement components C4A and C4B and RP-C4-CYP21-TNX (RCCX) modules in the major histocompatibility complex. *American journal of human genetics* 2002;71(4):823-37.
68. Blanchong CA, Zhou B, Rupert KL, et al. Deficiencies of human complement component C4A and C4B and heterozygosity in length variants of RP-C4-CYP21-TNX (RCCX) modules in caucasians. The load of RCCX genetic diversity on major histocompatibility complex-associated disease. *The Journal of experimental medicine* 2000;191(12):2183-96.
69. Burkholder BM. Vogt-Koyanagi-Harada disease. *Curr Opin Ophthalmol* 2015;26(6):506-11.
70. Bousquet E, Beydoun T, Zhao M, et al. Mineralocorticoid receptor antagonism in the treatment of chronic central serous chorioretinopathy: a pilot study. *Retina* 2013;33(10):2096-102.
71. Zhao M, Celerier I, Bousquet E, et al. Mineralocorticoid receptor is involved in rat and human ocular chorioretinopathy. *J Clin Invest* 2012;122(7):2672-9.
72. Schubert C, Pryds A, Zeng S, et al. Cadherin 5 is regulated by corticosteroids and associated with central serous chorioretinopathy. *Hum Mutat* 2014;35(7):859-67.
73. Leaver P, Williams C. Argon laser photocoagulation in the treatment of central serous retinopathy. *Br J Ophthalmol* 1979;63(10):674-7.

74. Watzke RC, Burton TC, Leaverton PE. Ruby laser photocoagulation therapy of central serous retinopathy. I. A controlled clinical study. II. Factors affecting prognosis. *Trans Am Acad Ophthalmol Otolaryngol* 1974;78(2):OP205-11.
75. Robertson DM, Ilstrup D. Direct, indirect, and sham laser photocoagulation in the management of central serous chorioretinopathy. *Am J Ophthalmol* 1983;95(4):457-66.
76. Silva RM, Ruiz-Moreno JM, Gomez-Ulla F, et al. Photodynamic therapy for chronic central serous chorioretinopathy: a 4-year follow-up study. *Retina* 2013;33(2):309-15.
77. Fujita K, Imamura Y, Shinoda K, et al. One-year outcomes with half-dose verteporfin photodynamic therapy for chronic central serous chorioretinopathy. *Ophthalmology* 2015;122(3):555-61.
78. Rouvas A, Stavrakas P, Theodossiadis PG, et al. Long-term results of half-fluence photodynamic therapy for chronic central serous chorioretinopathy. *Eur J Ophthalmol* 2012;22(3):417-22.
79. Reibaldi M, Cardascia N, Longo A, et al. Standard-fluence versus low-fluence photodynamic therapy in chronic central serous chorioretinopathy: a nonrandomized clinical trial. *Am J Ophthalmol* 2010;149(2):307-15 e2.
80. Tsai MJ, Hsieh YT. Half-time photodynamic therapy for central serous chorioretinopathy. *Optom Vis Sci* 2014;91(9):1140-5.
81. Malik KJ, Sampat KM, Mansouri A, et al. Low-intensity/high-density subthreshold microPulse diode laser for chronic central serous chorioretinopathy. *Retina* 2015;35(3):532-6.
82. Scholz P, Ersoy L, Boon CJ, Fauser S. Subthreshold micropulse laser (577 nm) treatment in chronic central serous chorioretinopathy. *Ophthalmologica* 2015;234(4):189-94.
83. Elsner H, Porksen E, Klatt C, et al. Selective retina therapy in patients with central serous chorioretinopathy. *Graefes Arch Clin Exp Ophthalmol* 2006;244(12):1638-45.
84. Lim JW, Ryu SJ, Shin MC. The effect of intravitreal bevacizumab in patients with acute central serous chorioretinopathy. *Korean J Ophthalmol* 2010;24(3):155-8.
85. Beger I, Koss MJ, Koch F. [Treatment of central serous chorioretinopathy: MicroPulse photocoagulation versus bevacizumab]. *Ophthalmologe* 2012;109(12):1224-32.
86. Pitcher JD, 3rd, Witkin AJ, DeCroos FC, Ho AC. A prospective pilot study of intravitreal aflibercept for the treatment of chronic central serous chorioretinopathy: the CONTAIN study. *Br J Ophthalmol* 2015;99(6):848-52.
87. Pikkell J, Beiran I, Ophir A, Miller B. Acetazolamide for central serous retinopathy. *Ophthalmology* 2002;109(9):1723-5.
88. Browning DJ. Nadolol in the treatment of central serous retinopathy. *Am J Ophthalmol* 1993;116(6):770-1.
89. Rahbani-Nobar MB, Javadzadeh A, Ghojzadeh L, et al. The effect of *Helicobacter pylori* treatment on remission of idiopathic central serous chorioretinopathy. *Mol Vis* 2011;17:99-103.
90. Dang Y, Mu Y, Zhao M, et al. The effect of eradicating *Helicobacter pylori* on idiopathic central serous chorioretinopathy patients. *Ther Clin Risk Manag* 2013;9:355-60.
91. Nielsen JS, Jampol LM. Oral mifepristone for chronic central serous chorioretinopathy. *Retina* 2011;31(9):1928-36.

92. Caccavale A, Romanazzi F, Imparato M, et al. Low-dose aspirin as treatment for central serous chorioretinopathy. *Clin Ophthalmol* 2010;4:899-903.
93. Kurup SK, Oliver A, Emanuelli A, et al. Low-dose methotrexate for the treatment of chronic central serous chorioretinopathy: a retrospective analysis. *Retina* 2012;32(10):2096-101.
94. Schatz H, Yannuzzi LA, Gitter KA. Subretinal neovascularization following argon laser photocoagulation treatment for central serous chorioretinopathy: complication or misdiagnosis? *Trans Sect Ophthalmol Am Acad Ophthalmol Otolaryngol* 1977;83(5):893-906.
95. Gilbert CM, Owens SL, Smith PD, Fine SL. Long-term follow-up of central serous chorioretinopathy. *Br J Ophthalmol* 1984;68(11):815-20.
96. Lavinsky D, Cardillo JA, Melo LA, Jr., et al. Randomized clinical trial evaluating mETDRS versus normal or high-density micropulse photocoagulation for diabetic macular edema. *Invest Ophthalmol Vis Sci* 2011;52(7):4314-23.
97. Framme C, Walter A, Berger L, et al. Selective Retina Therapy in Acute and Chronic-Recurrent Central Serous Chorioretinopathy. *Ophthalmologica* 2015;234(4):177-88.
98. Chan WM, Lim TH, Pece A, et al. Verteporfin PDT for non-standard indications--a review of current literature. *Graefes Arch Clin Exp Ophthalmol* 2010;248(5):613-26.
99. Photodynamic therapy of subfoveal choroidal neovascularization in age-related macular degeneration with verteporfin: one-year results of 2 randomized clinical trials--TAP report. Treatment of age-related macular degeneration with photodynamic therapy (TAP) Study Group. *Arch Ophthalmol* 1999;117(10):1329-45.
100. Schmidt-Erfurth U, Laqua H, Schlotzer-Schrehard U, et al. Histopathological changes following photodynamic therapy in human eyes. *Arch Ophthalmol* 2002;120(6):835-44.
101. Lim JJ, Glassman AR, Aiello LP, et al. Collaborative retrospective macula society study of photodynamic therapy for chronic central serous chorioretinopathy. *Ophthalmology* 2014;121(5):1073-8.
102. Maruko I, Iida T, Sugano Y, et al. Subfoveal choroidal thickness after treatment of central serous chorioretinopathy. *Ophthalmology* 2010;117(9):1792-9.
103. Manabe S, Shiragami C, Hirooka K, et al. Change of regional choroid thickness after reduced-fluence photodynamic therapy for chronic central serous chorioretinopathy. *Am J Ophthalmol* 2015;159(4):644-51.
104. Schlotzer-Schrehardt U, Viestenz A, Naumann GO, et al. Dose-related structural effects of photodynamic therapy on choroidal and retinal structures of human eyes. *Graefes Arch Clin Exp Ophthalmol* 2002;240(9):748-57.
105. Chan WM, Lam DS, Lai TY, et al. Choroidal vascular remodelling in central serous chorioretinopathy after indocyanine green guided photodynamic therapy with verteporfin: a novel treatment at the primary disease level. *Br J Ophthalmol* 2003;87(12):1453-8.
106. Vasconcelos H, Marques I, Santos AR, et al. Long-term chorioretinal changes after photodynamic therapy for chronic central serous chorioretinopathy. *Graefes Arch Clin Exp Ophthalmol* 2013;251(7):1697-705.

107. Ma J, Meng N, Xu X, et al. System review and meta-analysis on photodynamic therapy in central serous chorioretinopathy. *Acta Ophthalmol* 2014;92(8):e594-601.
108. Chan WM, Lai TY, Lai RY, et al. Safety enhanced photodynamic therapy for chronic central serous chorioretinopathy: one-year results of a prospective study. *Retina* 2008;28(1):85-93.
109. Chan WM, Lai TY, Lai RY, et al. Half-dose verteporfin photodynamic therapy for acute central serous chorioretinopathy: one-year results of a randomized controlled trial. *Ophthalmology* 2008;115(10):1756-65.
110. Wu ZH, Lai RY, Yip YW, et al. Improvement in multifocal electroretinography after half-dose verteporfin photodynamic therapy for central serous chorioretinopathy: a randomized placebo-controlled trial. *Retina* 2011;31(7):1378-86.
111. Smretschnig E, Ansari-Shahrezaei S, Hagen S, et al. Half-fluence photodynamic therapy in chronic central serous chorioretinopathy. *Retina* 2013;33(2):316-23.
112. Nicolo M, Eandi CM, Alovisi C, et al. Half-fluence versus half-dose photodynamic therapy in chronic central serous chorioretinopathy. *Am J Ophthalmol* 2014;157(5):1033-7.
113. Kim YK, Ryoo NK, Woo SJ, Park KH. Comparison of visual and anatomical outcomes of half-fluence and half-dose photodynamic therapy in eyes with chronic central serous chorioretinopathy. *Graefes Arch Clin Exp Ophthalmol* 2015.
114. Shiode Y, Morizane Y, Kimura S, et al. Comparison of halving the irradiation time or the verteporfin dose in photodynamic therapy for chronic central serous chorioretinopathy. *Retina* 2015;35(12):2498-504.
115. Herold TR, Prause K, Wolf A, et al. Spironolactone in the treatment of central serous chorioretinopathy - a case series. *Graefes Arch Clin Exp Ophthalmol* 2014;252(12):1985-91.
116. Daruich A, Matet A, Dirani A, et al. Oral mineralocorticoid-receptor antagonists: real-life experience in clinical subtypes of nonresolving central serous chorioretinopathy with chronic epitheliopathy. *Translational vision science & technology* 2016;5(2):2.
117. Lai TY, Chan WM, Li H, et al. Safety enhanced photodynamic therapy with half dose verteporfin for chronic central serous chorioretinopathy: a short term pilot study. *Br J Ophthalmol* 2006;90(7):869-74.
118. Valmaggia C, Haueter I, Niederberger H. Photodynamic therapy in the treatment of persistent central serous chorioretinopathy: a two-year follow-up. *Klin Monbl Augenheilkd* 2012;229(4):323-6.
119. Nicolo M, Zoli D, Musolino M, Traverso CE. Association between the efficacy of half-dose photodynamic therapy with indocyanine green angiography and optical coherence tomography findings in the treatment of central serous chorioretinopathy. *Am J Ophthalmol* 2012;153(3):474-80 e1.
120. Salehi M, Wenick AS, Law HA, et al. Interventions for central serous chorioretinopathy: a network meta-analysis. *Cochrane Database Syst Rev* 2015;12:CD011841.
121. Weber BH, Charbel Issa P, Pauly D, et al. The role of the complement system in age-related macular degeneration. *Dtsch Arztebl Int* 2014;111(8):133-8.
122. Holz FG, Strauss EC, Schmitz-Valckenberg S, van Lookeren Campagne M. Geographic atrophy: clinical features and potential therapeutic approaches. *Ophthalmology* 2014;121(5):1079-91.
123. Buga AM, Margaritescu C, Scholz CJ, et al. Transcriptomics of post-stroke angiogenesis in the aged brain. *Front Aging Neurosci* 2014;6:44.





CHAPTER 6

Summary / Samenvatting

Summary

Chronic central serous chorioretinopathy (CSC) is a disease of the eye with leakage of fluid under the central part of the retina, the macula. The fluid is derived from the choroid underlying the retinal pigment epithelium (RPE). Because of the subretinal fluid collection under the macula, patients can experience complaints of metamorphopsia and blurred vision. Chronic CSC often occurs in men who are relatively young and still professionally active. Other risk factors that have been associated with CSC are the use of corticosteroids and stress. Although chronic CSC is one of the most common maculopathies, little is known about the pathophysiology, the clinical characteristics and the optimal therapy.

The aim of this thesis is to gather more information about the genetic background, the clinical characteristics and the most effective treatment options of this disease. This could lead to new insights in the pathophysiological mechanisms of the disease. In addition, it may aid to more accurate information of patients regarding the clinical course, prognosis, and the optimal treatment approach for chronic CSC.

In **Chapter 1** a general introduction about the anatomy of the eye, and specifically the retina, is given. Also, the different imaging modalities to investigate the retina are discussed. Also, the different imaging modalities to investigate the retina are discussed. Furthermore, the clinical characteristics, the current ideas about the pathophysiology, and treatment options are introduced.

Chapter 2.1 describes one of the first genetic studies performed in a large chronic CSC patient cohort. In this study, genetic variants that are known to be associated with age-related macular degeneration (AMD), were investigated. Despite notable clinical differences, chronic CSC and AMD also share some clinical similarities prompting this genetic exploratory study. All chronic CSC patients were divided in three subgroups (ranging from very typical chronic CSC to atypical, AMD-like CSC) based on the phenotypical presentation on multimodal imaging. DNA collected from 292 chronic CSC patients, 1147 AMD patients, and 1311 healthy controls was analyzed for a range of single nucleotide polymorphisms (SNPs). Besides an already known genetic variant in the Complement factor H (*CFH*) gene, a new association was found with a variant in the *ARMS2* gene. Interestingly, the genetic variants that conferred risk for chronic CSC were protective for AMD, and vice versa. Also, significant differences in the genetic variants were found between the three phenotypic subgroups, illustrating the importance of correct clinical classification.

In **Chapter 2.2** the possible role of the complement system, an essential player in the innate immune system, in chronic CSC was further investigated. The *complement 4* (*C4*) gene, a gene that plays an important role in the classic and lectine pathway of the complement system, was studied. We found a significant association between the copy number of the *C4B* gene and chronic CSC. Individuals who carry no copies of *C4B* have an increased risk of

chronic CSC, whereas carrying three copies of *C4B* appeared to be protective. These genetic findings suggest that the complement system may play a pathophysiological role in chronic CSC.

In **Chapter 3.1** the clinical course of chronic CSC was investigated in a follow-up study in 52 eyes of 26 patients. Also, the impact of chronic CSC on the vision-related quality of life was analysed. The results show that chronic CSC is a progressive disease in many patients, causing a decrease in visual acuity, accompanied by a lower reported vision-related quality of life. In deciding whether or not to treat chronic CSC, the progressive nature of CSC should be taken into account.

Chapter 3.2 demonstrates that optical coherence tomography may not only be used to monitor the subretinal fluid in chronic CSC, but may aid in the prediction of the treatment response. The OCT characteristics of the subretinal fluid pocket of 48 eyes of treatment naive chronic CSC patients were analysed using a semi-automated computer program. All patients were subsequently treated with half-dose photodynamic therapy (PDT), and the treatment response was recorded. Variations within the OCT characteristics of the subretinal fluid appearance seem to be of predictive value for the treatment response to half-dose PDT.

In **Chapter 3.3** the new technique of OCT angiography was used to illustrate abnormalities in the flow patterns at the level of the choriocapillaris in chronic CSC patients. These irregularities corresponded to abnormalities that were seen on indocyanine green angiography. The abnormalities on OCT angiography in chronic CSC consisted of local areas of reduced flow surrounded by hyperperfusion. This may lead to focal ischemia of the choriocapillaris with hyperperfusion, eventually leading to leakage of serous fluid into the subretinal space.

Chapter 4 describes multiple studies on the treatment of chronic CSC.

Chapter 4.1 presents the results of a prospective treatment protocol that was conducted in a period of 18 months. In this protocol, chronic CSC patients were first treated with half-dose PDT, followed by a second half-dose PDT treatment in the case of persistent serous subretinal fluid. In case of persistent fluid leakage despite these two PDT treatments, a high-density subthreshold micropulse laser treatment was performed. This protocol led to a positive treatment result, defined as a complete resolution of subretinal fluid, in 80% of the cases, in which the visual acuity also increased after treatment. The first half-dose PDT treatment had the highest likelihood of a favorable treatment response and an increase in visual acuity. The use of corticosteroids is known to be associated with chronic CSC, but it is unknown if corticosteroid use as an exogenous factor influences the response of chronic CSC to treatment with PDT.

In **Chapter 4.2** we investigated if patients suffering from corticosteroid-associated chronic CSC respond differently to half-dose PDT treatment as compared to chronic CSC patients

without previous or current corticosteroid use. Possible differences between these patients groups could indicate different pathophysiological pathways. The study found no significant difference between both groups when looking at the percentage of complete resorption of the serous subretinal fluid after PDT treatment. Continuation of corticosteroids at the time of PDT treatment also did not seem to adversely affect response to PDT. Therefore, PDT treatment appears to be a viable and effective treatment option also in patients with chronic CSC associated with corticosteroid use. There is no consensus on the optimal treatment for CSC, and a broad range of therapies have been applied without a well-designed prospective randomized study design.

In **Chapter 4.3** the protocol of the first multicenter prospective randomized controlled treatment trial in chronic CSC, comparing half-dose PDT with high-density subthreshold micropulse laser treatment is described. In this unique investigator-initiated treatment trial, 156 chronic CSC patients will be recruited for randomized treatment. All patients will be examined extensively using multimodal imaging, as well as additional tests such as microperimetry and questionnaires. After inclusion, patients will be randomized into one of the two treatment arms, resulting in two equal treatment groups of which the visual, anatomical and functional treatment results will be compared. The aim of this study is to shed more light on the preferred treatment for chronic CSC patients, by comparing these two modalities that appear the most hopeful according to current literature. The results of this study may also aid in reaching an international consensus regarding the optimal therapeutic approach in chronic CSC, something that is currently lacking.

Finally, in **Chapter 4.4** we describe the use of eplerenone, an orally administered mineralocorticoid receptor antagonist, in patients with long-standing treatment-resistant chronic CSC. Five patients were included in this pilot study, who used eplerenone for 5 weeks. In contrast to the positive response reported in recent literature, this pilot study showed a positive effect with complete resolution of the serous fluid pocket only in one patient. This indicates that eplerenone may have a beneficial effect only in a minority of patients with long-standing treatment-resistant chronic CSC.

Chapter 5 is a general discussion of the main finding of this thesis, in which the study results are put into a broader perspective. An overview of the etiology and known risk factors is given, followed by discussion of the possible implications of the genetic associations that were identified. In addition, the different treatment modalities described in the current literature are discussed and compared to the results found in this thesis. Finally, future studies are proposed that may aid in unravelling the still mysterious entity of chronic CSC.

Samenvatting

Chronische centrale sereuze chorioretinopathie (CSC) is een aandoening van het oog waarbij lekkage van vocht onder het centrale deel van de retina, de macula, optreedt. Dit vocht is het gevolg van vochtlekage vanuit het onderliggende vaatvlies, de choroidea, door een dysfunctioneel retinaal pigment epitheel. Door dit subretinale vocht kunnen patiënten last hebben van vervorming van het beeld en minder scherp zien. Chronische CSC komt met name voor bij mannen van middelbare leeftijd. Andere beschreven risico's voor CSC zijn het gebruik van corticosteroiden en stress. Hoewel chronische CSC één van de meest voorkomende maculopathiën is, is nog lang niet alles bekend over het ziektemechanisme, de klinische kenmerken en de optimale behandeling.

Het doel van dit proefschrift is daarom meer kennis te verkrijgen over de genetische achtergrond en mogelijke geassocieerde ziektemechanismen, de klinische kenmerken en meest effectieve behandeling van deze veelvoorkomende oogaandoening. Een beter inzicht in deze aspecten kan zo bijdragen aan een betere voorlichting voor patiënten over het klinische beloop en de prognose, en aan een betere behandeling van chronische CSC gericht op het ziektemechanisme.

In **Hoofdstuk 1** wordt een algemene introductie gegeven over de anatomie van het oog, in het bijzonder van de retina, en de verschillende onderzoekstechnieken die gebruikt worden om de structuur van het netvlies te onderzoeken. Tevens worden de klinische kenmerken, de huidige ideeën over de ziektemechanismen en de behandelwijzen van CSC besproken.

Hoofdstuk 2.1. beschrijft één van de eerste genetische studies in een groot cohort van chronische CSC patiënten. Omdat chronische CSC en leeftijdsgebonden maculadegeneratie (LMD) klinisch erg op elkaar kunnen lijken, werden genetische varianten onderzocht waarvan al uitgebreid bekend is dat zij een rol spelen bij LMD. Er werd vervolgens gekeken naar het verband tussen de klinische kenmerken en de gevonden genetische associaties. De chronische CSC patiënten werden hiervoor op basis van de typische kenmerken op de klinische beeldvorming ingedeeld in 3 groepen. Voor deze studie werd het genetische materiaal uit het bloed van 292 chronische CSC patiënten, 1147 patiënten met LMD en 1311 gezonde controles met elkaar vergeleken. Naast een reeds bekende genetische variant in het *Complement factor H (CFH)* gen, werden ook associaties gevonden met een variant in het *ARMS2* gen. De genetische varianten waarvan bekend is dat ze een beschermend effect hebben voor LMD bleken risicoverhogend te zijn voor chronische CSC en vice versa. Daarnaast verschilden de 3 chronische CSC patiënten groepen significant voor deze genetische varianten, waarmee de noodzaak van juiste fenotypering wordt benadrukt.

In **Hoofdstuk 2.2** is nader onderzoek verricht naar een mogelijke betrokkenheid van het complement systeem, een onderdeel van het aangeboren immuunsysteem bij de pathogenese van chronische CSC. Er werd gekeken naar het *complement 4 (C4)* gen,

dat zowel een belangrijke rol speelt in de klassieke route als in de lectine route van het complement systeem. Uit de analyses kwam naar voren dat het aantal kopieën van *C4B* significant geassocieerd is met chronische CSC. Personen die geen kopieën van *C4B* dragen hebben een verhoogd risico op chronische CSC, terwijl personen met 3 kopieën van *C4B* juist minder risico lijken te hebben op het ontwikkelen van chronische CSC. Deze genetische bevindingen suggereren dat, net zoals bij LMD, het complementsysteem betrokken is bij het ontstaan van chronische CSC.

In **Hoofdstuk 3.1** is gekeken naar het klinisch beloop en de prognose van chronische CSC in een follow-up studie van 52 ogen van 36 patiënten met chronische CSC. Daarnaast werd gekeken naar de impact die de ziekte heeft op de visus-gerelateerde kwaliteit van leven. De resultaten laten zien dat chronische CSC een progressieve oogziekte is die geassocieerd is met een langzame achteruitgang van de visus, resulterend in een verminderde visus-gerelateerde kwaliteit van leven. Het is belangrijk dat de oogarts deze bevindingen meeneemt in de overwegingen of een patiënt behandeld zou moeten worden of niet.

Hoofdstuk 3.2 laat zien dat optische coherentie tomografie (OCT) bij chronische CSC niet alleen ingezet kan worden als diagnostisch middel om het subretinale vocht vast te stellen en te vervolgen, maar mogelijk ook kan helpen om de behandelrespons te voorspellen. De OCT karakteristieken van de sereuze vochtblaas in de ogen van 48 chronische CSC patiënten die nog geen behandeling hadden gehad, werden met een semi-geautomatiseerd programma geanalyseerd. Vervolgens werden deze patiënten behandeld met een halve-dosis fotodynamische therapie (PDT) en werd gekeken hoe zij op deze behandeling reageerden. Variaties in de OCT karakteristieken van de sereuze vochtblaas bleken een voorspellende waarde te hebben voor de behandelrespons op PDT.

Naast de reguliere OCT-scan werd ook een nieuwe techniek, de angio-OCT, getest in patiënten met chronische CSC. In **Hoofdstuk 3.3** wordt beschreven dat met behulp van deze nieuwe techniek afwijkingen in de bloedstroom van de choriocapillaris kunnen worden aangetoond bij chronische CSC patiënten. Deze afwijkingen komen overeen met afwijkingen die gezien kunnen worden met indocyanine-groen angiografie. De afwijkingen bestaan uit focale gebieden met een verlaagde stroomsnelheid, omgeven door een gebied met hyperperfusie. Dit kan mogelijk duiden op focale ischemie van de choriocapillaris met hyperperfusie die vervolgens kan leiden tot de typische lekkage van sereus vocht onder het netvlies in CSC patiënten.

Hoofdstuk 4 beschrijft verschillende studies naar de behandel mogelijkheden van chronische CSC. In **Hoofdstuk 4.1** worden de resultaten besproken van een prospectief behandelprotocol dat gedurende anderhalf jaar werd uitgevoerd. In dit protocol werden patiënten eerst behandeld met halve-dosis PDT. Indien nodig werd deze behandeling nogmaals herhaald. Bij uitblijven van behandel succes na 2 halve-dosis PDT behandelingen werd een micropulse laser behandeling toegepast. Dit protocol leidde in 80% van de gevallen tot een goed


resultaat, waarbij ook een verbetering van de visus werd gezien. Vastgesteld werd echter ook dat de eerste halve-dosis PDT behandeling de hoogste kans bood op een goede reactie en daarmee de beste verbetering in visus opleverde.


Het gebruik van corticosteroiden is sterk geassocieerd met het krijgen van chronische CSC, maar omgekeerd gebruiken lang niet alle chronische CSC patiënten corticosteroiden. Daarom wordt in **Hoofdstuk 4.2** ingegaan op de vraag of patiënten met corticosteroidgeassocieerde chronische CSC, anders reageren op een PDT behandeling dan patiënten die geen corticosteroiden gebruiken. Verschillen hierin zouden kunnen duiden op een ander ziektemechanisme in beide groepen. In onze studie vonden we geen significant verschil tussen beide groepen als we keken naar het percentage patiënten waarbij de sereuze vochtblaas volledig was verdwenen na de behandeling. Hierbij leek het in de door ons onderzochte patiëntengroep ook niet uit te maken of men de corticosteroiden tijdens de behandeling nog doorgebruikte, of dat men de corticosteroiden stopte. In patiënten die corticosteroiden hebben gebruikt en/of deze niet kunnen stoppen vanwege medische noodzaak blijkt dat PDT een effectieve behandeling is ondanks deze veronderstelde externe risicofactor. Deze resultaten zijn ook een aanwijzing dat chronische CSC in deze patiëntengroepen door een soortgelijk ziektemechanisme wordt veroorzaakt.

In **Hoofdstuk 4.3** beschrijven wij het protocol van de eerste multicenter prospectieve randomized controlled trial die halve-dosis PDT direct vergelijkt met micropulse laser therapie voor chronische CSC. In deze unieke door onderzoekers geïnitieerde behandel-trial zullen 156 chronische CSC patiënten geïnccludeerd worden. Alle patiënten worden met uitgebreide beeldvorming en aanvullend onderzoek in kaart gebracht en krijgen met behulp van een randomisering-programma een behandeling toegewezen. Uiteindelijk zullen er twee even grote behandelgroepen ontstaan waarbij de behandelresultaten met elkaar vergeleken zullen worden. Met deze zogenaamde PLACE-studie wordt getracht meer inzicht te krijgen in de effectiviteit van halve-dosis PDT en micropulse laser therapie, de behandelmethoden die tot op heden het meest effectief lijken voor behandeling van chronische CSC. Het streven is dat de studie zal bijdragen aan de ontwikkeling van een tot op heden ontbrekende internationale consensus en behandelrichtlijn voor chronische CSC.

Tot slot wordt in **Hoofdstuk 4.4** de toepassing beschreven van een nieuw medicijn bij chronische CSC patiënten die eerder niet reageerden op behandelingen zoals PDT en micropulse laser. Aan deze pilot studie deden 5 patiënten mee, die gedurende 5 weken het middel eplerenon innamen. In tegenstelling tot sommige positieve resultaten die beschreven zijn in andere kleine studies, werd er in deze pilot-studie slechts bij één van de patiënten een volledige afname van de sereuze vochtblaas gezien. Dit suggereert dat eplerenon, ondanks dat het goed verdragen wordt, van beperkt nut is voor patiënten die eerder ook niet reageerden op andere behandelingen.

De belangrijkste bevindingen van dit proefschrift worden in **Hoofdstuk 5** samengevat en in een breder perspectief bediscussieerd. Na een samenvatting van de etiologie en de bekende risicofactoren, komt de mogelijke rol van de nieuwe genetische bevindingen aan de orde. Tevens worden de verschillende behandelmogelijkheden uit de recente literatuur besproken en vergeleken met de resultaten uit dit proefschrift. Tot slot worden mogelijke toekomstige studies besproken die verder inzicht kunnen geven op het na anderhalve eeuw nog altijd mysterieuze ziektebeeld chronische CSC.





CHAPTER 7

Dankwoord

Dankwoord

Daar zit je dan met enkele duizenden woorden op papier, woorden die in de afgelopen 4 jaar op zijn plek zijn gevallen. Niet alleen door de mensen die direct betrokken zijn geweest bij mijn onderzoek, maar ook zeker door alle mensen die me vanaf buiten hebben gesteund en mee zijn gegaan in dit avontuur. De enige woorden die dan nog missen, zijn misschien wel de belangrijkste woorden van dit geheel: de woorden van dank. Ook al kun je sommige dingen niet volledig met woorden omvatten en zijn woorden niet helemaal ‘mijn ding’, wil ik toch proberen één ieder die mij zover heeft laten komen te bedanken.

Prof. dr. C.B. Hoyng, beste Carel, toen ik begon met mijn project was serosa eigenlijk een ondergeschoven stiefbroertje van de AMD. Hoe dan ook, het was steeds duidelijk dat als puntje bij paaltje komt, ik altijd van je op aan kan. Bedankt voor de stabiliteit en de mogelijkheden die jij hebt weten te scheppen voor het onderzoek naar CSC. Het is mooi om ook jouw ogen af en toe te zien glunderen als het om CSC gaat.

Prof. dr. J.E.E. Keunen, beste Jan, met jou begon mijn avontuur in Nijmegen. De veilige basis die je vanaf het begin af aan uitstraalde gaf mij een gerust gevoel om zonder twijfel de stap naar Nijmegen te maken. Door jou draaide mijn onderzoek niet alleen om ‘significante resultaten’, maar ook om de patiënten achter deze resultaten. Dank voor jouw relativeringsvermogen en persoonlijke interesse, gecombineerd met de gevarieerde intermezzo’s tijdens mijn onderzoeksperiode.

Prof. dr. A.I. den Hollander, beste Anneke, de rust die jij zelfs in het heetst van de strijd kunt uitstralen doet mij keer op keer versteld staan en bewonder ik zeer. Ook al stond jij tijdens mijn promotie traject niet direct op de voorgrond, het was al snel duidelijk dat jij alles nauwlettend in de gaten hield achter de schermen. Daar waar wij als klinici vaak in rondjes bleven draaien, wist jij ons met je kritische blik weer op het rechte pad te zetten. Vooral in de afsluitende fase heb ik je sturende en begeleidende kant steeds meer mogen ervaren en ik had deze niet kunnen en willen missen, waarvoor veel dank.

Prof. dr. C.J.F. Boon, beste Camiel, ik ben meer dan vereerd met het feit jij mijn ‘kwartet’ compleet hebt gemaakt. Ondanks dat wij elkaar fysiek weinig in hetzelfde ziekenhuis hebben getroffen, wist ik dat je altijd met raad en daad voor me klaarstond, niet alleen als ‘begeleider’ maar ook als ‘persoon’. Geen mail te veel, geen tijdstip te bont en geen afstand te ver. Dank voor jouw tomeloze inzet, inspiratie, kennis en bemoedigende woorden die ik vooral in de laatste periode erg nodig heb gehad om dit werk zo neer te zetten als het nu voor ons ligt. Het is mooi om te zien dat alle uren van grading, randomiseren en reviseren geleid hebben tot vele mooie projecten.

Als iemand het mysterie achter de ‘serosa’ kan ontrafelen dan ben jij het!

Dr. K. Brasse, lieber Karl, ohne deine Ausdauer wäre ich vielleicht nie überzeugt für die Augenheilkunde, ich danke dir für die lehrreiche und vor allem angenehme Zeit in deiner Praxis.

Drs. J.K. Mohr-Karsenberg, beste Jacqueline jouw voorwerk heeft mij op weg gebracht. Ik vind het jammer dat ik je maar heel even als assistent heb mogen meemaken. Desalniettemin, was je altijd even enthousiast en geïnteresseerd op de momenten dat wij elkaar tegen kwamen, wat me motiveerde ons onderzoek tot een goed eind te brengen.

Beste Lex, bedankt voor al je monnikenwerk en coördinatie met ons project hier en in Oxford.

Lieve mensen van de administratie, zonder jullie hulp in de planning en jullie vele bezoeken aan de promovendi kamer, zouden vele patiënten de weg naar en op de poli niet gevonden hebben voor mijn onderzoek en zou mijn 'privé' archief niet hebben kunnen bestaan. Bedankt voor het puzzelen en alle zoektochten naar statussen.

Lieve mensen van de verpleegpost, ik moet toegeven dat als ik even niet wist/weet hoe ik iets voor elkaar moet krijgen, ik vaak gewoon even bij jullie langs loop, want oplossingen vinden is jullie tweede natuur (daarnaast is het natuurlijk altijd gewoon erg leuk om even langs te lopen). Bedankt voor de 'extraatjes' en tussentijdse bloedafnames ook al was/is er niet altijd evenveel tijd voor.

Beste dames van trial, lieve Maria en Anne, bedankt voor al de planning en het administratieve werk.

Beste optometristen, door jullie beschikken we vandaag de dag over enorme hoeveelheid en variatie aan imaging van patiënten, iets wat voor mijn onderzoek van essentieel belang is geweest. Ik weet dat ik jullie vaker dan eens heb opgezadeld met nog 'even wat aanvullende scans', bedankt voor jullie flexibiliteit!

Asha, jou wil ik speciaal bedanken. Zonder jouw overgave voor de studie, was alle energie die wij in de PLACE hebben gestoken voor niets geweest!

Beste Berna, Francis, Laura, Mara en ten tijde van mijn promotie Bart, Karlijn en Charlotte het is fijn dat jullie onze staf zo goed in de gaten houden en hun agenda's plannen. Ik weet dat ik menigeen horendol heb weten te maken met last-minute meetings in agenda's die per definitie al 100% overboekt zijn. Toch lukt het jullie steeds weer een plekje voor ons te creëren. Bedankt voor alle flexibiliteit en ook voor de interesse in ons allen. Een praatje met jullie maakte het tussentijds koffie halen des te leuker en meer ontspannen.

Beste Bjorn, Eiko, Bert en Frederieke, bedankt voor de uren die jullie in het serosa project hebben gestoken, zonder jullie structuur en ideeën was het een rommeltje geworden.

Drs. J.M. Groenewoud, beste Hans, jij was voor mij de 'Araschnia levana' als het om de statistiek gaat. 'Geen resultaat' komt niet voor in jouw vocabulair, ook al waren sommige resultaten voor ons soms erg bedroevend, jij wist er altijd een positieve draai aan te geven. Bedankt voor je rust, chocolade en vooral voor je statistische analyse op de momenten dat ik ze soms allemaal niet meer op een rijtje had.

Tijdens mijn promotie traject heb ik de kans gekregen mee te werken aan het opzetten van een unieke trial: de PLACE-trial. Dit proces was niet alleen erg leerzaam (soms leek het een ware hordenloop), maar ging ook samen met het leren kennen en samenwerken met unieke personen uit verschillende landen.

Oxford; Dear prof. dr. R.E. Maclaren and dr. S. Downes, Dear Robert and Susan, thank you for the opportunity to bring the PLACE-trial to Oxford. Thank you, dear Alexina Fantato and dear Daniel Buttress for all the organising work behind the scenes. Also many thanks to all the members of the research team involved in the PLACE trial.

Paris; Cher prof. dr. E.H. Souied et dr. G. Querques, j'aimerais adresser ma gratitude pour le service que vous m'avez rendu en accueillant le trial PLACE dans votre clinique. Chère dr. Blanco-Garavito, chère Rocio, merci pour votre enthousiasme et votre zèle (et pour votre avis d'aligot ;)). Merci à tous ceux qui nous ont aidé lors du trial à Paris

Köln; Sehr geehrter Herr Prof. Dr. Fauser, lieber Sascha, die PLACE-Studie war nicht unsere erste Zusammenarbeit zwischen Köln und Nijmegen. Deswegen fühlt es sich bei euch schon fast so an, als würde man nach Hause kommen. Herzlichen Dank für die vielen interessanten Besprechungen und die großartige Mitarbeit an der PLACE-Studie. Sehr geehrte Frau Franken, Liebe Katharina, sehr geehrte Frau Neumann, Frau Prinz und Frau Dr. Scholz, liebe Paula, und allen anderen, die bei der Studie mitgeholfen haben, herzlichen Dank für Ihre/eure Mühe, Flexibilität und Einsatz für dieses Projekt!

Leiden; Beste dr. Dijkman, beste Greet, bedankt voor het mogelijk maken van de studie in Leiden. Beste dames van het trial centrum in Leiden, bedankt voor jullie hulp bij het opzetten en het coördineren van de studie in Leiden, zonder jullie zaten we nu nog bij de METC. Tot slot dank al alle optometristen en verpleegkundigen die zich voor de PLACE studie in de nodige bochten hebben weten te wringen.

Roos, Elon en Danial, mede door jullie heeft het onderzoek naar CSC een grote toekomst. Beste Elon, de energie waarmee jij het onderzoek bent ingedoken en de snelheid waarmee je doordendert is af en toe beangstigend, maar ook zeer bewonderenswaardig. Ik denk dat er geen betere opvolger van het project en vooral ook de PLACE-trial had kunnen zijn dan jij. Samen met Danial (en waarschijnlijk zullen er nog vele promovendi volgen) houdt jij de zaak onder controle in het 'Leidse'. Vol spanning zal ik jullie onderzoeken blijven volgen!

Lieve Roos, door jou zit er weer leven in het onderzoek naar de genetische achtergrond van CSC. Op sommige vlakken kun je niet meer verschillen dan wij, soms wat onhandig maar vooral ook soms erg fijn. Ik denk dat we elkaar daarmee goed aanvullen, niet alleen op de werkvloer maar ook in ons gedeelde huis. Bedankt voor je altijd vrolijke aanwezigheid, ook als ik me soms liever even afsluit, waarmee je me helpt herinneren aan de essentiële dingen in het leven!

Dank aan mijn mede promovendi op de kamer die POG-en, WOG-en en SOG-en aangenaam en zeer makkelijk maakten. Ramon bedankt voor je muzikale begeleiding. Michel bedankt voor je andere kijk op dingen en dank dat jij zonder er ooit over te klagen altijd voor ons de algemene telefoon op nam. Yara en Freekje bedankt voor jullie kennis, gezelligheid (ook 's avonds bij de pubquiz) en informatie over alle online sales. Constantin thank you for thinking out of the box! Nicole bedankt voor je 'twentse' nuchterheid, door jou voelde het bijna als thuis. Freerk bij jou weet ik nog niet zo goed of ik je moet bedanken voor alle RSI of misschien toch vervloeken, de toekomst zal het leren. Hoe dan ook bedankt voor de gezellige momenten, graden naast jou was nooit saai! Nathalie bedankt voor je vrolijke aanwezigheid na een goede kop koffie en Stanley bedankt voor het delen van jouw technische kennis, ik had soms graag wat van jouw vermogen je af te sluiten meegekregen. Niet alleen op de kamer was het gezellig, daarom ook dank aan de overige (oude en nieuwe) promovendi die de researchmeetings gevarieerd en gezellig maakten: Mark, Bart, Laura, Maartje (160km!), Shazia, Mahesh, Karlijn, Eveline, Sanne, Vivian en Dyon.

Beste AIOS, beste Samuël, Linda, Ann-Laure, Paulien, Carla, John, Dzenita, Anita, Stefan, Ramon, Frank, Jelina, Ellen, Nicole, Yara, Artin, Anna, Nathalie, Mustapha en Martijn, bedankt voor het gespreide bedje dat voor mij als jongste klaar stond, dat samen met het afronden van mijn promotie voelt als voldoende ontgroening. Op naar nog een mooie tijd samen

Lieve familie, lieve vrienden en vriendinnen, ondanks dat promoveren een team-effort is, maakt het je soms zeker niet socialer. Dank aan iedereen die me steeds weer uit mijn sociale isolement heeft weten te trekken op het moment dat ik zelf de tijd en energie niet meer kon opbrengen mezelf te zijn en op alle plekken tegelijk te zijn. Wees gewaarschuwd.. dit was de stilte voor de storm!

(P.S. ik houd nog steeds niet van bellen ;))

Lieve Soof, zo verschillend maar toch ook zo gelijk, ik hoop nog veel van de wereld samen met jou te zien en te beleven!

Lieve Eef, de stabiele factor ben je tijdens onze studententijd altijd al geweest en blijf je nog altijd voor mij. Fijn dat je er bent!

Lieve Lot, het is zo leuk dat 'MYLO' ook in Nijmegen voortbestaat.

Lieve Marianne, ik ken niemand die zo lief en zorgzaam is voor anderen als jij, je bent een schatje!

Lieve Anneloes, thanks for stalking me!

Lief Kippie, wat vliegt de tijd en wat schiet afspreken er toch soms bij in, toch is het fijn dat wij 'zusjes' zijn!

Lieve Nonche, bedankt voor de altijd gezellige avondjes, je interesse en je energie.

Lieve Jelina, dank je voor de adoptie en de fijne avondjes op de rode bank.

Liebe Kathrin und Esther, ohne euch ist Urlaub in Frankreich kein richtiger Urlaub!

Lieve 'Hoogstraatjers', beste Iliana, Wiets en Kas, bedankt voor het altijd luisterende oor, de altijd open deur en vooral de gezelligheid. Beter een goede buur dan een verre vriend, laten we er nog vele pannenkoeken op eten!

Lief Kick-spin-fit-team, of misschien hadden we het beter Kick-spin-fit-gin-tonic-green-ice-tea-team kunnen noemen, zonder jullie had ik een hoop gezellige momenten in Nijmegen gemist. Bedankt voor jullie 'atletische' inzet binnen en buiten de sportschool.

Lieve vogels, ik ben zo blij dat jullie er zijn en zonder jullie waren de afgelopen jaren een stuk minder leuk en een stuk stressvoller geweest. Met jullie maak je alles mee (ook al heb ik daar vooral het afgelopen jaar te veel van moeten missen..!) Een vogel hoort op de berg!

Lieve paranimfen, lieve Hanna Mai en lieve Ellen, ik ben blij dat jullie tijdens mijn promotie aan mijn zijde zullen staan.

Lieve Mai, een peptalk staat jou op het lijf geschreven en gelukkig lijdt jij net als ik aan chronisch tijdgebrek. Ik ben blij dat je mijn vriendinnetje bent!

Mai, rodijs en rosijns zijn zonder jou toch vele malen minder fijn!

Lieve Ellen, altijd positief, begaan en in voor een sportieve activiteit. Bedankt voor het luisteren en het meedenken als dingen niet zo lopen als gepland. Ondanks dat we elkaar pas enkele jaartjes geleden hebben leren kennen, voelt het al als een eeuwigheid, ik ben blij dat ik je ken!


El, samen halen we de top!


Broerlief, zoals jij is er geen (en dat weet jij stiekem ook maar al te goed....). Ondanks dat we elkaar soms liever achter het behang plakken dan gewoon lief tegen elkaar te zijn, ben ik blij

dat jij er altijd voor me bent. Ik denk dat we trots kunnen zijn op elkaar, op wie we zijn en waar we staan en wie weet worden ook wij ooit volwassen!

Lieve mam en pap, als iemand mij als jong meisje had verteld dat ik in de voetstappen van papa zou treden, had ik ze denk ik voor gek verklaard (eigenzinnig als ik toen al was en nog steeds een beetje ben). Blijkbaar hebben de vele uren in de praktijk, het spelen met de apparatuur (want wat was het leuk om een Goldmann keer op keer te doen) en het meespieken bij kleine operaties toch de nodige vruchten afgeworpen. Jullie hebben voor Holger en mij altijd een stabiele basis weten te creëren, ook al ging dit soms ten koste van jullie zelf. Jullie hebben mij geleerd zelf keuzes te maken en ook om te gaan met de (soms minder leuke) consequenties van deze keuzes. De geborgenheid, het vertrouwen en de wetenschap dat jullie er op ieder moment voor ons zijn, hebben mij enorm gesteund in mijn onderzoeksperiode. Mama bedankt voor je analytische en kritische blik en zorgzame liefde. Papa bedankt voor je eindeloze geduld en ongecompliceerde liefde.

Tot slot, in de geneeskunde bestaat er zonder patiënten en proefpersonen geen onderzoek. Ik wil alle patiënten en proefpersonen bedanken voor hun deelname aan ons onderzoek.





CHAPTER 8

Curriculum vitae / List of publications

Curriculum vitae

Myrte Breukink was born on January 1st, 1986 in Enschede, the Netherlands. She completed her secondary school (VWO-certificate, Nature and Health) at 'De Driemark' in Winterswijk and commenced her medical study at the University of Groningen, successfully completing this in 2011. During her medical training she became interested in science and she did research on the complement system and genetics in patients who received a lungtransplant (under the supervision of dr. M.A.J. Seelen and prof. dr. W.J. van Son). Her interest in research and foreign countries was combined in her final year of her medical training in which she took part in research at the Canniesburn Plastic Surgery Unit, Glasgow, Scotland. Here she became more and more enthousiastic about the fine (micro) surgery. From April 2011 untill June 2012 she worked as a resident in ophthalmology at the 'Augenärztliche Praxis Dr. Brasse' and the 'Augenklinik Ahaus', Germany. In this period her interest in ophthalmology grew, leading to an application for a PhD position in the Radboudumc, Nijmegen, that resulted in this thesis. After a research period of 3 years she recommenced her specialisation in ophthalmology in August 2015 at the Radboudumc under the supervision of prof. dr. J.E.E. Keunen and prof. dr. B.J.Klevering.

List of publications

Association between donor MBL promoter haplotype and graft survival and the development of BOS after lung transplantation.

Janna M. Munster, Wim van der Bij, **Myrte B. Breukink**, Gerrit van der Steege, Michael W. Zuurman, Bouke G. Hepkema, Erik A.M. Verschuuren, Wim J. van Son, Marc A.J. Seelen
Transplantation 2008 Dec 27 86(12), pp 1857-1863

Coincidental finding during laparotomy; aberrant appendix

Myrte B. Breukink, L. Lopez
Medisch Contact, 3 december 2009; 64(49): 2056

A functional-MRI paradigm to identify distinct cortical areas of facial function: a reliable localizer

Marco Romeo, Luca Vizioli, **Myrte B. Breukink**, Junpeng Lao, Roberto Caldera, Kiomars Aganloo, Stefano Cotrufo and Stephen Morley
Plast Reconstr Surg. 2013 Apr;131(4):527e-33e

The use of eplerenone in therapy-resistant chronic central serous chorioretinopathy.

Myrte B. Breukink, Anneke I. den Hollander, Jan E.E. Keunen, Camiel J.F. Boon, Carel B. Hoyng
Acta Ophthalmol. 2014 Sep;92(6): e488-90

Chronic central serous chorioretinopathy is associated with genetic variants implicated in age-related macular degeneration.

Eiko K. de Jong, **Myrte B. Breukink**, Rosa L. Schellevis, Bjorn Bakker, Jacqueline K. Mohr-Karsenberg, Sascha Fauser, Jan E. E. Keunen, Carel B. Hoyng, Anneke I. den Hollander, Camiel J.F. Boon
Ophthalmology. 2015 Mar;122(3):562-70

Are intravitreal injections with ultrathin 33-g needles less painful than the commonly used 30-g needles?

Freekje van Asten, Henriët van Middendorp, Samuël Verkerk, **Myrte B. Breukink**, Lomme R.M., Carel B. Hoyng, Andrea W. Evers, B. Jeroen Klevering
Retina. 2015 sep;35(9):1778-85

OCT angiography compared to fluorescein and indocyanine green angiography in chronic central serous chorioretinopathy.

Michel M. Teussink, **Myrte B. Breukink**, Mark J. van Grinsven, Carel B. Hoyng, B. Jeroen Klevering, Camiel J.F. Boon, Eiko K. de Jong, Thomas Theelen
Invest Ophthalmol Vis Sci. 2015 Aug;56(9):5229-37

Genomic copy number variations of the complement component C4B gene are associated with chronic central serous chorioretinopathy.

Myrte B. Breukink, Rosa L. Schellevis, Camiel J.F. Boon, Sascha Fauser, Carel B. Hoyng, Anneke I. den Hollander, Eiko K. de Jong
Invest Ophthalmol Vis Sci. 2015 Aug;56(9):5608-13.

The PLACE trial - Comparing half-dose photodynamic therapy (PDT) with high-density subthreshold micropulse laser (HSML) treatment in patients with chronic central serous chorioretinopathy (cCSC): study protocol for a randomized controlled trial.

Myrte B. Breukink, Susan M. Downes, Giuseppe Querques, Elon H.C. van Dijk, Anneke I. den Hollander, Rocio Blanco-Garavito, Jan. E.E. Keunen, Eric H. Souied, Robert E. MacLaren, Carel B. Hoyng, Sascha Fauser, Camiel J.F. Boon
Trials. 2015 Sep 21;16:419.

Half-dose photodynamic therapy followed by diode micropulse laser therapy as treatment for chronic central serous chorioretinopathy: evaluation of a prospective treatment protocol.

Myrte B. Breukink, Jacqueline K. Mohr-Karsenberg, Annette Ossewaarde-van Norel, Anneke I. den Hollander, Jan. E.E. Keunen., Carel B. Hoyng, Camiel J.F. Boon
Acta Ophthalmol. 2016 Mar;94(2):187-97.

Efficacy of photodynamic therapy in steroid-associated chronic central serous chorioretinopathy: a case-control study.

Myrte B. Breukink, Danial Mohabati, Elon H.C. van Dijk, Anneke I. den Hollander, Eiko K. de Jong, Greet Dijkman, Jan. E.E. Keunen, Carel B. Hoyng, Camiel J.F. Boon
Acta Ophthalmol. 2016 Sep;94(6):565-72.

Chronic central serous chorioretinopathy: long-term follow-up and vision-related quality of life.

Myrte B. Breukink, Alexander J.M. Dingemans, Anneke I. den Hollander, Jan. E.E. Keunen, Robert E. MacLaren, Sascha Fauser, Giuseppe Querques, Carel B. Hoyng, Susan M. Downes, Camiel J.F. Boon
Clinical ophthalmology, accepted

A haplotype in the NR3C2 gene, encoding the mineralocorticoid receptor, is associated with chronic central serous chorioretinopathy.

Elon H.C. van Dijk, Rosa L. Schellevis, Maaïke van Bergen, **Myrte B. Breukink**, Lebriz Altay, Paula Scholz, Sascha Fauser, Onno Meijer, Carel B. Hoyng, Anneke I. den Hollander, Camiel J.F. Boon, Eiko K. de Jong
submitted

STELLINGEN

BEHORENDE BIJ HET PROEFSCHRIFT:

Chronic central serous chorioretinopathy

Studies on the clinical and genetic characteristics

1. De visuswinst is vaak het hoogst na de eerste halve dosering fotodynamische therapie behandeling bij patiënten met chronische centrale sereuze chorioretinopathie.
2. Chronische centrale sereuze chorioretinopathie gaat gepaard met een verminderde visus-gerelateerde kwaliteit van leven.
3. Genetische varianten in *ARMS2* en *CFH* zijn geassocieerd met chronische centrale sereuze chorioretinopathie.
4. Met behulp van adequate fenotypering vindt men significante verschillen in alle frequenties tussen chronische centrale sereuze chorioretinopathie en leeftijdsgebonden maculadegeneratie.
5. Focale ischemie van de choriocapillaris ligt mogelijk ten grondslag aan lekkage van subretinaal sereus vocht bij chronische centrale sereuze chorioretinopathie.
6. Chronische centrale sereuze chorioretinopathie verbreedt je horizon.
7. There is only one PLACE to be!
8. De baten voor de patiënt zijn mede afhankelijk van de onbaatzuchtigheid van de onderzoeker.
9. Promoveren is in Nederland het langste traject om 1 letter verandering door te voeren.
10. Ontlokt een stelling twijfel, dan treft de stelling doel.