

# 2014 Eye Special Tropical Ophthalmology



**Working Group Tropical Ophthalmology  
The Netherlands**

# TABLE OF CONTENT

|                 |                                                                                               |    |
|-----------------|-----------------------------------------------------------------------------------------------|----|
| AIDS            | EYE DISEASES IN HIV/AIDS                                                                      | 2  |
|                 | IMMUNE RECOVERY UVEITIS                                                                       | 25 |
| BLINDNESS       | CHILDHOOD BLINDNESS AND VISION LOSS IN AFRICA                                                 | 8  |
| CATARACT        | AGE RELATED CATARACT                                                                          | 5  |
| CONJUNCTIVA     | CONJUNCTIVITIS OF THE NEWBORN                                                                 | 13 |
|                 | TUMOURS OF THE BULBAR CONJUNCTIVA                                                             | 67 |
| DIABETES        | DIABETES                                                                                      | 20 |
| EQUIPMENT       | MAINTENANCE OF INSTRUMENTS                                                                    | 31 |
|                 | TRANSFORMING A PAPERCLIP INTO AN EYE-OPENER                                                   | 40 |
| EYE EXAMINATION | RED REFLEX AND MORE                                                                           | 47 |
|                 | WHAT TO DO WITH A PATIENT WHO HAS EYE PROBLEMS?                                               | 73 |
| EYELID          | STYE AND OTHER AFFECTIONS OF THE EYELIDS                                                      | 52 |
| GENERAL         | THE SHIFT IN POTENTIALLY BLINDING EYE DISEASE BEFORE AND DURING THE AIDS PANDEMIC IN CAMEROON | 59 |
|                 | VISION 2020, THE RIGHT TO SIGHT                                                               | 69 |
| GLAUCOMA        | GLAUCOMA                                                                                      | 21 |
| ONCHOCERCIASIS  | ONCHOCERCIASIS (RIVER BLINDNESS)                                                              | 33 |
| PREVENTION      | PREVENTION: COMMUNITY-BASED PREVENTION OF CORNEAL BLINDNESS                                   | 10 |
|                 | HOW TO IMPROVE EYE SERVICES IN YOUR AREA                                                      | 27 |
| RED EYE         | RED EYE: ACUTE RED EYES                                                                       | 41 |
|                 | CORNEAL ULCERS                                                                                | 16 |
| REFRACTION      | HOW TO HELP PROVIDE LOW VISION CARE, ESPECIALLY FOR CHILDREN                                  | 28 |
|                 | REFRACTION: THE NEED FOR REFRACTIVE SERVICES IN LOW-INCOME COUNTRIES                          | 49 |
| TRACHOMA        | TRACHOMA                                                                                      | 61 |
| TRAUMA          | TRAUMATIC EYE LESIONS                                                                         | 65 |
| XEROPHTHALMIA   | XEROPHTHALMIA, MEASLES AND MALNUTRITION                                                       | 74 |

# EDITORIAL EYE SPECIAL

In 2002 a Memisa edition was dedicated to ophthalmology. It was used in the ‘Tropical Course’, the preparation for doctors going to low income countries. Now this training is an official specialization: Arts Internationale Gezondheidszorg en Tropengeneeskunde (AIGT). Though most of the content was still relevant, it was felt that a revision was needed.

The first MTb issue in 2014 gives an overview where eye care in low income countries stands now. MTb, Medicus Tropicusi is the official bulletin of the Netherlands Society for Tropical Medicine and International Health. The content of this issue is added to the updated Memisa special.

It is outlined how the ophthalmological world thinks to improve the quality of sight (Vision 2020) There is a special article about the care for children. The last years there has been a shift in eye pathology. This shift is described and 2 articles highlight an important cause, the aids epidemic. There is an example how a simple action in the field can reduce blindness. The important (low income countries) eye diseases are discussed.

All articles put emphasis on what workers in the frontline can do.

We hope that you enjoy this new Eye Special and find it useful. You can also find it on the site of Werkgroep Tropische Oogheelkunde (Working Group Tropical Ophthalmology). <http://www.tropischeoogheelkunde.nl> You can find also some more information there.


The Werkgroep can be reached via e-mail mailto:[secretariaat@tropischeoogheelkunde.nl](mailto:secretariaat@tropischeoogheelkunde.nl)

Jan Geert Bollemeijer, Peter Hardus, Ype Henry, Margreet Hogeweg, Coen Koppert

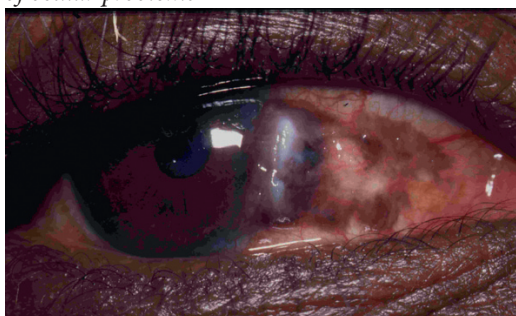
*On the front you see the cover of the Memisa Eye special 2002 combined with measuring the ocular tension with the modern Icare tonometer in a rural setting.*

# EYE DISEASES IN HIV/AIDS – SOME PRACTICAL TOOLS FOR DIAGNOSIS AND TREATMENT

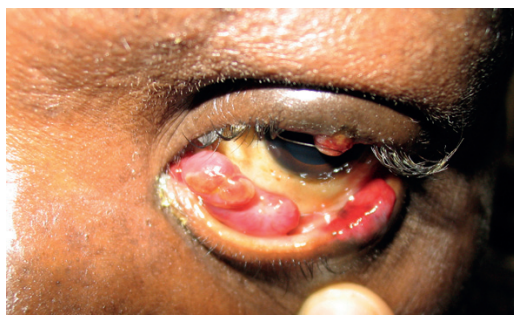JAN GEERT BOLLEMEIJER MD, OPHTHALMOLOGIST,  
Rotterdam Eye Hospital, formerly Zimbabwe  
e-mail [j.bollemeijer@oogziekenhuis.nl](mailto:j.bollemeijer@oogziekenhuis.nl)



*Fig. 1 Herpes zoster ophthalmicus. If the tip, side and root of the nose is involved (sign of Hutchinson) the n. nasociliaris is involved and more risk of ocular problems*



*Fig. 2 Squamous cell carcinoma*



*Fig. 3 Kaposi (Photo C. Meenken and G.J. van den Horn)*

Imagine, you are a general practitioner in a middle-sized city somewhere in Sub-Sahara Africa. On Monday morning your first patient in the OPD is a 33 year old male with since two weeks the symptoms of herpes zoster ophthalmicus on the left side. He can't close his left eye anymore due to scar formation of the upper eyelid, his eye is painful, red and filled with puss, the vision in this eye is markedly reduced. (fig 1)

The second patient is a 40 year old woman with since several months a conjunctival growth on the right eye. (fig 2) The third patient is a 29 year old male with since several weeks a strange thickened dark red upper eyelid of the left eye. The eyelid is not painful. (fig 3) He has dark red patches in his oropharynx. The fourth patient, a 36 year old woman, has been put on HAART recently as she was found to be HIV positive. She is complaining of loss of vision.

30 years ago it was very rare to start the week in the OPD like this. However, with the arrival of HIV opportunistic infections like herpes zoster ophthalmicus (patient 1) and neoplasms like squamous cell carcinoma of the conjunctiva (patient 2) and Kaposi sarcoma (patient 3) are nowadays common in relatively young patients.

And since the introduction of Highly Active Antiretroviral Treatment (HAART) in 1996 new phenomena like Immune Recovery Uveitis (patient 4) have appeared (see article *Immune Recovery Uveitis*, C. Meenken and others. pp. 25.).

Worldwide more than 35,3 million people are infected with HIV, the greater part in Sub-Saharan Africa (25 million), Asia (4,8 million) and North America/Western Europe (2,1 million). In lower income countries it is the second cause of death after lower respiratory infections. Adnexal and orbital complications affect more than 25% of untreated HIV-positive patients and could be the presenting sign of the disease. Keratoconjunctivitis sicca occurs in 10 to 20% of patients and in more advanced stages of the disease posterior segment manifestations like retinal microvasculopathy and CMV retinitis are seen in some areas in 40-50% of patients.

Eye diseases diminish the quality of living of patients suffering from AIDS. For the general practitioner it is important to recognise that an infection can be opportunistic, due to AIDS. As many general practitioners are the first doctors patients visit they are the ones who diagnose the disease and who decide on therapy and referral. In this paper some tools are presented to recognise HIV related eye diseases and to facilitate treatment and/or referral.

Two important skills are necessary to fulfil this task: knowledge and examination skills. The general practitioner should have knowledge about which opportunistic infection fits into the picture of a certain level of immunodeficiency. And the general practitioner should be capable to perform a basic eye examination.

HIV is acting by reducing the number of CD4 cells eventually leading to deep immune incompetence, which paves the way for opportunistic infections and neoplasms. Table 1 shows an overview.

Table 1 Ophthalmic manifestations of HIV infection by CD4 T cell count

|           |                                                                                                                                                                                                                             |
|-----------|-----------------------------------------------------------------------------------------------------------------------------------------------------------------------------------------------------------------------------|
| CD4 < 500 | Herpes zoster ophthalmicus<br>Kaposi sarcoma<br>Lymphoma<br>Squamous cell carcinoma conjunctiva                                                                                                                             |
| CD4 < 200 | Tuberculosis<br>Toxoplasmosis<br>Fungal infections like <i>Coccidioidomycosis</i> ,<br><i>Cryptococcosis</i> , <i>Histoplasmosis</i> , <i>Pneumocystis jirovecii</i>                                                        |
| CD4 < 100 | Cytomegalovirus retinitis, Herpes zoster virus retinitis<br><i>Mycobacterium avium</i> complex infection<br><i>Microsporidiosis</i><br>Progressive multifocal leucoencephalopathy<br>Retinal/conjunctival microvasculopathy |

In diagnosing an opportunistic infection a handy tool is the hand ophthalmoscope. (see article *Red Reflex and More*, P.Hardus and others. pp. 47.)

Therapy depends on the availability of drugs. In individuals with advanced immunodeficiency more aggressive therapy is mandatory as they have an increased risk of permanent vision loss.

A patient with herpes zoster ophthalmicus could benefit from aciclovir (800 mg five times daily) or valaciclovir (1000 mg three times daily), topical calamine lotion or emollient, potassium permanganate soaks, systemic antibiotics in case of secondary infection and analgesics like indomethacin (50 mg three times daily), while amitriptyllin (75-150 mg at night) and carbamazepine (100 mg once or twice daily) can reduce post herpetic neuralgia. Local therapy for cornea exposure due to a retracted upper eyelid could consist of eye ointment and a tarsorrhaphy.

In case of a Kaposi sarcoma of the eyelid and conjunctiva there are more Kaposi's in the mouth. Median survival in Sub-Saharan Africa is 3.5 months. Treatment is in the first place to start HAART as soon as possible as it greatly improves the survival. Surgical excision is sometimes possible, but as Kaposi sarcoma is a heavily vascularized tumor can be difficult. Radiotherapy and intralesional vinblastine chemotherapy are other options.



The differential diagnosis of a conjunctival growth is (apart from a few other rare tumors like non-Hodgkin lymphoma, pyogenic granuloma after trauma and papilloma) pinguecula (harmless hyalin degeneration), pterygium (from the conjunctiva spreading “wing” over the cornea with parallel blood vessels giving rise to astigmatism and eventually covering of the pupil) and conjunctival intraepithelial neoplasia leading to squamous cell carcinoma of the conjunctiva. Squamous cell carcinoma of the conjunctiva must be excised completely with a free zone around the process of at least 2 mm as recurrences can be very aggressive. If possible the whole area is treated with double freeze-thaw cryotherapy. An alternative is application of 5-fluoro-uracil 1% eye drops four times daily during four days followed by ten days rest and reinstallation of 5-fluoro-uracil 1% four times daily. In case of metastasis the first stations are the submandibular- and pre-auricular lymphnodes.

If the CD4 count is below 200 patients are more likely to suffer from intra-ocular infections. Those infections reduce the visual acuity and can be diagnosed by funduscopy. Look for local and systemic signs of the infections of table 1.

AIDS is still a deadly disease. In general prompt diagnosis of HIV and timely start of treatment with HAART is essential to improve the condition of the patient.

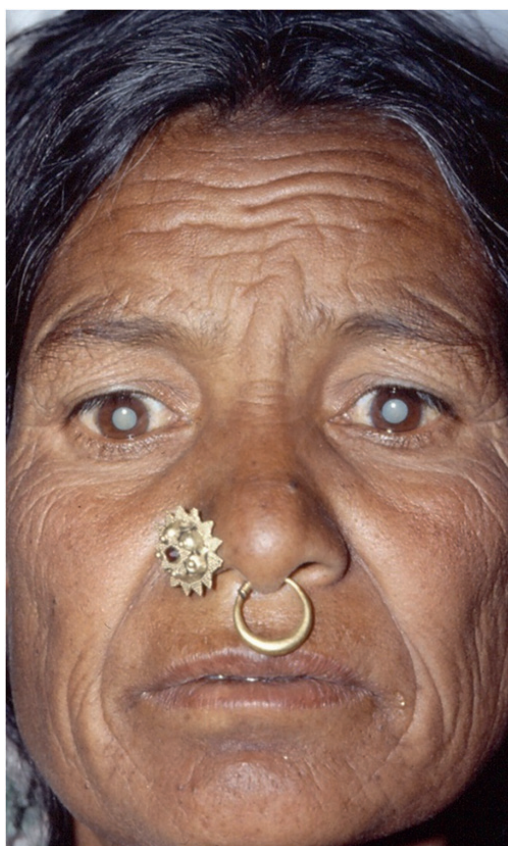Many thanks to Hans van den Horn and Ina Meenken, ophthalmologists, for reviewing the manuscript.

#### REFERENCES:

1. Cunningham ET Jr, Margolis TP. *Ocular manifestations of HIV infection*. N Engl J Med 1998; 339: 236-244
2. <http://www.unaids.com>

# CATARACT

MARGREET HOGEWEG, OPHTHALMOLOGIST, CBM MEDICAL ADVISOR CE ASIA



*Fig 1. Bilateral mature cataract*

The prevalence of blindness\* (\*WHO definition of presenting Visual Acuity (VA) of less than 3/60 (< 0.05, cannot count fingers at 3 meter) in the better eye) is usually between 2-4% in people over the age of 50 years. Of all blindness, 40-50% is due to age related cataract, making this the single most important cause of blindness. WHO advises a 'Cataract Surgical Rate' (CSR: number of cataract surgeries per year per million population) of 2000 for Africa and 3000 for Asia. In many African countries the CSR is still estimated as < 500/million/year, indicating

a huge backlog of cataract patients in need of surgery.

Patients with age related cataract are elderly, and present with a history of gradual and painless loss of vision, due to progressive clouding of the lens. It is essentially a bilateral condition. The most important risk factor is age. In low income countries, age related cataract seems to develop about 10 years earlier compared to the West. Many patients are only in their early sixties. Cataract may also be secondary to trauma, intra-ocular inflammation and long-term use of steroids. Cataract can also occur in young children, as congenital or developmental cataract. Cataract requires surgery as soon as possible, to prevent amblyopia (lazy eyes).

## EXAMINATION AND DIAGNOSIS

Assessment of Visual Acuity (VA): to qualify for cataract surgery in remote rural areas, VA should usually be less than 6/60 but of course depends on local guidelines. Light perception and light projection must be intact: patients should be able to indicate whether a torch light is "on" or "off", and to indicate from which direction the light comes, even in 'mature cataract'. The pupil must react briskly to light.

In mature cataracts, the opaque lens is visible immediately behind the iris, as a grey-white opacity (fig. 1) (not to be confused with a corneal scar: an irregular white grey opacity in front of the iris and partly or completely covering it). Immature cataract (in particular central posterior sub-capsular cataract) can be visually very disturbing but cannot be recognised as easily during an external ocular examination. The colour of the "pupil"/ lens in elderly people is always slightly greyish: this does not necessarily indicate the presence of cataract.

The best method to estimate the amount of

cataract is by examining the 'red reflex' with a direct ophthalmoscope in a semi-darkened room. A clear lens and clear vitreous will show a bright red reflex, emerging from the well vascularized choroid. An advanced immature cataract will show partial obscuration of the red reflex. The red reflex cannot be seen in mature cataract. The level of VA should be in balance with the obscuration of the red reflex. Note: in rare cases, obscuration of the red reflex may be caused by a vitreous haemorrhage, not cataract. Corneal scars will of course also obscure the red reflex. (see article *Red Reflex and More*, P.Hardus and others. pp. 47.)

It should always be realised that there are other causes for gradual loss of vision in the elderly, apart from cataract: for instance gradual change in refraction, glaucoma (chronic open angle), diabetic retinopathy, age related macular degeneration, various other chorio-retinal conditions and optic atrophy. Therefore assessment of visual acuity, in combination with assessment of the red reflex, is essential before making the diagnosis 'cataract' and selecting patients for cataract surgery.

#### TREATMENT

'Anti-cataract' medicines are useless and a waste of money. The only effective treatment is surgery, with removal of the lens material. Intraocular lens (IOL) implantation (fig. 2) has become standard (pseudophakia) in most countries. Cheap IOLs are available for \$ 5-10.- or even less.

The surgical technique will usually be either ECCE (extra capsular cataract extraction) or "SICS", (small incision cataract surgery). Phako-emulsification is another good technique,




Fig 2. Intraocular lens

gaining more and more popularity in major eye departments, but the machine is very expensive and even the cheapest foldable IOLs are 10 x more expensive than standard PMMA IOLs. This is usually not affordable for poor rural populations. In addition: advanced cataracts are less suitable for this technique. Final results can be almost equally good in all three techniques, but much depends on the right selection of patients, the quality of surgery and the postoperative care. All techniques require a good microscope. The choice of technique will depend on local circumstances and the preference and training of the surgeon. Unless the patient is a child, surgery is done under local anaesthesia.

An A-scan and keratometer can calculate the best IOL power before surgery so that no glasses will be necessary postoperatively. If not available, a standard 21 or 22 D IOL is implanted and any residual refractive errors can be corrected with glasses, if needed. A late complication of the extracapsular cataract extraction is secondary posterior capsule opacification, causing visual impairment. If severe, this requires Nd:YAG laser treatment or opening of the capsule with a sharp needle. In case an IOL cannot be implanted (aphakia), the patient will need S+10 glasses after surgery.

Couching is still common in parts of Sub Saharan Africa. Traditional healers perforate the eye with a sharp 'instrument' and push the lens away from the pupillary area, deep into the vitreous. The complication rate is very high, but the intervention can be successful. A well couched eye has an uncorrected VA of 2-3/60 (count fingers at 2-3 metres), which can improve to 6/18 or even better with aphakic S+10 spectacles.

Best indications for surgery:

- patient with bilateral VA < 6/60, due to cataract (depending on policies and available resources).
- one-eyed patient with a VA of < 3/60, due to cataract.
- bilateral dense congenital cataract in children (no red reflex).
- eyes with lens-induced glaucoma (prognosis guarded).

Relative indications for surgery:

- unilateral cataract (second eye has no/imma-



ture cataract, patient still can see).

- second eyes, in unilateral pseudophakia (vision already restored by surgery in the first eye).
- unilateral traumatic cataract (often a poor prognosis, second eye good).

No indications for surgery:

- no/doubtful perception/projection of light (no improvement to be expected).
- cataract extraction in eyes with poor vision, but good red reflex (other eye disease likely).
- unilateral congenital cataract (eye deeply amblyopic).

'Referral' for cataract surgery is not sufficient. Only 10% of the "referred patients" will finally present for surgery; the reasons for this include costs and lack of transport.

It is very worthwhile to arrange for cataract surgery. If there is no eye department in the vicinity, it may be useful to liaise with an eye team. The team could visit regularly as part of their outreach work and take patients with them for surgery at their base and back. An alternative is to invite an eye team for surgery at the

hospital once or twice a year. For this, take into account the farming season and local festivities. Particular attention should be paid to accessibility for women, as they suffer from cataract blindness more often than men. Good publicity is essential. It may well be possible to obtain financial support through local churches and service clubs or through the various (I)NGO's that focus on eye care. Rural health insurance systems may include refund for cataract surgery, thus removing the barrier of costs. For follow up patient will usually come back to the local hospital. It is important to monitor the outcome of cataract surgery. In the ideal situation, < 5% of the patients should have an uncorrected VA of < 0.1, six weeks after surgery. In reality the final VA is often < 0.1. in 10-15%, but this percentage should not be higher than that.

Cataract blindness is unnecessary. Vision can be restored by a comparatively simple operation. It is one of the most rewarding and cost effective interventions in medicine!

# CHILDHOOD BLINDNESS AND VISION LOSS IN AFRICA

PAUL COURTRIGHT M.D. PH.D , OPHTHALMOLOGIST

Kilimanjaro Centre for Community Ophthalmology, Moshi, Tanzania.

Kilimanjaro Centre for Community Ophthalmology, Division of Ophthalmology, University of Cape Town, Cape Town, South Africa.

Vision loss and blindness in children is rare, even in Africa. While accurate estimates are not available, it is likely that, in most of Africa, less than one child in 5,000 is blind. (1) That said the impact of vision loss and blindness in childhood can be significant; for the children, their families, and societies at large the impact can endure for decades.

Due to successful vitamin A supplementation and measles immunization programmes in many countries, corneal blindness has reduced significantly. As a result most incident blindness and vision loss in children is no longer preventable; instead, it is a mix of treatable and untreatable causes. The major treatable causes include congenital or developmental cataract (fig. 1), glaucoma, and refractive error.

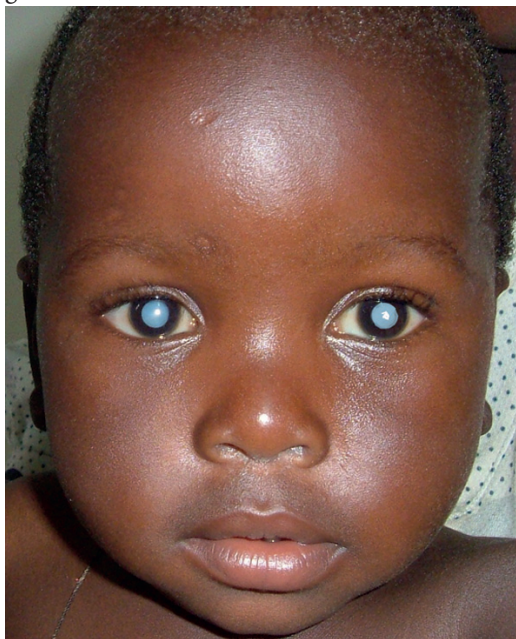

Fig. 1 Congenital bilateral cataract (Photo Prof. Khumbo Kalua, Malawi)

The aetiology of congenital or developmental cataract in many of these children remains poorly understood. While rubella, a treatable condition, does contribute to some cases of congenital cataract, evidence suggests that its contribution is not more than 20%.

Managing the present causes of blindness and vision loss in children requires sophisticated services to provide good quality surgical, medical, and optical interventions. Also, these children require comprehensive care throughout their childhood in order for them to achieve their full visual potential. Unlike cataract surgery in adults, managing cataract in children is a lifelong undertaking. The links between the health care services and educational services need to be strengthened to ensure that these children achieve their educational potential. One aspect of dealing with childhood vision loss is still true: children with serious eye disease need to be seen by a qualified eye care provider as soon as possible because of amblyopia prevention. In many countries, particularly in eastern Africa, "Child Eye Health Tertiary Facilities" (CEHTF) have been established at key tertiary hospitals, each striving to serve a population of approximately 10 million. (2) These facilities need to be staffed by well-trained paediatric ophthalmologists, paediatric anaesthetists, optometrists, low vision specialists, and Childhood Blindness & Low Vision Coordinators. Ideally they will have strong links to the communities they serve in order to identify children in need of services as well as to ensure that children receive adequate health and educational follow up.

Experience gained suggests that:

1. Key community members (key informants) can be very effective in identifying and referring children in need of eye care ser-

- vices. Studies in a number of countries have demonstrated the impact of this approach and training manuals have been developed and disseminated.(3-5)
2. Less success has been demonstrated in using general health workers to identify and refer children, whether through routine clinic activities such as immunization, or through community campaigns. (4,5) Currently, the knowledge and skills of general health workers regarding childhood vision loss is generally weak (6). Every district hospital in Africa should have at least one trained clinical person dedicated to eye care; Their role is crucial to ensure that a sufficient diagnosis is made and proper referral done. They should have a strong relationship with the CEHTF both for referral and for follow up.
  3. Where possible children need to be referred to a CEHTF for proper assessment and treatment. Since children require long term follow up, which may be difficult to always carry out at the CEHTF, a plan of action, tailored to each child and the clinical and educational environment needs to be adopted. This is one of the tasks of the Childhood Blindness & Low Vision Coordinator, who works alongside clinical personnel.

For general clinicians working in Africa, some recommendations include:

1. Find out where the nearest CEHTF is located, visit the facility, and establish a relationship with the relevant personnel.
2. Assess the current knowledge and skills of eye care personnel in the area related to child eye health and provide upgrade training, as needed.
3. Insert short educational messages in training of general health workers, particularly on the need to refer children, regardless of age, with serious eye problems to the relevant eye care providers as emergencies.

4. In collaboration with the CEHTF consider conducting key informant programmes in the area.
5. Do not forget vitamin A or measles related blindness; if corneal opacity secondary to vitamin A/measles is detected, this should be a trigger to report to health authorities. Corneal opacification is the “tip of the iceberg” and indicates a serious public health problem.

Continuing to reduce the burden of vision loss in children in Africa requires good planning, a comprehensive approach, good partnership, a strong link between all sectors of the health care services, a viable system for follow up, and engagement with the educational sector. Only by including all these aspects will children be able to achieve their best visual and educational potential.

#### REFERENCES:

1. Gogate P, Kalua K, Courtright P. Blindness in childhood in developing countries: time for a reassessment? *PLoS Med.* 2009 Dec;6(12):e1000177.
2. Agarwal PK, Bowman R, Courtright P. Child eye health tertiary facilities in Africa. *JAPOS* 2010;14:263-266
3. Shija F, Kalua K, Shirima S, Lewallen M, Courtright P. Using key informants to identify and refer children who need eye care services: A manual for Africa. AED. 2010
4. Shija F, Shirima S, Lewallen S, Courtright P. Comparing key informants to health workers in identifying children in need of surgical eye services. *International Health* 2012;4: 1-3
5. Kalua K, Ng'ongola RT, Mbewe F, Gilbert C. Using primary health care (PHC) workers and key informants for community based detection of blindness in children in Southern Malawi. *Hum Resourc Health* 2012; Sept 27; 10(1):37
6. Kishiki E, Dieleman M, Hogeweg M, Lewallen S, Courtright P. Is the existing knowledge and skills of health workers regarding eye care in children sufficient to meet needs? *International Health* 2012; 20: 260-266

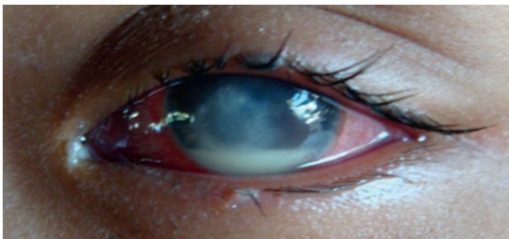
# COMMUNITY-BASED PREVENTION OF CORNEAL BLINDNESS, A SUCCESSFUL PROGRAMME IN TAKEO PROVINCE, CAMBODIA

MANFRED MÖRCHEN DR.MED., FEBO  
Ophthalmologist CARITAS Takeo Eye Hospital, CBM  
Te Serey Bonn MPH, MA  
Project Director CARITAS Takeo Eye Hospital

MARGREET HOGEWEG, M.D, OPHTHALMOLOGIST  
CBM CEARO Medical Advisor CBM CEARO regional office, Bangkok.

## INTRODUCTION

Corneal ulceration as a result of untreated traumatic corneal abrasion is one of the leading causes of ocular morbidity and blindness worldwide. [1] In developing countries the main cause of corneal ulcer is a minor agricultural injury sustained during farming, e.g. during plantation and harvest. Patients usually prefer treatment nearby (such as by unlicensed pharmacies, traditional healers, private doctors, or apply eye drops, already used by others). They therefore present late at the hospital with severe bacterial- or fungal ulcers, that are resistant to treatment. The widespread availability of steroid-containing eye drops, contraindicated in case of simple corneal abrasion, results in an even higher incidence of corneal ulcer.



*Fig. 1 Patient with advanced fungal corneal ulcer (after foreign body injury during work at a paddy field)*

A community-based strategy for early treatment of corneal abrasions and prevention of corneal ulceration was tested before in several studies. [2-5] It showed that post-traumatic corneal ulceration can be prevented by simple topical application of 1% chloramphenicol eye ointment (e.o) shortly after the injury, by trained village health workers (VHWs). Immediate

treatment with antibiotic e.o. also prevents the development of fungal corneal ulcers, that are otherwise very hard to treat.

Corneal scarring unrelated to trachoma was identified as the second main cause of bilateral blindness in a Rapid Assessment of Avoidable Blindness (RAAB) in Cambodia in 2007. [6] In a hospital-based study (2005) at the CARITAS Takeo Eye Hospital (CTEH) 130 patients had been admitted within a period of only 6 months because of a severe corneal ulcer: 50 % was due to trauma, 75 out of 99 eyes were blind (VA <3/60) due to late presentation and 23% of the eyes had to be removed, due to very severe intra-ocular inflammation, resistant to treatment. [7] The high number of patients with advanced corneal ulcers at CTEH was the main reason to initiate a community-based prevention programme, based on the previous studies. The objective was to demonstrate the feasibility beyond a strict research setup and to integrate community-based prevention in a busy secondary eye hospital in rural Cambodia.

## METHODOLOGY

In 2008, 26 volunteer village health workers (VHWs) from 2 communes were trained by staff of CTEH for one week in basic eye care, to identify corneal abrasion with fluorescein strips and a blue torch, and to treat abrasions with 1% chloramphenicol e.o. three times daily for three days. A population of 20,012 in 26 villages was prospectively monitored by the VHWs for 13 months. The villages were located near CTEH in a rural area, dominated by agriculture.

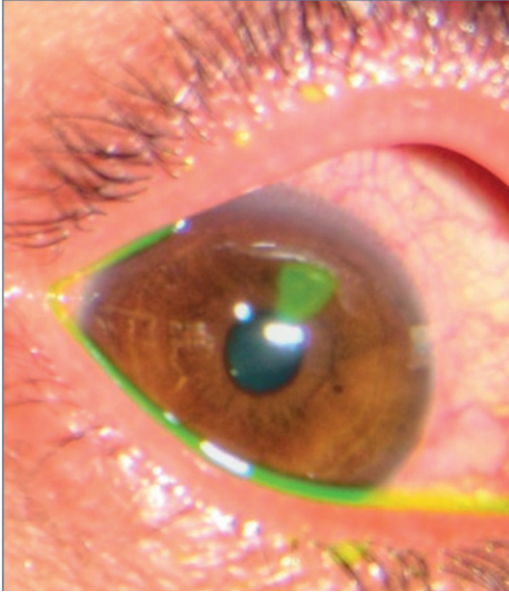


Fig. 2 Corneal abrasion

VHWs were also taught to record visual acuity (VA) using an E-chart, identifying corneal ulcer and other common eye diseases, and how to refer to CTEH. They were advised to treat a) only residents of their intervention area, b) patients presenting within 48 hours of the injury with confirmed corneal abrasions and c) patients aged 5 years and older. Every month the VHWs were called to CTEH for reporting and follow-up.

## RESULTS

During 13 months, 1,147 individuals (female 56.9%, male 43.1%) reported to the VHWs. 783 (78.2%) were farmers. VHWs diagnosed

corneal abrasion in 1,004 cases (87,5%). The main results of these 1,004 cases are presented in table 1.

Table 1: Outcome in 1,004 patients with corneal abrasions, as diagnosed and treated by VHWs

|                                                     |       |       |
|-----------------------------------------------------|-------|-------|
| Corneal abrasion                                    | 1,004 | 100%  |
| Healed                                              | 949   | 94,5% |
| Referred because of corneal ulcer despite treatment | 34    | 3,3%  |
| Dropped out                                         | 14    | 1,4%  |
| Missing results                                     | 7     | 0,7%  |

In total 713 (71.3%) patients reported an injury of organic nature, of whom 392 (39.2%) had an injury with rice. Table 2 demonstrates the seasonal correlation between location and agent of ocular injuries. In December 2008 and 2009 (main harvest season in Cambodia), around 70% of all ocular traumas were reported to have happened during work in the paddy fields, with rice grains as major agent. A second peak with a similar pattern could be observed in April and May (minor harvest and early plantation season).

Visual acuity was less than 6/60 in 26.4% of all patients before treatment. After treatment, only 1.1% could see less than 6/60.

Of the 34 patients referred because of corneal ulcer, 9 (26.5%) were lost to follow-up. Of the remaining 25 patients, 7 (28%) corneal ulcers could be confirmed at CTEH. None of these eyes had to be removed. In 18 patients (72%) corneal ulcer could not be confirmed. Addition-

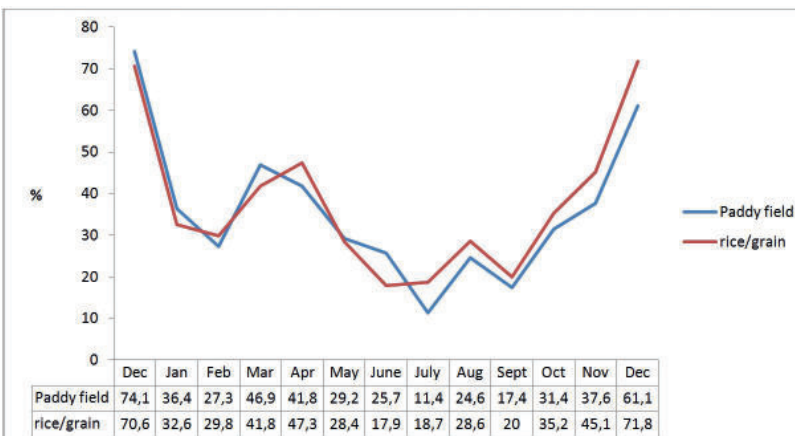


Table 2: Reported location of ocular injury and agent from December 2008 until December 2009 by VHWs.



ally, 46 sight threatening (cataract, pterygium etc.) and 28 conjunctivitis cases were referred by the VHWs.

## DISCUSSION

This intervention project aimed to prevent traumatic corneal ulcer in a region dominated by agriculture, with a hot and humid climate and known high prevalence of corneal blindness.[6,7] Hospital-based data indicate that at CTEH the overall number of patients that had to be treated because of corneal ulcer decreased from 745 in 2007 to 442 in 2013, a decrease of 41% while yearly more patients attended ! This study therefore shows that early application of chloramphenicol e.o. probably prevented a considerable number of corneal ulcers.

Only 28% of the patients referred with corneal ulcer could be confirmed. As the VHWs had been trained only for one week, such misdiagnoses had been expected. There was confusion with a variety of other causes of red eyes, - not ulcers -, but yet in need of treatment. We consider this therefore as a positive outcome.

VHWs had to be selected from the communes in collaboration with the local authorities. Therefore, this Cambodian experience may reflect the ground reality and may serve as a feasible model of intervention despite some limitations.

The strong correlation between the harvest season, location of ocular trauma and reported agent is important: massive awareness campaigns before the harvest season and basic training of primary health care workers for a short period may be able to prevent many corneal ulcers in communities with a large agricultural sector and hot and humid climates. As a result of our study, we have indeed initiated

mass radio messages at the start of the harvest season in order to create awareness of the importance of early treatment after sustained corneal injury.

Advocacy efforts by CTEH resulted in significant support by the local government institutions, especially the Provincial Health Department (PHD) of Takeo Province. The project continued during 2010 and 2011 with support from CTEH and was handed over to the PHD in February 2012. In these 3 years, all together 1,985 patients with corneal abrasions were identified (healing rate 98.9%). 24 Patients with suspected corneal ulcer and 246 patients with other eye diseases, like cataract, pterygium etc., were referred to CTEH. We hope, that the Cambodian Ministry of Health, will adapt community prevention of corneal ulceration as a national strategy in the next multi-year plan.

## REFERENCES

- 1) Whitcher JP et al: Corneal blindness: a global perspective. *Bull World Health Organ* 2001;79:214-21
- 2) Upadhyay MP et al: The Bhaktapur eye study: ocular trauma and antibiotic prophylaxis for the prevention of corneal ulceration in Nepal. *Br J Ophthalmol* 2001;85:388-392
- 3) Maung N et al: Corneal ulceration in South East Asia. II: A strategy for the prevention of fungal keratitis at the village level in Burma. *Br J Ophthalmol* 2006;90:968-970
- 4) Gethsen K et al: Corneal ulceration in South East Asia. I: A model for the prevention of bacterial ulcers at the village level in rural Bhutan. *Br J Ophthalmol* 2006;90:276-278
- 5) Srinivasan M et al: Corneal ulceration in south-east Asia III: prevention of fungal keratitis at the village level in south India using topical antibiotics. *Br J Ophthalmol* 2006;90:1472-1475
- 6) Rapid assessment of avoidable blindness (RAAB). National Program for Eye Health, Ministry of Health Cambodia, 2007
- 7) Hall T, Lion F: Corneal ulcer in a Cambodian eye hospital. *Community Eye Health Journal* Vol 18 No.53 2005 p81

# CONJUNCTIVITIS OF THE NEW-BORN

N. BUISMAN, OPHTHALMOLOGIST EX-ZIMBABWE, CAMEROON AND TSJAAD

P. HARDUS, OPHTHALMOLOGIST, PREVIOUSLY DEPT. OPHTHALMOLOGY GRONINGEN UNIVERSITY ,NIGERIA, ANGOLA

*This article was originally written by Nico Buisman who was much involved in ophthalmology in low resource countries ; he worked as general medical doctor and ophthalmologist for many years in different countries, especially in Africa. Unfortunately he died much too young due to a fatal disease. The content of his article is still very actual. Where necessary some updating is done.*

## INTRODUCTION

Every case of conjunctivitis with an onset in the first 28 days after birth is called conjunctivitis of the newborn or ophthalmia neonatorum. (1) The contamination usually takes place during the passage through the birth canal. It is, therefore, a sexually transmitted infection (STI). The incidence of STI's is high in Africa, 10-30%. Common causes are *Neisseria gonorrhoea* and *Chlamydia trachomatis*. Chlamydia occurs more often than gonorrhoea. In addition, other less harmful microorganisms occur. Prompt diagnosis and treatment of the conjunctivitis of the new born is important as an untreated gonococcal conjunctivitis can lead to blindness within a short time. Furthermore, a genital infection in the mother that remains undetected can lead to sterility. Despite the effort in the struggle against AIDS to reduce the number of STI's, the prevalence of these infections is still increasing. An additional problem is the high prevalence of Penicillinase-Producing *Neisseria gonorrhoea* (PPNG) in Africa.

## CLINICAL PICTURE

A conjunctivitis caused by gonococci and chlamydia generally leads to a severe inflammation with much swelling and redness of the eyelids and conjunctiva (Fig.1). Often great quantities of half-liquid green-yellow discharge are present. When the eye is opened by the examiner this discharge may flow out of the eye. This picture, however, may also be much milder.

It may start on one side and remain unilateral for the first days. Gonococci produce toxins that

melt the cornea. This can happen extremely quickly and may cause a corneal perforation. Both gonococci and chlamydia cause systemic infections and this will be evident physically. It is impossible to make a clinical distinction between gonococci and chlamydia infections. Gonococcal conjunctivitis may start a bit earlier than chlamydia conjunctivitis. Gonococci and chlamydia often cause a more severe conjunctivitis than other microorganisms. In Cameroon a sexually transferred micro-organism was detected seven times more often in severe conjunctivitis than was detected in the lighter cases. (2) The severity of the inflammation is a strong indicator of the presence of an STI in mother and child. A dual infection of both gonorrhoea and chlamydia is common.

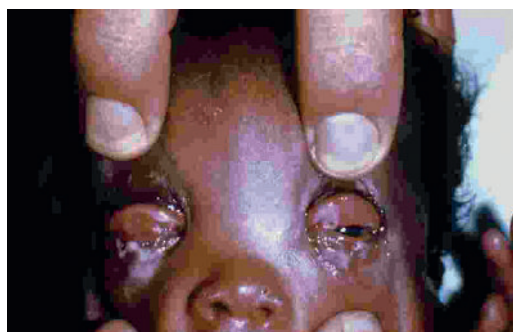


Fig. 1 Neonatal conjunctivitis

## DIAGNOSIS

A simple method of diagnosing gonococci and chlamydia as a cause of conjunctivitis in a newborn is needed in order to treat mother and

child adequately for STI's. Gonococci can be diagnosed reliably with Gram stain microscopy. Following the removal of the bulk of secretion, a smear of the conjunctiva can be taken and Gram stained. The diagnosis is positive for gonococci when Gram negative diplococci are seen in the leucocytes. A culture does not give much more information than does careful microscopy. Laboratory diagnosis of chlamydia is practically impossible in a general hospital in a low resource country. The distinction between a severe and a light conjunctivitis can be very helpful. The treatment scheme makes use of this distinction. (Table 1)

The clinical picture of newborn conjunctivitis may be confused if a child is given traditional eye medicines (TEM) by a local healer. Herpetic conjunctivitis is very uncommon. Most times there are herpetic skin abnormalities around the eye as well. Also nasal lacrimal duct obstruction can give rise to discharge but will be at a bit later age and is usually unilateral. Pressure on the lacrimal sac will give discharge.

#### TREATMENT SCHEME

A Gram stained smear should be made whenever a newborn has conjunctivitis. If gonococci are present mother and child must be treated. In all cases of severe conjunctivitis mother and child also need to be treated for chlamydia as the chance that chlamydia is an underlying cause of the infection is very high. A dual treatment is recommended in all severe cases of gonorrhoea. The remaining cases of light conjunctivitis can be treated as a nonspecific infection. If the conjunctivitis persists following two to three days' of antibiotics, treatment for chlamydia should be given.

Tabel 1 Treatment of ophthalmia neonatorum

|                       |                                                                                                                                            |
|-----------------------|--------------------------------------------------------------------------------------------------------------------------------------------|
| Gonococci             | Kanamycin 25 mg/kg IM 1x + Tetracycline (alternative: Gentamycin) eye ointment 1 week + Erythromycin orally 12.5mg/kg 4x a day for 2 weeks |
| No gonococci          |                                                                                                                                            |
| Severe conjunctivitis | Erythromycin orally 12.5mg/kg 4x a day for 2 weeks                                                                                         |
| Light conjunctivitis  | Tetracycline eye ointment                                                                                                                  |

#### TREATING GONOCOCCAL INFECTIONS

The best treatment is single dose, systemic and on an outpatient basis. WHO and CDC propose several drugs. It is important to first rinse the eye thoroughly with water or saline (every 5 minutes) in order to remove the toxins that are dangerous for the cornea.

The following antibiotics are useful:

- Kanamycin 25 mg/kg IM 1x + Tetracycline eye ointment, 1 week (recommended)
- Kanamycin 25 mg/kg IM 1x + Gentamycin eye ointment, 1 week
- Ceftriaxone 20-25 mg/kg IM 1x; do not exceed 125 mg
- Cefotaxim 25 mg/kg IM 1x

Ceftriaxon and cefotaxim PM are practical but expensive. Kanamycin combined with topical gentamycin or tetracycline is very useful and less expensive.

Gonococcal strains tend to have become susceptible to antimicrobials that are not frequently used, such as kanamycin, gentamicin and spectinomycin. Spectinomycin, especially, would seem an appropriate second-line treatment for gonorrhoea, although it is expected that widespread use of these antibiotics will quickly result in development of resistant *N. gonorrhoea*. (3,4)

The best will be to get information which treatment is locally most effective to treat the gonococ.

#### TREATING CHLAMYDIA INFECTIONS

Systemic treatment for the child consists of erythromycin orally 12.5 mg/kg q.i.d for two weeks. (1) Obviously both the mother and her partner should also be treated for the STI's. It is worth noting that the *Chlamydia trachomatis* that causes the conjunctivitis of the newborn is of a different serotype (D-K) than the chlamydia that causes trachoma (A-C). The clinical picture of the conjunctivitis is also different.

#### PROPHYLAXIS

The most important activity is the thorough cleansing of the eyelids as soon as the child's head is born in order to prevent cervical secretions from reaching the conjunctiva. Topical 0.5% erythromycin and 1% tetracycline are considered equally effective for prophylaxis of ocular gonorrhoea infection in newborn infants. (1)

Where available (not in USA), povidone-iodine 2.5% seems at least as effective. A second application has no additional effect.(5)

## REFERENCES

1. Neonatal Conjunctivitis Medscape update march 2013  
McCourt E.A  
<http://emedicine.medscape.com/article/1192190-over-view>
2. Buisman NJF, Abong Mwemba T, Garrigue Getal. Chlamydia Ophthalmia Neonatorum in Cameroon. *Doc. Ophthalmol.* 1988; 70: 257-64
3. Guidelines for the management of sexually transmitted infections. WHO, 2001
4. Report of the expert consultation and review of the latest evidence to update guidelines for the management of sexually transmitted infections WHO/RHR/11.37 World Health Organization 2011.  
[http://apps.who.int/iris/bitstream/10665/75194/1/WHO\\_RHR\\_11.37\\_eng.pdf](http://apps.who.int/iris/bitstream/10665/75194/1/WHO_RHR_11.37_eng.pdf)
5. S J Isenberg, L Apt, M Del Signore, S Gichuhi, N G Berman  
A double application approach to ophthalmia neonatorum prophylaxis *Br J Ophthalmol* 2003;87:1449–1452  
<http://www.ncbi.nlm.nih.gov/pmc/articles/PMC1920568/>

# CORNEAL ULCERS (INFECTIVE KERATITIS): THE SILENT EPIDEMIC

JAN VAN DER HOEK, CONSULTANT OPHTHALMOLOGIST SCARBOROUGH HOSPITAL  
WOODLANDS DRIVE  
Scarborough YO12 6QL UK. Formerly Nepal

## INTRODUCTION

Unilateral blindness resulting from microbial keratitis has gone under-reported in the large national blindness surveys, although it is now recognised that superficial corneal trauma, often sustained during agricultural work and leading to microbial keratitis, is a major world-wide cause of unilateral ocular morbidity and blindness. (see article *Community-based prevention of corneal blindness* Manfred Mörchen a.o. p. 10) The incidence of ulcerative keratitis in the US has been reported at 11 per 100,000 population. In southern India the incidence was found to be closer to 11 per 10,000 population or 10 times the US rate. Extrapolation of the results of studies in India suggests that annually world-wide one and a half million people become unilaterally blind as a result of corneal ulceration.

In Western countries microbial keratitis is often caused by contact lens wear (30-40% as reported in literature) or seen in severe ocular surface disease and/or in debilitated elderly patients. In the developing world the most common cause is trauma, which in rural areas is often sustained during agricultural work (up to 50% in reported series). The incidence usually follows a seasonal pattern with peak incidences occurring at times of increased agricultural activity, particularly during harvest and planting seasons. Children and young adults may be heavily represented in the patient group with infective keratitis thought to be the result of unsupervised playing and the general lack of awareness of the dangers of eye injury. Corneal ulcers may account for 10% of all red eyes seen in eye clinics in developing countries.

Factors that make the presentation of infective keratitis different from that in the more temperate parts of Europe include the different etiology: fungal keratitis is very much more common in hotter climates. Up to an estimated 50% of infective keratitis in hot climates may be

caused by fungus, particularly in a community engaged in agricultural activity. *Fusarium* or *Aspergillus* are the most commonly implicated filamentary fungal species. Bacterial infection make up most of the remaining 50%, both gram positive and gram negative bacteria such as *Staphylococcus aureus*, *Streptococci* and *Pseudomonas* are commonly found in infective keratitis. *Acanthamoeba* is less frequently encountered but may present as a non-contact lens related cause of keratitis. More unusual organisms such as *Nocardia* and some species of mycobacterium are occasionally seen as causes of keratitis.

Another features of infective keratitis in the developing world is the often marked delay in seeking medical help; the delayed patients may have tried traditional eye medicines and or steroid eyedrops prior to presentation. Children may have poor vitamin A status, particularly if associated with measles although some reports in the literature appear to suggest that this is on the decline.

Patients may also have pre-existing trichiasis from trachoma (particularly common in women), poor eyelid closure and/or reduced corneal sensation from leprosy.

## HISTORY

The farmer with keratitis is unlikely to present to an ophthalmic trained person within hours of the original injury. There may be a considerable delay in seeking advice as small eye injuries are probably common and many may heal without sequelae. Treatment with topical steroids (which may be available at the local pharmacy shop and may help to mask the symptoms of inflammation) or harmful traditional eye medicines (TEM) can significantly worsen the situation. TEM may be available from local healers or simply bought from local market stalls. Not all TEM will be harmful for the eye, but patients



may be persuaded to try unsuitable and aggressive treatments some of which were not intended as eye treatments (tiger balm) or contain ingredients unsuitable as medicine (human urine). The patient may be reluctant to make a long and arduous journey to an unfamiliar eye clinic, often having to spend considerable length of time away from home resulting in loss of income and unanticipated costs.

## DIAGNOSIS

Infective keratitis is generally not difficult to diagnose as the history of trauma, the loss of vision, watering and the typical clinical features of corneal infiltration and hypopyon are usually self-evident. A history revealing the type of matter or material that entered the eye and caused the keratitis may be helpful.

Always look if there is a foreign body left. (rotate eyelid)

A baseline record of epithelial defect, amount of infiltration and hypopyon should be obtained. Deep corneal scrapings can be obtained for direct microscopy with Gram stain; KOH or Lactophenol Cotton Blue may be used for the detection of fungi. However, it takes considerable skill and experience to confidently diagnose a particular infection on the basis of direct microscopy. If microbiology facilities are available a scrape for culture and sensitivity may lead to identification of the offending organism, although cultures may only be positive in about half of all cases.

Infections should initially be assumed to be bacterial unless there are features strongly suggestive of other organisms. Trauma involving vegetative matter should lead to a high index of suspicion of fungal keratitis, although it obviously does not rule out a bacterial cause. The presence of a dry, raised plaque on the cornea, particularly if associated with pigmentation, a feathery infiltrate and a sticky non-moving hypopyon make a diagnosis of fungal keratitis much more likely. A history of steroid use (abuse) is contributory to the diagnosis. Pain may be a late feature of fungal keratitis.

*Acanthamoeba* may often be mistaken for a herpetic infection in the early stages with a waxing waning course. Pain is a prominent and early feature and often out of proportion with the initially scanty clinical signs. The classic ring ulcer often appears later in the disease process. Successful treatment of acanthamoebal kerati-

tis requires an early diagnosis and it should be realised that in developing countries acanthamoeba is only rarely associated with contact lens wear. The latter may be considered rare outside urban centres.

It is important to bear in mind that no appearance is pathognomonic of a particular organism and polymicrobial infections do occur.

Viral keratitis may occasionally masquerade as a bacterial infection although the typical staining pattern usually provides clues as to the correct diagnosis. Ulceration secondary to Herpes zoster should raise suspicion of an underlying HIV infection in endemic areas. Sterile ulcers and in particular Mooren's ulcers are not uncommon, especially in sub-Saharan Africa. The underlying process is autoimmune related and gives rise to mostly peripheral corneal melting which can be relentlessly progressive. Males tend to be more affected than females.

## TREATMENT PROTOCOL

The treatment of microbial keratitis requires the intensive topical application of broad spectrum antibiotics. Oral or intravenous antibiotics are not thought to be helpful. In cases where endophthalmitis is suspected oral ciprofloxacin (750 mg b.d.) provides good penetration into the eye and broadspectrum activity.

Topical ciprofloxacin (ofloxacin or levofloxacin may be alternatives) has good broad spectrum activity which includes activity against *Pseudomonas*, but more restricted activity against gram positive organisms. It is easily available in Asia and Africa and can be kept outside a refrigerator. In some parts of the world quinilone resistance may be on the increase.

The combination of topical gentamycin (which may be fortified) and a cephalosporin also has excellent broad spectrum range and does cover gram positive organisms. *Pseudomonas* resistance may occur and tobramycin has better activity against that organism. Cephalosporin drops are not commercially available and have to be manufactured; these can therefore not be kept for long and will require refrigeration. Resistance to cephalosporins may be on the increase in some parts of the world. Gentamycin causes corneal toxicity and prolonged use may delay healing of corneal defects.

Tobramycin, gentamycin and cephalosporins are widely available, although the latter may

have to be made locally. Other antibiotics, such as penicillins can be manufactured into eye drops.

The initial intensive treatment regime requires hourly medication round the clock at least for the first 48 hours and during waking hours thereafter for 5-7 days (sterilization phase).

Additional measures are important and may include cutting of the eye lashes to aid lid hygiene and adequate instruction to the patient and his helpers regarding hand washing and other hygienic measures. The eye should **not** be padded.

Mucocelles, trichiasis and entropion should be corrected in the early treatment phase.

Children should always receive vitamin A supplementation in those areas where marginal vitamin A status can be expected. The same applies to pregnant and lactating mothers.

Five days of intensive treatment clears the cornea of susceptible bacteria and in eyes that show definite signs of improvement the treatment can be tailed off with the emphasis shifting towards adequate lubrication and epithelial healing.

Indolent and worsening ulcers should initially be treated with alternative regimes and in tropical countries polymicrobial ulcers and/or fungal keratitis should be suspected. Delayed healing of defects may benefit from a tarsorrhaphy once the initial infection is under control.

#### FUNGAL & ACANTHAMOEBA

Chlorhexidine drops are active against acanthamoeba and possibly have antifungal properties. Neomycin –in combination with chlorhexidine- can also be used against *acanthamoeba*. The treatment is often long and difficult. Polyhexamethyl biguanide (PHMB) in combination with dipropamide (Brolene) is the standard treatment in most European countries.

Both *Fusarium* and *Aspergillus* are thought to be sensitive to natamycin and often to amphotericin B. Natamycin is the usual choice for filamentous fungal infections and is commercially available. Amphotericin B may be used as an alternative but is not readily available as an eye treatment; fluconazole and/or miconazole may be less effective in ocular mycosis according to published data. None of these drugs are commercially available as eye drops and will have to be manufactured. Voriconazole is a newer

anti-mycotic which has been used successfully in individual cases. Most anti-fungals contain large molecules that penetrate the cornea poorly and debridement and scraping of epithelium may help. Oral and intravenous anti-fungals have been tried in the treatment of corneal ulcer as well as subconjunctival injections and even intrastromal injections.

Perforations can be glued with a histoacrylic glue where available, but this may be difficult or impossible without an operating microscope. If the infection is under control perforations can do quite well following tarsorrhaphy. Leaving adequate space for inspection of the eye is helpful and in successful cases the AC deepens within 1-2 days. Maintain good antibiotic cover and be aware that panophthalmitis is a real risk if the original infection festers under the tarsorrhaphy.

#### PROGNOSIS

In all cases it is important to be realistic in terms of what can be achieved for a particular patient. Often vision cannot be saved and keeping the eye and making the eye symptom free becomes the main goal.

Keratoplasty for corneal scarring or active keratitis is rarely an option outside large ophthalmic centres and not available at all in some African countries. The possibility of evisceration in advanced and difficult cases should be considered as a means to make the patient symptom free. Heroic attempts at treating unsalvageable eyes may be very costly to the patient even in clinics where the treatment is free. Every day away from home is expensive for the patient and family members who may have accompanied the patient. Earnings may be lost and the need to pay for transport and food may be a considerable burden. Evisceration/ conjunctival flaps and tarsorrhaphies may have to be considered in earlier phases of the disease than is customary outside less developed and poorer parts of the world.

#### PREVENTION

Primary prevention of eye trauma is difficult and require education programmes, e.g. at schools and the availability of eye protection. Simple antibiotic ointment (e.g. chloramphenicol and clotrimazole ointment) applied soon after an eye injury has been shown to be of use in the prevention of corneal infections. BAK

and chloramphenicol have invitro anti-fungal properties. Povidon Iodine drops may also be useful. The training of local health workers to recognize corneal trauma and institute appropriate treatment is important. The use of topical steroids should be strongly discouraged –and

engaging pharmacies in medical education programmes may yield benefits. The same applies to the use of traditional eye medicines if these are found to be harmful and the engagement of local healers in medical education.

#### SUMMARY OF TREATMENT PROTOCOL

Topical **Ofloxacin/ Ciprofloxacin** hourly for 5 days

*Or*

Topical fortified **Gentamycin AND Cephazoline**  
alternating hourly for 5 days

*Plus*

Cut eye lashes, treat trichiasis and mucocele  
Vitamin A supplementation in children

AND

**Gt Natamycin** if fungal cause is suspected  
**Fortified Gentamycin (1.5%)**

2 ml of parenteral 40 mg/ml (intravenous) Gentamycin is added to normal concentration Genta-  
mycin eyedrops (0.3%)

**Note: risk of corneal toxicity in prolonged use**

**Fortified Cephalosporin (5%)**

500 mg of parenteral antibiotic is diluted with 2.5 ml sterile water and added to 7.5 ml of preservative free artificial tears

or

Dilute 750 mg of antibiotic with 5 ml of sterile water and add the solution to 10 ml of sterile water; the resulting solution is placed in sterile drop bottles. These solutions require refrigeration

#### FOR INFORMATION ON THE MANUFACTURE OF (FORTIFIED) EYE DROPS :

Pharmacy Department of Moorfields Eye Hospital may be able to offer advice.

Address: City Road , London EC1V 2PD , UK

**Telephone** +4420 76849090

**Fax** +4420 7253 4696

**Email:** [pharmaceuticals@moorfields.nhs.uk](mailto:pharmaceuticals@moorfields.nhs.uk)

# DIABETES MELLITUS

P.HARDUS, OPHTHALMOLOGIST PREVIOUSLY DEPARTMENT OF OPHTHALMOLOGY  
GRONINGEN UNIVERSITY, NIGERIA, ANGOLA

The globalisation makes diabetes and so diabetic retinopathy a global problem. Four out of every five people with diabetes now live in low income countries, with most affected men and women being of working age. (2010 international diabetes federation) Factors are the change in lifestyle with less movement, obesity and change of food.(1)

Certain ethnic groups are more susceptible than others.

Prevalence figures especially in developing countries are not very reliable.

A recent review included a total of 72 articles from 33 countries. There were only 26 population-based studies using fundus photography (12 in developing countries), of which only 16 (eight in developing countries) were published since 2000.

Prevalence estimates of diabetic retinopathy varied from as low as 10% to as high as 61% in persons with known diabetes and from 1.5 to 31% in newly diagnosed diabetes. Across all the studies, the median (interquartile range) prevalence of any diabetic retinopathy in known diabetes was 27.9% (22-37%) and 10.5% (6-16%) in newly diagnosed diabetics. Prevalence of diabetic retinopathy was higher in low income countries.(2)

An excellent review about modern treatment is written by Hall for ICEH.(3)The presentation seems basically not different in the first and third world.(4)

In type 1 diabetes, neovascularisation is more prominent. In type 2 there is more background retinopathy. Severe retinopathy can be present while at the same time visual acuity can be fine: so screening only on visual acuity gives a false feeling of comfort and is therefore insufficient.

Diagnostic means techniques such as fundus photography, fluorescence angiography and ocular coherence tomography are only limitedly available. They are only useful if laser treatment,

anti-VEGF treatment and preferably also vitreo-retinal surgery are present.

What to do for the physician who does not have these facilities? Screen your patients for eye disease by using funduscopy. Though direct ophthalmoscopy does not show the peripheral retina, screening the central retina gives most of the times sufficient information. Fundus camera's, mounted on smart phones may soon become available and will greatly facilitate diagnosis of diabetic retinopathy. A grading and referral scheme is available. (5)

Try also to find out where advanced treatment can be given so that you can advise your patient.

Good blood sugar regulation, weight reduction in case of overweight, sufficient exercise, healthy food and hypertension control delay the progression of diabetic retinopathy and other diabetes related complications.

## REFERENCES

1. Diabetes Action Now: An initiative of the World Health Organisation and the International Diabetes Federation 2004 ISBN 92 4 159151 <http://www.who.int/diabetes/actionnow/en/DANbooklet.pdf>
2. Ruta LM, Magliano DJ, Lemesurier R, Taylor HR, Zimmet PZ, Shaw JE. Prevalence of diabetic retinopathy in Type 2 diabetes in developing and developed countries. *Diabetic Medicine*. 30(4):387-98, 2013 Apr.
3. Hall A. Recognising and managing diabetic retinopathy. *Comm Eye Health* Vol. 24 No. 75 2011 pp 05 – 09. [http://www.cehjournal.org/wp-content/uploads/download/ceh\\_24\\_75\\_005.pdf](http://www.cehjournal.org/wp-content/uploads/download/ceh_24_75_005.pdf)
4. Padmaja Kumari Rani, Rajiv Raman, Vikranth Sharma, Sachin Vasant Mahuli, Arokiasamy Tarigopala, RR Sudhir, Govindasamy Kumaramanickavel, and Tarun Sharma. Analysis of a comprehensive diabetic retinopathy screening model for rural and urban diabetics in developing countries. *Br J Ophthalmol*. 2007 November; 91(11): 1425–1429. <http://www.ncbi.nlm.nih.gov/pmc/articles/PMC2095459/>
5. Diabetic retinopathy (DR): management and referral 2011 [http://www.cehjournal.org/wp-content/uploads/download/ceh\\_24\\_75\\_005.pdf](http://www.cehjournal.org/wp-content/uploads/download/ceh_24_75_005.pdf)

# GLAUCOMA

P.HARDUS, OPHTHALMOLOGIST PREVIOUSLY DEPARTMENT OF OPHTHALMOLOGY  
GRONINGEN UNIVERSITY ,NIGERIA, ANGOLA

Glaucoma is the second most common cause of blindness in the world.

There were an estimated 60.5 million people with open angle glaucoma (OAG) and angle closure glaucoma (ACG) in 2010. This number is expected to increase to 79.6 million by 2020, and of these, 74% will have OAG. Women have comprised 55% of OAG, 70% of ACG, and 59% of all glaucoma in 2010. Asians will represent 47% of those with glaucoma and 87% of those with ACG.

Bilateral blindness was present in 4.5 million people with OAG and 3.9 million people with ACG in 2010, expected to rise to 5.9 and 5.3 million people in 2020, respectively. (1)

The current definition of glaucoma is: “an optic neuropathy characterised by a specific pattern of optic nerve head and visual field damage, which represents a final common pathway resulting from a number of different conditions that can affect the eye”. While elevated intra-

*Table 1 Number of people with OAG, 2010*

|               | Total OAG  | Lower CL   | Upper CL   | % World OAG |
|---------------|------------|------------|------------|-------------|
| Europe        | 10,693,335 | 7,599,188  | 15,040,703 | 23.9        |
| China         | 8,309,001  | 6,695,433  | 10,423,439 | 18.6        |
| India         | 8,211,276  | 6,812,711  | 9,937,413  | 18.4        |
| Africa        | 6,212,179  | 4,992,103  | 7,722,626  | 13.9        |
| Latin America | 5,354,354  | 2,943,534  | 9,697,792  | 12.0        |
| Japan         | 2,383,802  | 2,106,534  | 2,697,623  | 5.3         |
| SE Asia       | 2,116,036  | 1,744,523  | 2,580,354  | 4.7         |
| Middle East   | 1,440,849  | 1,001,315  | 2,082,944  | 3.2         |
| World         | 44,720,832 | 33,895,340 | 60,182,894 |             |

*Table 2 Number of people with ACG, 2010*

|               | Total ACG  | Lower CL   | Upper CL   | % World ACG |
|---------------|------------|------------|------------|-------------|
| China         | 7,473,195  | 4,419,269  | 13,216,902 | 47.5        |
| India         | 3,733,620  | 2,630,886  | 5,510,142  | 23.7        |
| SE Asia       | 2,141,584  | 1,246,325  | 3,852,149  | 13.6        |
| Europe        | 1,371,405  | 1,310,861  | 1,434,702  | 8.7         |
| Latin America | 322,804    | 308,667    | 337,581    | 2.1         |
| Japan         | 278,643    | 171,811    | 456,753    | 1.8         |
| Africa        | 245,844    | 235,143    | 257,029    | 1.6         |
| Middle East   | 177,869    | 170,124    | 185,964    | 1.1         |
| World         | 15,744,965 | 10,493,085 | 25,251,221 |             |



ocular pressure is the most important risk factor for the development or progression of glaucomatous damage, it is still only a risk factor and not the disease itself. Glaucoma is an essentially bilateral condition.

The pressure in the eye is caused by aqueous fluid, which is produced in the ciliary body and passes between iris and lens from the posterior chamber to the anterior chamber. There it is absorbed in the angle formed by cornea and iris.

Two abnormal situations are common: due to closure of the angle of the anterior chamber, the fluid cannot reach the trabecular system where absorption takes place. This is called ACG (French: glauome primitif par fermeture de l'angle).

This type of glaucoma in the acute form is painful and blindness is common if it is not treated immediately. It is more common in Asians and in women. The anterior chamber is shallow and a peripheral iridectomy (surgical or laser) is necessary with or without cataract extraction, as a swollen lens may contribute to the angle closure. In case of acute glaucoma the second eye usually will need a prophylactic iridectomy as well.

The type of glaucoma responsible for most cases of blindness is OAG ( French: glaucoma primitif à angle ouvert). The angle of the anterior chamber is open but an obstruction is present in the trabecular tissue and therefore the aqueous fluid cannot be absorbed easily.

Important risk factors are a family history of glaucoma and ethnicity. Members of the negroid race have a higher risk of OAG glaucoma. In addition, long term use of freely available steroid containing eye drops can lead to severe OAG and even blindness, some times already in young adults. Onchocerciasis is also considered as a risk factor for glaucoma.

## DIAGNOSIS

The definite diagnosis glaucoma is made by finding of typical pattern of visual field loss (VFL). In third world circumstances these investigations are difficult to perform due to the lack of the necessary instruments and difficulties in understanding by patients.

In early stages of VFL patients do not have complaints. Patients in the third world often have such an advanced VFL that this is clear from their behaviour: their gait is uncertain; they cannot see where they are putting their feet

as they only have a small part of their VF left. VFL occurs more often in the peripheral VF, where rods are prominent; this often results in the patient complaining of poor night vision. On examination, the pupillary reaction becomes poor, as many nerve fibres are lost. Many patients present late with already incurable blindness in one or both eyes.

A summary of simple steps to assess glaucoma is published in Community Eye Health. In the same issue more items concerning glaucoma are discussed.(2)

The optic disc excavation can be examined with an ophthalmoscope. The extent of damage of nerve tissue can be judged by the cup/disc ratio. The diameter of the central excavation of the optic nerve is divided by the diameter of the total disc. This is best done in the vertical position because the nerve fibre loss begins at the superior and inferior pole (fig 1-2).

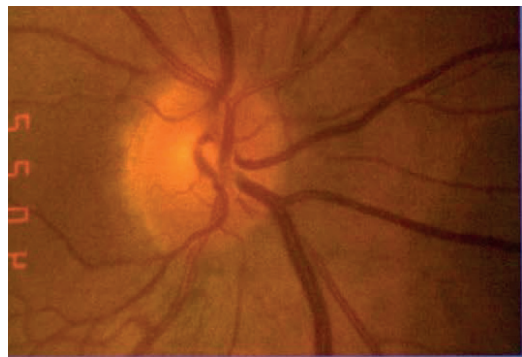


Fig. 1 Normal optic disc; cup/disc ratio 0.2

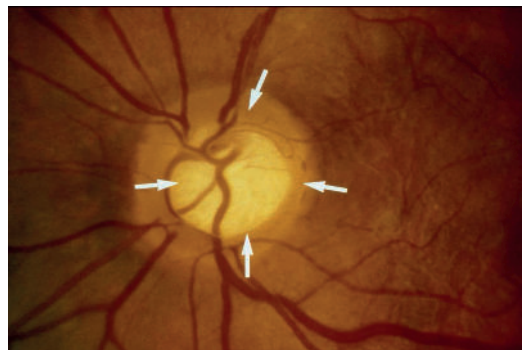

Fig. 2 Glaucomatous cupping; arrows point to the outer border of the cup.

In many cases of OAG the ocular pressure(IOP) is high. A simple, inexpensive method of measuring the pressure is by Schiottz tonometry




Fig. 3a Schiotz tonometer

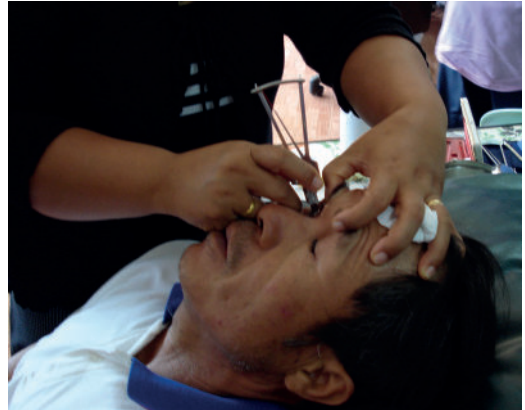

Fig. 3b Measuring the intraocular pressure with a Schiotz tonometer

(fig.3). (see also article *Maintenance of Instruments*, D.Haddad a.o.. p. 31.)

It needs some exercise but it is still a good, cheap and especially reliable instrument. The

IOP is normally between 12 and 21 mm Hg. The width of the anterior angle can be determined with a torch light (fig.4).

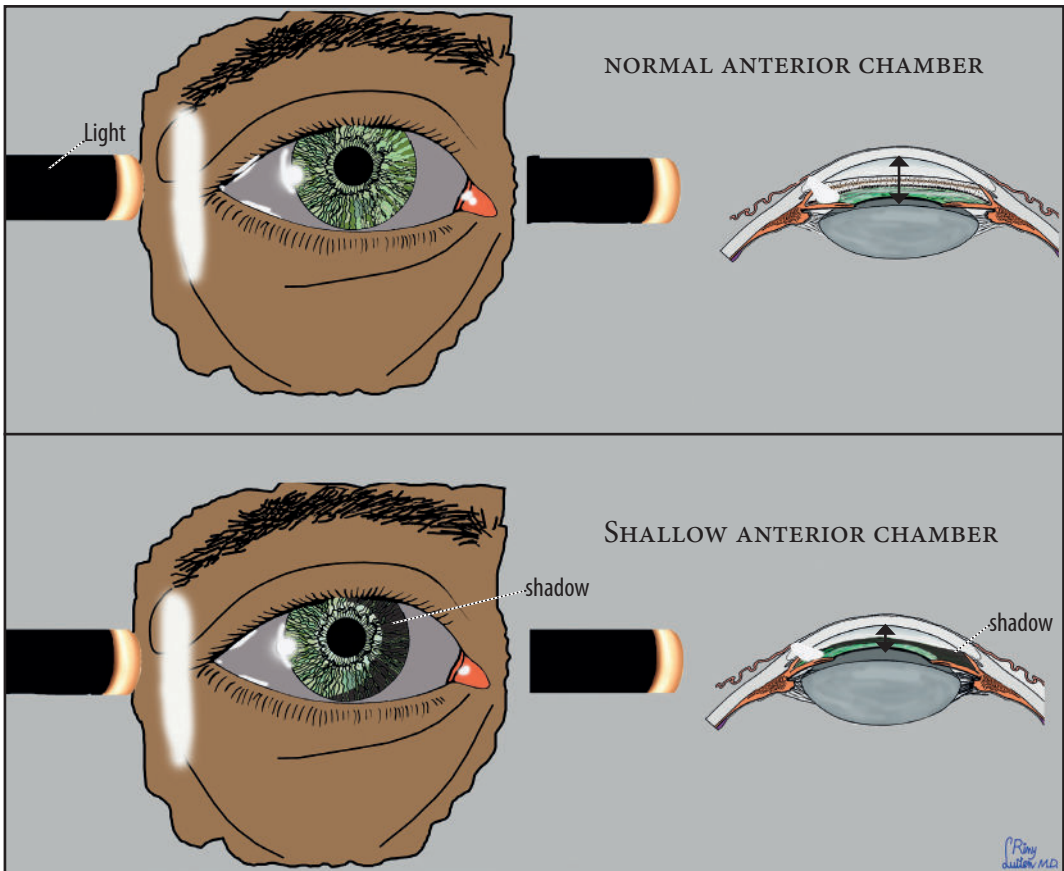


Fig. 4 Judging anterior chamber depth: when the anterior chamber is shallow, a shadow is cast on the nasal iris when the temporal side of the eye is illuminated in the plane of the iris with a penlight; the shadow is caused by the anteriorly protruding iris.

## TREATMENT

Treatment can be medical or surgical. The purpose is to lower the intraocular pressure. Beta-blockers as timolol, prostaglandin agonists as Latanoprost, sympathicomimetics as brimonidine and local carboanhydrase inhibitors as dorzolamide are available as drops. The carboanhydrase inhibitor acetazolamide 250 mg can be used for a short period of time as tablets or injection.

Advise for non-specialist would be to have acetazolamide available as tablet and injection (in case of vomiting), for ACG. Have at least one type of eye drop: prostaglandin agonists are most powerful with limited side effects. A good alternative are the beta-blockers. Let it also depend on the price and availability.

Compliance with longstanding use of medication in the third world is problematic: it is costly and there are either no drugs or inappropriate drugs available. In addition, the result of glaucoma surgery following the prolonged use of eye drops is less due to changes in the conjunctiva.

Surgery, usually a trabeculectomy, will therefore be more frequently indicated than in a sophisticated setting; there is no alternative.

In 80% an acceptable intraocular pressure can be reached in previously non-operated

OAG; this operation should be performed by the ophthalmologist.

Such a filter operation can be done in combination with antimetabolites. The last couple of years big success is achieved with implants as the Baerveldt device. This is expensive but a more affordable Indian device will soon become available.

A peripheral iridectomy, performed in cases of ACG in order to connect the posterior chamber and the anterior chamber/trabecular system, might be within the scope of the interested general doctor.

## REFERENCES

- 1 H A Quigley, A T Broman The number of people with glaucoma worldwide in 2010 and 2020  
Br J Ophthalmol 2006;90:262–267. doi: 10.1136/bjo.2005.081224 <http://www.ncbi.nlm.nih.gov/pmc/articles/PMC1856963/>
- 2 H. Philippin, P. Shah, M. Burton Detecting possible glaucoma with only limited equipment: a crucial first step. Community Eye Health Vol. 25 No. 79 & 80 2012 pp 48 - 49. <http://www.cehjournal.org/article/detecting-possible-glaucoma-with-only-limited-equipment-a-crucial-first-step/> Community Eye Health Vol. 25 No. 79 & 80 2012 pp 48 - 49.
- 3 Sandford-Smith . Eye Surgery in hot climates. Thorpe ISBN 0-7089-4499-X download for free <http://www.cehjournal.org/resources/eye-surgery-in-hot-climates/>

# IMMUNE RECOVERY UVEITIS INVOLVEMENT OF THE EYE IN IMMUNE RECONSTITUTION INFLAMMATORY SYNDROME

CHRISTINA MEENKEN MD, PHD, OPHTHALMOLOGIST

GERARDUS J VAN DEN HORN MD, PHD, OPHTHALMOLOGIST

VU MEDICAL CENTER DEPARTMENT OF OPHTHALMOLOGY, AMSTERDAM, THE  
NETHERLANDS

Since the advent of the so-called combined Anti Retroviral Therapy (cART) the Immune Reconstitution Inflammatory Syndrome (IRIS) has emerged as an important condition complicating antiretroviral treatment: 10-25% of patients receiving cART may develop atypical forms of (opportunistic) infections (OI), presenting with unusually enhanced inflammatory reactions. Because the clinical symptoms worsen while under therapy, these manifestations are referred to as paradoxical. The term “unmasking syndrome” (regarded by some as a distinct form of IRIS), is used in case symptoms of a previously subclinical OI become manifest. Such reactions are attributed to dysregulation of immunological responses to antigens from opportunistic pathogens in a partially restored immune system. IRIS typically occurs during the initial phase of cART (highest incidence 8-16 weeks after initiation [1]), and is associated with a wide spectrum of pathogens, most commonly mycobacteriae, herpes viruses, and fungal infections such as cryptococcal meningitis. Patients with advanced immune deficiency (CD4 cell counts fewer than 50/ $\mu$ L) have the highest risk of developing IRIS.

## OCULAR IMMUNE RECONSTITUTION PHENOMENA

Soon after the introduction of cART, enhanced ocular inflammation (diagnosed by the presence of cells and flare in the eye) was observed in the anterior chamber and vitreous cavity of patients with inactive CMV-retinitis (CMV-R). This uncommon phenomenon typically occurred within 6-12 weeks after initiation in patients with advanced immune depletion [2,3]. Classically, the clinical picture of CMV-R in AIDS is characterized by only minor inflammation in these compartments as a result of the inability

to mount inflammatory responses due to severe immune incompetence. Now, enhanced inflammation seemed to be associated with a rapid increase of CD4 cell counts to values above 100/ $\mu$ L, and was attributed to enhanced immunological responses against CMV antigens as a result of cART. Because this ocular form of IRIS presents as uveitis, it is usually referred to as ‘immune recovery uveitis’ (IRU).

Apart from CMV-R, other (opportunistic) infections, such as mycobacterial infections [4] and *Leishmania major* [5] have also been associated with IRU.

The clinical spectrum of IRU expands from asymptomatic in some patients, to acute onset and self-limiting course (transient vitritis) [2], and to chronic persisting uveitis with long term complications [3].

For symptomatic cases of IRU, visual loss and floaters are the most common presenting symptoms. IRU-induced permanent loss of vision may result from complications of the intraocular inflammation, most commonly cystoid macular edema (CME) and epiretinal membrane formation, reflecting the primarily posterior segment location of inflammation in most cases [3,6].

The diagnosis IRIS (IRU) is usually made on the basis of clinical evidence of newly developed or enhanced (intraocular) inflammation in HIV positive individuals with advanced immune deficiency, shortly after receiving cART.

While inflammation in IRIS generally can be mitigated by corticosteroids, infectious diseases require a different approach, namely control of the underlying infectious agent, in which corticosteroids are often contraindicated. Unmasking IRIS should be differentiated from co-infections (e.g. tuberculosis, syphilis) and other disseminated (O)Is, systemic diseases,

and primary manifestations of (ocular) infection. One should always be alert to distinguish whether the symptoms result from a process of restoration of the immune system due to cART, or rather should be regarded as expression of a (disseminated) infection in a still immune incompetent individual. Obviously, to justify the diagnosis IRIS, a certain degree of immune recovery should be achieved (rise in CD4 cell count by  $>50/\mu\text{L}$  to a level  $> 100/\mu\text{L}$  [7]. This reflects a degree of immune recovery expected to control CMV in the absence of anti-CMV therapy.

Unmasking forms of IRIS generally require treatment of the causative pathogen, with simultaneous mitigation of the destructive inflammatory reaction. IRU in case of active CMV-R requires anti-CMV medication until under cART a substantial rise in CD4 cells has been achieved. In cases of mild and more advanced IRU, topical or orbital floor corticosteroids are usually sufficient to control inflammation. This therapy may also be beneficial for CME, and improve vision, at least in the short run. Established CME associated with IRU however, can follow a chronic course that is refractory to therapy.

## PREVENTION

It is probable that most cases of IRIS can be prevented by early identification of HIV-infected patients, and initiation of cART before they reach the advanced stage of immune deficiency associated with a high risk of OI's. Primary treatment of systemic OI's for a short period preceding initiation of cART may be indicated. Some investigators believe that a similar approach may reduce the incidence of CMV-associated IRU. However, because CMV retinitis is associated with a very high risk of mortality especially in the absence of cART, even a short delay in the initiation of cART should be avoided [8]. Only very rare circumstances would justify discontinuation of cART in case of IRU [9].

Further research of incidence and outcome of IRU, especially in resource poor regions, are needed to better clarify the extent of this evolving problem in the regions of highest HIV prevalence.

## REFERENCES

1. French MA, Lenzo N, John M, Mallal SA, McKinnon EJ, James IR, Price P, Flexman JP, Tay-Kearney ML: Immune restoration disease after the treatment of immunodeficient HIV-infected patients with highly active antiretroviral therapy. *HIV.Med.* 2000; 1: 107-15
2. van den Horn GJ, Meenken C, Danner SA, Reiss P, de S: Effects of protease inhibitors on the course of CMV retinitis in relation to CD4+ lymphocyte responses in HIV+ patients. *Br.J.Ophthalmol.* 1998; 82: 988-90
3. Karavellas MP, Plummer DJ, MacDonald JC, Torriani FJ, Shufelt CL, Azen SP, Freeman WR: Incidence of immune recovery vitritis in cytomegalovirus retinitis patients following institution of successful highly active antiretroviral therapy. *J.Infect.Dis.* 1999; 179: 697-700
4. Zamir E, Hudson H, Ober RR, Kumar SK, Wang RC, Read RW, Rao NA: Massive mycobacterial choroiditis during highly active antiretroviral therapy: another immune-recovery uveitis? *Ophthalmology* 2002; 109: 2144-8
5. Meenken C, van Agtmael MA, Ten Kate RW, van den Horn GJ: Fulminant ocular leishmaniasis in an HIV-1-positive patient. *AIDS* 2004; 18: 1485-6
6. Jabs DA, Van Natta ML, Holbrook JT, Kempen JH, Meinert CL, Davis MD: Longitudinal study of the ocular complications of AIDS: 2. Ocular examination results at enrollment. *Ophthalmology* 2007; 114: 787-93
7. Kempen JH, Min YI, Freeman WR, Holland GN



# HOW TO IMPROVE EYE SERVICES IN YOUR AREA

ARIE VAN OOSTERWIJK, OPHTHALMOLOGIST; PREVIOUSLY UMCU, KENYA, UGANDA

What can a Generalist Tropical Doctor do to improve the quality of eye care in her/his hospital?

Get to know the staff of the eye clinic that is nearest to you. Talk with them about their understanding of the Vision 2020 programme and ask them what their “vision” is about the future of eye care in the area. Try to find out how they see the three pillars of the programme.

First, “*pillar number one*”, disease control: Ask for the major causes of blindness in the area. How serious are cataract, onchocerciasis (river blindness), trachoma, refractive errors and childhood blindness, the five conditions that have been selected by Vision 2020? Ask the eye team to come to your hospital and hold eye clinics on a regular basis so that the principles of Vision 2020 can be put into practise.

Then, “*pillar number two*”, human resource development: Send someone from your hospital for training in ophthalmology. This course could take three months or one year, depending on what is available in your country or region. Graduates from these courses are often able to run an eye clinic on their own and select patients that need to be seen or operated upon by an ophthalmologist.

Finally, “*pillar number three*”, infrastructure development: Set aside a room in your hospital to be used as an eye clinic. Ideally this room should not have a lot of sunlight coming in to it and it should be at least three by three meters in size. Make equipment available to the eye worker(s) in your hospital. The donors who organise the eye-training courses often provide this equipment to suc-

cessful students. Make eye drugs available for use by the eye worker(s).

Antibiotic eye drops and ointments are often very inexpensive to purchase commercially. For the more specialised eye drugs such as steroids, atropine and diagnostics, contact a local hospital that has an eye drops production unit. They will probably be happy to sell their products to you, often at much lower prices than you would find in your local drug shops.

In summary, tropical doctors do not need to know all there is to know about eyes. Instead, they should be aware that blindness is bound to be a problem in their area and they should stimulate the development of a local eye care service that deals with the prevention and cure of the major blinding diseases.

# HOW TO HELP PROVIDE LOW VISION CARE, ESPECIALLY FOR CHILDREN

KARIN VAN DIJK

CBM GLOBAL ADVISOR ON LOW VISION; LOW VISION CONSULTANT TO LIGHT FOR THE WORLD NETHERLANDS AND TO KILIMANJARO CENTRE FOR COMMUNITY OPHTHALMOLOGY US, OPHTHALMOLOGIST PREVIOUSLY DEPARTMENT OF OPHTHALMOLOGY GRONINGEN UNIVERSITY, NIGERIA, ANGOLA

Low vision is functionally defined as ‘having irreversible visual loss that seriously reduces the ability to do many daily activities’. If a person has any useful vision, they should be considered to have low vision; they are not blind! This is an important distinction to ensure that any remaining vision is used as much as possible and people are not unnecessarily labelled as ‘blind’. This is especially important when assisting children. Up to this day, children in many low income countries are being taught Braille, regardless of their vision level, when attending special schools or resource centres/Annexes attached to mainstream schools, partly because they are labelled ‘blind’.

When you are faced with a person whose vision cannot be improved to normal levels and thus is low vision (formally defined as: visual acuity does not improve beyond 6/18), it is important to first check that everything possible has been done to improve their vision medically.

1. Has their diagnosis (and prognosis for vision) been confirmed by an ophthalmologist or other eye care worker?
2. Has all the medical and surgical treatment possible already been given?

If not, these activities need to be organised first.

Subsequently the following needs to be done to

assist someone with low vision:

- Listing vision related problems and needs: what does the person need and would like to do again, that he or she cannot do anymore because of poor vision.
- Refraction: It is important to check if they recently have been refracted and got correct distance or presbyopic spectacles, and are they wearing them? It is recommended to refract again.
- Measuring near vision, without and with full correction (elderly people need to wear their presbyopic correction). You might find for example that the near vision level of a child is good enough to read the print schoolbooks in primary school with new distance spectacles. Alternatively they might need simple magnification, such as a pair of ‘magnifying’ glasses (high + spectacles) of, for example, + 4.0 Dioptres to read print of the required size.
- Deciding on all interventions: prescription of new distance spectacles, non- optical interventions (such as light), magnifying devices.
- Obtaining and payment of spectacles and low vision devices. A simple prescription does not guarantee a child or adult will obtain the spectacles and will use them.
- Organizing follow up for further training



Fig. 1: Children with visual problems in a resource centre in northern Tanzania, unnecessarily learning Braille. (Photo David De Wit)

and support at school, or at a rehabilitation program; for example training in the use of devices and in mobility.

- Organizing annual follow-up, especially for children: They might need new distance spectacles and the ability to read smaller print sizes in higher grades.

One 'easy' way to find children with low vision is to visit schools where children with disabilities are known to be enrolled. The first thing to do is ensure that all children with visual problems in these educational facilities receive a thorough eye examination and refraction.

How especially children with low vision can be helped is illustrated by the following examples. (Fig. 1 and 2)

Vision assessment of 222 children with possible low vision (not amenable to further surgery and treatment) enrolled in 12 resource centres in Tanzania showed the following main causes of low vision (unpublished data):

- 36% Retina-related, of these 78% albinism
- 23% Lens-related, of these 48% had pseudophakia

The majority is likely to benefit from refraction (and new distance corrections), especially the many children with albinism (fig. 1). Their vision-related performance will also benefit from simple interventions such as caps, umbrellas, sunglasses and their health will benefit from clothing covering arms, legs and neck. Children with aphakia and pseudophakia, often benefit, in addition to distance spectacles and an optical device for near activities such as reading, from good light on their reading and writing tasks. Most importantly children operated for cataract need annual follow-up.

Vision assessment of 663 school children in Nepal (unpublished data) attending different types of educational services (including local schools) showed that refractive errors were the main cause of low vision (29%), followed by lens related conditions (22%). Refraction improved distance visual acuities substantially (of course only if the children also obtained the required spectacles!):

- Before refraction, 66% of children had (very) poor vision (<6/60), after a thorough refraction, only 35% remained in this



Fig. 2: Child (Malawi) with low vision can comfortably read a print schoolbook with distance spectacles and a simple hand magnifier. (Photo David De Wit)

category

- Many of the 65% with a visual acuity of 6/60 – 6/18 (after refraction) could now use their improved vision for reading the blackboard (seated in the front row) and almost all of these children could now access print.

The near vision of these children improved by distance glasses (the most common intervention!), non-optical interventions and/or magnifying devices:

- 82% reached small to large size print levels (was 62% before interventions)
- Only 7% still had very poor near vision after eye care assessment and interventions

Many children have learned to use Braille unnecessarily, regardless of their vision level, and after assessment have enough vision and motivation to learn print.

Non-optical measures are rarely understood or used as health/eye care staff might think these interventions are not 'medical'. The most common non-optical interventions that are very helpful for people with low vision of all ages relate to:

- Illumination: use of window light or of a reading lamp at work, reducing glare by wearing a cap.
- Contrast and Colour improvement.
- Distance: by reading at a closer distance.
- Size: by simply writing a bit larger.
- Posture: by using a reading or writing stand to avoid bending over and blocking light.

Optical low vision devices that are available in

many locations include low power hand magnifiers and high+ spectacles (+2.0 to at least + 10.0 D lenses in a frame). In addition any optical low vision devices can be ordered for a reasonable price from the low vision resource centre at the Hong Kong Society for the Blind.

If available, referral to a large eye hospital, at tertiary level, with a low vision service. Last but not least, all interventions need to be part of the advice given at the end of an assessment. It is important to realise that parents and teachers in general receive little/no information about low vision and the importance of use of vision. Simple explanations will improve compliance and motivation to (facilitate) use of (improved) vision.

#### GENERAL REFERENCES:

1. Low vision: we can all do more. Community Eye Health Journal 2012, volume 25, Issue 77 (<http://www.cehjournal.org/>)
2. Low Vision Care: The Need to Maximise Visual Potential. Community Eye Health 2004, Vol 17 No. 49 2004 (<http://www.cehjournal.org/>)
3. Low vision devices from the Hong Kong Society for the Blind: <http://www.hksb.org.hk>

# MAINTENANCE OF INSTRUMENTS

DANNY HADDAD, MD, FORMERLY DIRECTOR ONCHOCERCIASIS AND TRACHOMA PROGRAMS

PETER HARDUS, P.HARDUS OPHTHALMOLOGIST, PREVIOUSLY DEP OPHTHALMOLOGY GRONINGEN UNIVERSITY, NIGERIA, ANGOLA

## CLEANING

Following surgery used instruments should be cleaned immediately. Thorough cleaning of the instruments is necessary prior to sterilisation. Foreign material will impede sterilisation and will harden into a crust that will be difficult to remove. When liquid sterilisation is used, one must remember that this will not penetrate blood clots. In the western world, cleaning of instruments is done mechanically; the manual cleaning of instruments is no longer allowed. As mechanical cleaning is usually not possible in the tropics, manual cleaning should be meticulously performed. The risk of accidental contamination of the person cleaning the dirty instruments should be reduced to an absolute minimum. This requires that one must have access to surgical gloves to be worn while cleaning instruments. The use of chlorinated water may diminish the risk of HIV/hepatitis B infection. To clean instruments a piece of gauze or a soft sponge and a mild neutral soap should be used. Never use hard objects such as brushes, scrapers or scalpels. An instrument should be opened completely since, especially in a joint, there may be a lot of blood.

## Causes of rust on stainless steel instruments

- Blood: if instruments are not cleaned well, blood can cause rust. Haemoglobin contains iron!
- Sterilisation or cleaning with iodine.
- Iron parts in autoclave (e.g. screws) or stainless steel instruments with iron parts (screws). The iron ions can precipitate on the stainless steel and cause rust.
- Old instruments are often made of chromium plated iron. If the chromium is damaged the iron will precipitate onto other instruments during sterilisation.

## REMOVAL OF RUST

Soak instruments in Coca-Cola, for one hour. The rust will soften and can be removed quite easily. A solution of lemon and salt will also dissolve the rust.

## AUTOCLAVING PLASTIC OBJECTS

During autoclaving plastic objects (e.g. syringes, needle cones, nylon sutures etc.) should not be allowed to be in contact with a metal tray. This will result in direct heat transfer from the tray to the instrument; the latter may melt! If no suitable tray is available, always use folded cloth to protect instruments.

## SCHIOTZ TONOMETER

This simple instrument is still very useful for measuring ocular tension.

- It is cheap and will last for ever if well kept.
- There is only one important point: do NOT leave the plunger inside the shaft: the plunger will stick inside and will not move freely anymore.
- A pipe cleaner can be used to clean the inside of the shaft. (fig. 1)




Fig. 1 Schiotz tonometer with pipe cleaner in the shaft. Plunger with weight removed



## FURTHER INFORMATION

1. Haddad, Danny MD; Worst, Prof. Dr. J.G.F. *Standard operating procedure manual for maintenance of microsurgical instruments. Repair of microsurgical instruments.* See for booklet and CD on site [www.tropischeogheekunde.nl](http://www.tropischeogheekunde.nl)
2. <http://www.cehjournal.org/article/equipment-maintenance-and-repair/>

# ONCHOCERCIASIS

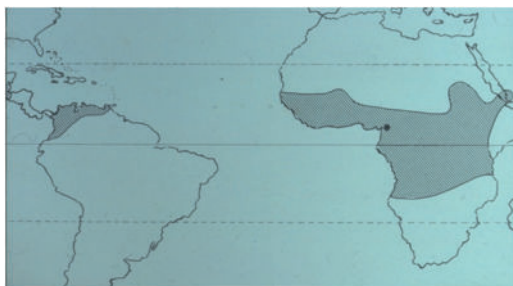H.C.KOPPERT, OPHTHALMOLOGIST.

NETHERLANDS TROPICAL COURSE, AMSTERDAM; THE NETHERLANDS SOCIETY FOR TROPICAL MEDICINE AND INTERNATIONAL HEALTH

## ONCHOCERCIASIS

Onchocerciasis, also called river blindness in cases where eyes are involved, is an infectious disease caused by the parasite *Onchocerca volvulus*, a nematode worm which is spread by the bite of an infected black fly (species of *Simulium*). It is the world's second leading infectious cause of blindness.

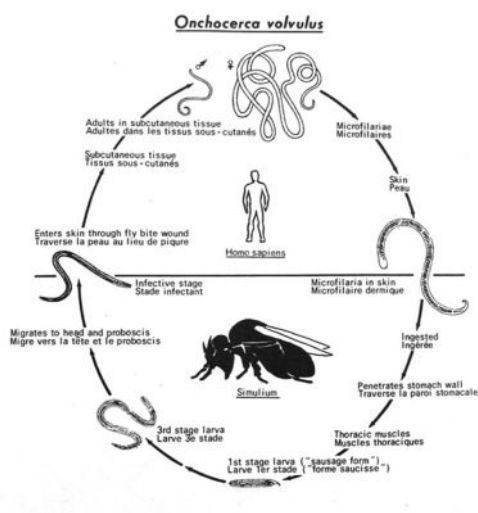
The disease is present in Sub-Saharan Africa (more than 99% of all cases). Isolated foci also exist in the Central and South Americas and in Yemen. The infection is transmitted in rural areas



The consequences of onchocerciasis extend beyond the individual and affect the family, the community and the region. In many of the African countries it constitutes a public health problem. In hyper-endemic areas the disease is responsible for poor school performance and higher drop out rate among infected children, due to itching, lack of sleep and malaise. Among heavily infected adults low productivity, low income and higher health related costs are common. In these areas onchocerciasis induced blindness is associated with a life expectancy that is shorter than that of non-blind individuals in the same area.

## THE PARASITE

The causal agent of onchocerciasis is *Onchocerca volvulus*, belonging to the superfamily *Filaroideae* (threadlike worms). The life cycle:



*O. volvulus*, a filiform white worm, related to other threadlike worms that infect animals including cattle and horses, has two manifestations: the adult worms, the **macrofilariae** and the larvae, the **microfilariae**. Adult worms are free living or present in subcutaneous nodules which form a characteristic feature of the disease. Most nodules contain several worms of both sexes coiled up. The adult worms live for years (up to 15 years). The females can measure over 50 cm in length. They are ovoviviparous: bearing larvae that hatch from eggs inside the body of the maternal organism. The 50 cm long uterus of the gravid female is filled with eggs containing microfilariae in all stages of develop-

ment. A female onchocerca gives daily birth to thousands of microfilariae.

The males measure only 2-4 cm. Their only task is to fecondate the females.

The uterus of *O. volvulus* is surrounded by symbiont *Wolbachia* bacteria which are essential for the embryogenesis and survival of the female worm. Its discovery is of great importance for the fight against river blindness. It opens ways towards new strategies and remedies. Microfilariae are mainly found in the skin, but have been found in any part of the body. Their size is about 300 µm, well visible with a 25x magnification. Their tails are pointed and curved in a hook (=onchos). They are actively motile and often migrate beneath the skin. Their span of life is not exactly known. Homo sapiens is the definitive host and usual reservoir of the infection.

Intermediate host, the vector, is a certain species of *Simulium*, a genus of flies, also called black flies or "moute moute". They are three to four millimeters long. The female simulia are ferocious biters, excellent flyers (radius of action up to 200 km). Her eggs are laid on rocks, plants or even on crustaceae (crabs) near or in rapidly running streams. They require well-oxygenated water to mature into larvae, pupae and flies. Their life span is about 4 weeks.

#### DEVELOPMENT OF MICROFILARIAE IN THE FLY

Microfilariae are ingested by the female simulium fly during her blood meal -required for her ovulation- on an infected human host. Those who escape from the insect's stomach into its tissues develop in the thoracic muscles and become converted into infective larvae that reach the salivary glands and mouthparts, ready to enter the human host during her bite. This maturation lasts about 10 days.

#### DEVELOPMENT OF MICROFILARIAE IN THE HUMAN HOST

After entering the skin the infective larvae migrate through the subcutaneous tissues where over the next 12 months each larva will mature into an adult female or male. The adult worms pair and mate, producing millions of microfilariae during a decade.

#### PATHOPHYSIOLOGY

Most microfilariae die as immature worms in

the host. Their degeneration and death cause an intense inflammatory reaction that is responsible for most of the morbidity in onchocerciasis. Alive the microfilariae mask their presence to the immune system of the infected person. But dying microfilariae induce cell-mediated and humoral inflammatory responses. The lymph nodes that drain infected areas show granulomatous inflammation, fibrosis and atrophy. The dying microfilariae provoke the onchocerciasis syndrome that includes dermatitis, blindness, lymphadenitis, malaise and much other discomfort. Onchocerciasis may become a systemic disease.

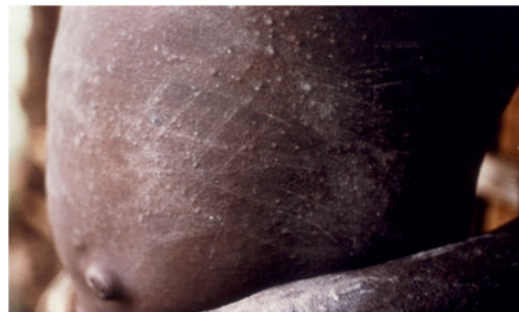The role of *Wolbachia* bacteria in the inflammatory response is interesting. *O. volvulus* and other nematodes harbour endosymbiotic *Wolbachia* bacteria throughout their lifecycles and they are passed onto the next generation of worms through the oocyte, much like an inherited characteristic. The worm relies on these intracellular bacteria for its homeostasis.

It is clear that *Wolbachia* play a main role in the pathogenesis of ocular onchocerciasis in the human host.

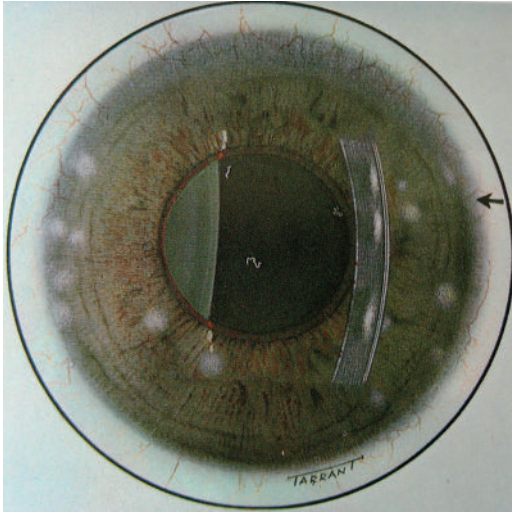
#### CLINICAL MANIFESTATIONS

##### *Skin*

The earliest skin involvement is mild to heavy pruritus and may be followed by papular rashes, by scratch marks and eventually secondary infection. In highly endemic regions the itching increases until about 25 years. This prurigenous condition is called in some African regions "craw-craw", the sound of scratching with a potsherd. In chronic cases the classic dermal lesion is named "leopard skin", characterized by patchy depigmentation and hyperpigmentation. An atrophied and scaling skin is called "lizard skin".



*Onchodermatitis*



*Cornea: punctate keratitis: occurs in reaction to dying microfilariae in stroma of the cornea. Around the dying microfilariae an infiltrate appears, leading to fluffy or “snowflake” opacities. These lesions are reversible and disappear within a few weeks. Wolbachia bacteria play a role in this inflammation. These opacities can be observed already in young children. These lesions are reversible.*

Onchocercomas are the characteristic subcutaneous nodules, collections of adult worms coiled together and surrounded by fibrous tissue; important sign, sometimes difficult to distinguish from atheromas and cysts.

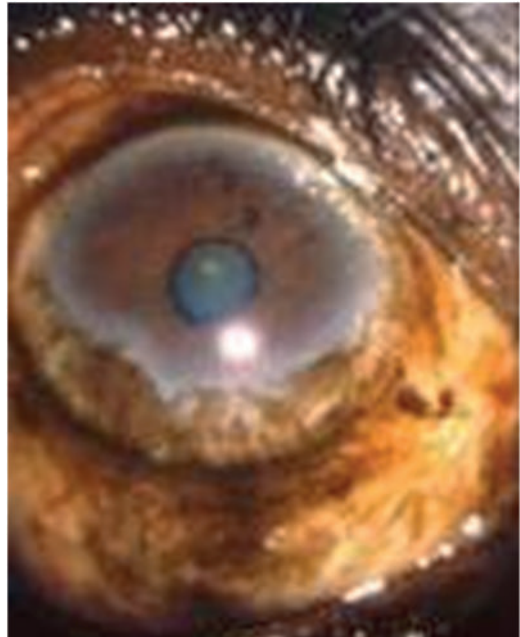
### Eyes

Microfilariae (mf) can enter the eye along several routes: invasion from the skin along the subconjunctival tissues, through the bloodstream, via the sheaths of the penetrating scleral vessels. Changes can occur in practically all tissues of the eye, from the cornea to the optic nerve.

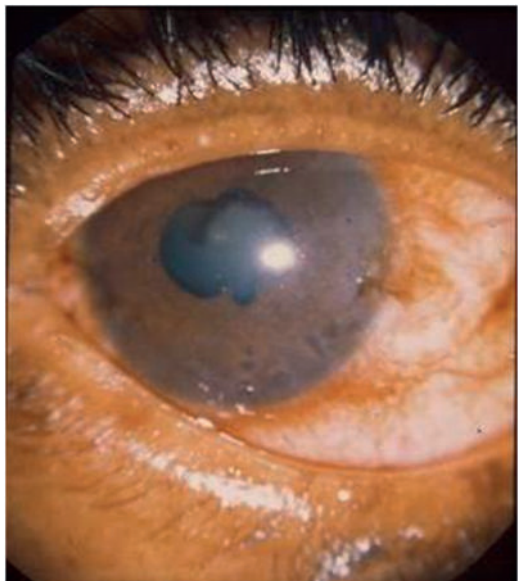
**Conjunctiva** : hyperaemia, oedema (cheimosis), limbitis.

**Anterior chamber**: observing with the slitlamp the presence of swimming and twisting microfilariae confirms the diagnosis. In slight infections inflammatory reactions are not visible.

**Secondary glaucoma**; must be checked, an important complication in onchocerciasis, often accompanied by goniosynechiae. In regions where onchocerciasis is endemic, glaucoma is more prevalent than in non-oncho regions. Glaucoma in young individuals is not rare in hyperendemic regions.

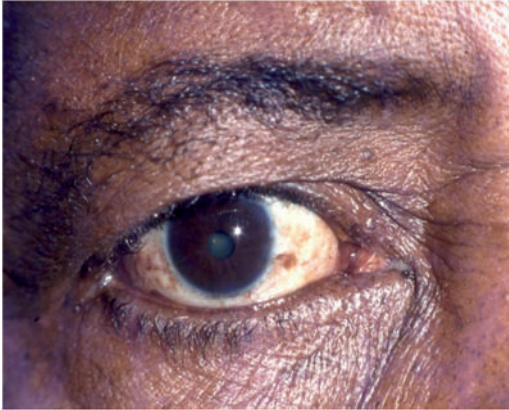


*Sclerosing keratitis develops in longstanding heavily infected patients, showing loss of clear corneal stroma. Corneal haze begins in the lower parts and in the interpalpebral margin of the limbus, extending downwards and centrally. Blindness occurs if the opacity gradually progresses to cover the central area of the cornea. The whole cornea may become opaque*

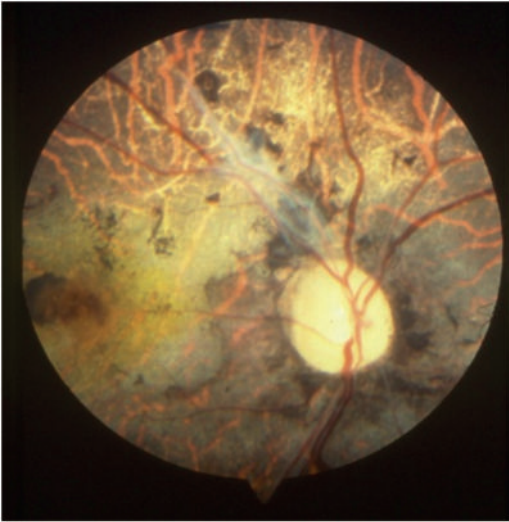


*Anterior uveitis (iritocyclitis), may be mild, may be chronic, may be acute and severe.*

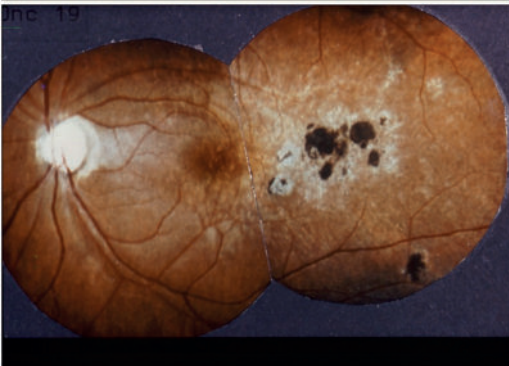




*Downward dragged pupil: A hidden small hyphema in the inferior part of the anterior chamber drags the pupil downward, leading to an eccentric downward placed pupil, often in both eyes.*



*Optic neuritis*

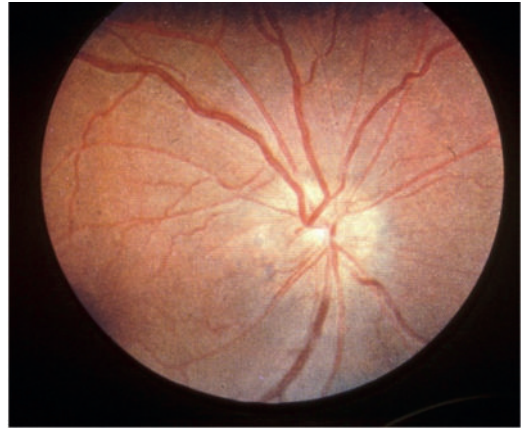


**Posterior pole:** Degenerative chorioretinitis, **onchocercal chorioretinopathy**. A wide

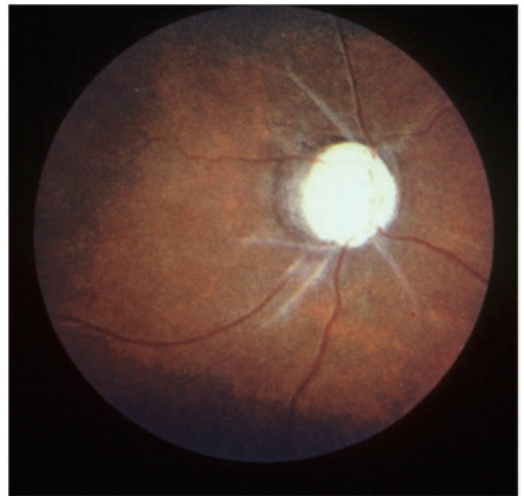
spectrum of fundal changes. Most striking is the atrophy of retinal pigment epithelium and of the choroidal capillaries. Further areas of severe atrophy, well and sharply demarcated zone between atrophic and normal retinal tissue, a typical distribution of the lesions.

The typical distribution of the lesions is attributed to the presumed entry of microfilariae in the eye via the short ciliary arteries. In later stages fibrosis and -rarely- neovascularisation can be seen.

Characteristic is pigment clumping within the pigment epithelium. (Comparable with the



*Optic atrophy*



pigment clumping in the skin.)

**Optic neuritis** **Optic atrophy** Microfilariae have been found within the optic nerve and in its sheath. It is plausible that the death of


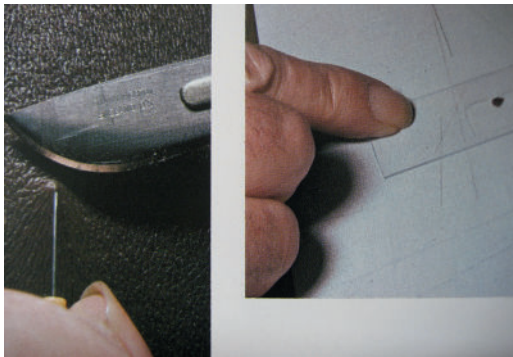


these microfilariae initiates the inflammatory response. Also in children and in young people active optic neuritis is seen. (Swelling of the optic disc, hyperaemia, blurring of the edges of the disc.) This inflammation in combination with the loss of ganglion cells in the retina may be responsible for optic atrophy. Optic atrophy is more commonly seen in onchocerciasis regions. Glaucoma can also attribute to the process of atrophy.

**The pathogenesis** of all these manifestations is a result of a large variation in the immune responses of each patient. Hypersensitivity reactions occur, directed against the dying and dead microfilariae, both in their natural death and after treatment with microfilaricides like ivermectin.

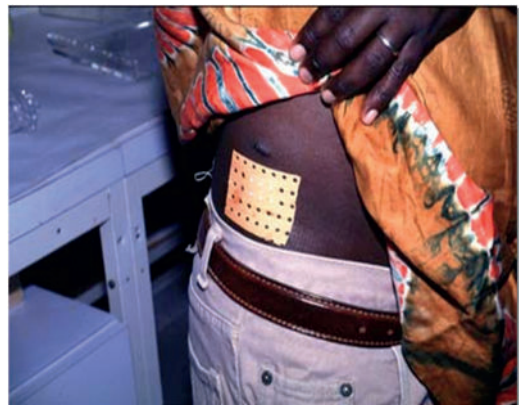**Diagnosis** in the individual patient: by clinical picture and by demonstration of the presence of microfilariae in the skin.

- a) By means of a **skin snip**: a small piece of skin is taken, 1 or 2 mg. preferable with a special punch and is suspended in saline. After a few minutes the microfilariae escape from the snip and it is possible to see them moving actively under the low magnifica-

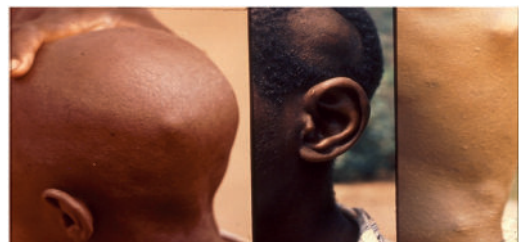


tion of the microscope to be counted. This method can give many false negative results. The skin snips can be taken from different parts of the body, e.g. the pelvis, the iliac crest. Or from the outer canthus since the density of microfilariae at this site correlates with ocular involvement. Be aware: Taking a skin snip has a risk for HIV contamination.

- b) **By a DEC patch:** The diethylcarbamazine (DEC)-test in an aerated plaster is an elegant and cheap alternative. This test is more sensitive than the skin snip. DEC is a microfilaricidal drug, which has an “unmasking” effect on the microfilariae: the mf are suddenly recognized by the immune system of the patient and as a result an inflammation in the skin will appear. The DEC-patch test is non-invasive, simple and cheap; a good alternative to the skin-snip method.



**Diagnosis** in the community is easy and not bloody: by counting the mean number of nodules (onchocercomas) in a village, a method used by the APOC, the African Programme for Onchocerciasis control.



**Control programs** for onchocerciasis belong to the most successful and are the longest running

programs to control an infectious disease in developing countries. The current strategy of the African Program of Onchocerciasis Control (APOC) is to treat the entire population of meso- and hyperendemic communities where prevalence of positive skin snips is at least 40% or the prevalence of palpable nodules is at least 20%.


**Treatment** consist of an oral dose of **ivermectin** (150 microgram/kg bodyweight) administered annually to all eligible individuals. The strategy has proven to be highly effective in reducing infection intensity, prevalence and microfilaria load. Presently the disease has been eliminated as a public health problem in 11 West African countries. In 17 other countries, most in Sub-Saharan Africa, approximately 20 % of the population at risk is being treated. Ivermectin acts on microfilariae by killing them and reducing their production by temporarily inhibiting the release of intrauterine mf from female worms, but does not kill adult female worms. Given the very long lifespan of adult female worms (about 13 years), it has been estimated that mass drug treatment should be continued for a minimum of 20 years or even more, depending on the coverage and other factors.

**THE CHALLENGE OF ONCHOCERCIASIS AND LOIASIS CO-ENDEMICITY**

A serious obstacle in river blindness control is the co-endemicity of onchocerciasis and loiasis in West- and Central Africa.

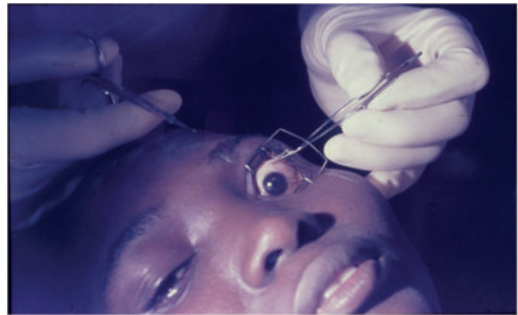
**Ivermectin, which is a microfilaricidal drug, is contraindicated in patients with a co-infection of loiasis and onchocerciasis!**

*Loiasis*



*Life cycle of Loa loa*

The life cycle of the filaria worm *Loa loa* is comparable with *O. volvulus*. The intermediate host is the *Chrysops* fly, the definitive *Homo sapiens*. The microfilariae of *Loa loa* are mainly present in the blood, those of *O. volvulus* in the skin.



*Removal of adult Loa loa worm from conjunctiva*

In several parts of West-Central Africa both parasites are endemic in the same area. The death of massive numbers of microfilariae of both parasites *Loa loa* and *O. volvulus*, but especially those of *Loa loa* present in the (pre-) capillaries in the central nervous system, can lead to emboli and thrombus formation causing vascular obstruction. **These events lead to encephalopathy, coma and death** and in the eye to hemorrhages of conjunctiva and retina; as well as to vascular obstructions and bleedings in other organs. These serious complications are also damaging the campaigns and leading to juridical charges.

A term has been given for this set of complications: neurologic serious adverse events (SAE's)

More research is needed into the mechanisms of post-ivermectin treatment SAE to develop drugs that are appropriate to individuals suffering from multiple parasitic infections.

**WOLBACHIA BACTERIA AND DOXYCYCLINE**

In 2007 it was shown that a 6-week administration of 100 mg/day of doxycycline to onchocerciasis patients led to a strong decrease of *Wolbachia* bacteria from adult worms. This was associated with a long-term cessation of embryogenesis and consequently of microfilariae production and even with the death of the female worms. while having no effect on the microfilariae of *Loa loa*.

**Therefore doxycycline without ivermectin can be considered for treatment in regions with coincidence of onchocerciasis and loiasis in an individual.**

While the use of doxycycline is not amenable for mass drug administration, because six weeks long courses are not feasible, it could be applied in the treatment of individual cases.

**The great pharmaceutical objective is to evaluate macrofilaricidal drugs for the mass treatment of onchocercal- and lymphatic filariasis in the large central-western parts of Africa where loiasis also is endemic.**

The onchocerciasis story will be continued.

# TRANSFORMING A PAPERCLIP INTO AN EYE-OPENER


**Aim:** inspection of the eye.  
These paperclip retractors proved to be as feasible as the eyelid retractors of Desmarres.

## MATERIALS

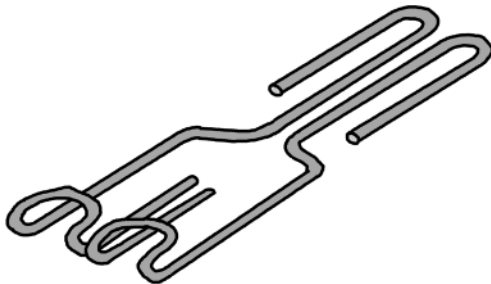
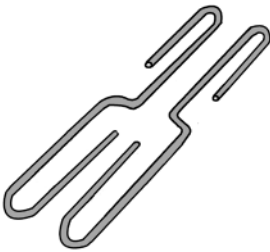
- Paperclips or wire
- Long-nosed (needle-nosed) pliers

## CONSTRUCTION

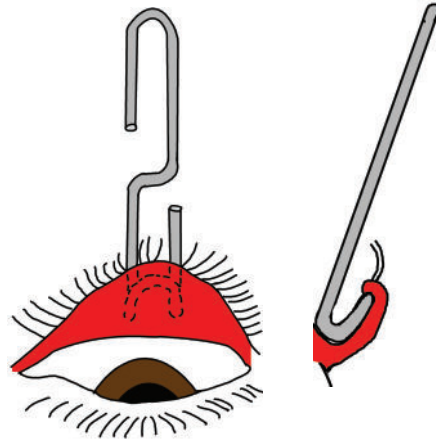
Bend the paperclips according to the drawings or into any other shape one prefers. Long-nosed pliers facilitate the bending of the paperclip.




USE



Prior to use, the bent portion of the paperclip, the retractors, should be held in a flame for a few seconds and allowed to cool. This will prevent contamination of the eye.



*Fig. 1 Double eversion of the upper eyelid for inspection of the superior cul de sac.*



*Fig. 2 Examining a child's eye. The picture shows one assistant holding the eye open and immobilising the child's head at the same time. The battery-torch provides lateral illumination of the eye and reveals corneal and conjunctival abnormalities clearly, especially if the eye has been stained with fluorescein.*

After use, the retractors must be cleaned and kept in 70% alcohol or in acetone.

# ACUTE RED EYES

MARGREET HOGEWEG, OPHTHALMOLOGIST,

CBM MEDICAL ADVISOR CENTRAL EAST ASIA

Acute red eyes, with or without pain, are common in any general outpatient clinic. Immediate diagnosis and treatment are necessary: all eyes blinded as a result of corneal scarring once started as 'acute red eyes'. Diagnosis can usually be made by careful inspection. If treatment is started promptly it is often successful and rewarding.

As many as 40% of all outpatients at an eye department present because of red eyes!

The main causes of 'acute red eye', in order of frequency, are:

1. acute conjunctivitis (very common),
2. corneal lesions, including trauma (common),
3. acute iritis (uncommon),
4. acute glaucoma attack (rare).

For the differential diagnosis between conjunctival and intraocular causes, it is important to distinguish between painless and painful, and normal visual acuity versus diminished visual acuity respectively. Redness in conjunctival disease is bright and diffuse, whereas redness in intraocular conditions is more purple in colour and located immediately around the cornea.

Watering and photophobia are rather aspecific symptoms (table 1).

Slightly red and irritated but otherwise normal eyes are common in hot and dusty climates only need reassurance. Sunglasses may help.

A careful history is important, particularly in case the redness is related to trauma.

## EXAMINATION:

The eye should be examined systematically: from outside in.

|              |                                                                                                                                                                                         |
|--------------|-----------------------------------------------------------------------------------------------------------------------------------------------------------------------------------------|
| Eye lids     | Any inward lashes touching the cornea?                                                                                                                                                  |
| Conjunctiva: | Any discharge? Redness? Diffuse and bright, or pericorneal and more purple?                                                                                                             |
| Cornea:      | Any corneal abrasion, foreign body or greyish infiltrate? Cornea hazy?                                                                                                                  |
| Pupil:       | A normal pupil is round and reacts to light. If constricted and irregular: suspect acute iritis. If dilated and not reacting to light: suspect acute glaucoma (or the use of atropine). |

## Extra:

|    |                                                                                                                                                                       |
|----|-----------------------------------------------------------------------------------------------------------------------------------------------------------------------|
| a) | Stain the cornea with fluorescein to make any corneal epithelial defect easily visible, e.g. corneal abrasion, ulcer or herpetic dendrite.                            |
| b) | Evert the upper eye lid to detect a foreign body lodged in the conjunctiva of the upper eye lid, or the typical follicles of trachoma or vernal keratoconjunctivitis. |
| c) | If considering acute iritis: dilate the pupil with a short-acting mydriatic (tropicamide) to demonstrate synechiae (adhesions between iris and lens)                  |
| d) | If considering acute glaucoma: palpate the ocular tension digitally and compare with the other eye.                                                                   |
| e) | If considering a blocked lacrimal sack: press on the area of the tear sack: pus will well up.                                                                         |

## ACUTE CONJUNCTIVITIS

There is a purulent or watery discharge, some discomfort, but no real pain. No history of trauma. Normal visual acuity. The cornea and pupil are normal. Conjunctivitis often starts unilaterally, but gradually becomes bilateral. Conjunctivitis may occur in epidemics and in certain seasons and can be bacterial (Fig.1), viral or allergic. It is by far the commonest cause of acute red eye.

Treatment: repeated cleaning of the eye throughout the day with clean (drinking) water; boiling is not necessary. Most cases of conjunctivitis will settle within one week. In



TABLE 1: The acute red eye.

| signs & symptoms | conjunctivitis                                              | Vernal conjunctivitis                                                                   | corneal lesions                                                                                           | acute iritis               | acute glaucoma                                                   |
|------------------|-------------------------------------------------------------|-----------------------------------------------------------------------------------------|-----------------------------------------------------------------------------------------------------------|----------------------------|------------------------------------------------------------------|
| eye              | usually both eyes                                           | usually both eyes                                                                       | usually one eye                                                                                           | usually one eye            | usually one eye                                                  |
| pain             | none or some discomfort                                     | severe itching; photophobia                                                             | pain and photophobia                                                                                      | pain and photophobia       | severe pain; at times nausea & vomiting                          |
| redness          | diffuse, bright red                                         | peri-corneal with limbal thickening                                                     | peri-corneal; purplish                                                                                    | peri-corneal               | peri-corneal & diffuse purple                                    |
| discharge        | sticky or watering                                          | some, thick & stringy                                                                   | Sometimes sticky                                                                                          | watering                   | watering                                                         |
| vision           | unaffected (after cleaning)                                 | ↓ or unaffected                                                                         | ↓ depending on location of lesion                                                                         | ↓↓                         | ↓↓↓↓                                                             |
| cornea           | clear                                                       | punctate keratitis; corneal scarring                                                    | superficial defect, FB, grey white infiltrate                                                             | clear or slightly hazy     | diffuse hazy, due to oedema                                      |
| pupil            | normal                                                      | normal                                                                                  | normal or slightly constricted                                                                            | constricted                | mid-dilated & not reacting to light                              |
| special features | purulent or watery discharge                                | Children; cobblestone follicles below upper eyelid                                      | stains with fluorescein                                                                                   | irregular after dilatation | Intra-ocular pressure ↑↑↑                                        |
| treatment        | cleaning and topical antibiotics or diluted betadine (0.5%) | cold compress; sunglasses; longterm Chromoglycate 2%; topical steroids in exacerbations | frequent application of topical antibiotics or diluted betadine (0.5%); urgent referral if no improvement | Atropine; topical steroids | Acetazolamide 500 mg, timolol, pilocarpine; referral for surgery |

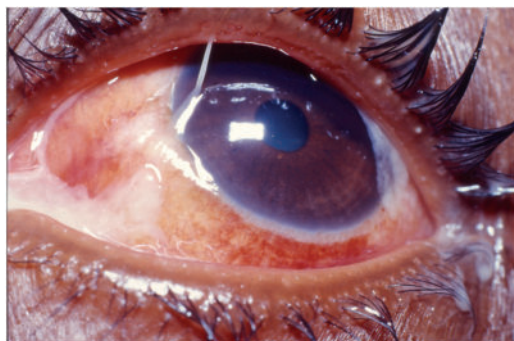


Fig 1. Acute bacterial conjunctivitis

addition to cleaning, topical antibiotics such as chloramphenicol (0.5%), 6x /day may be given. Tetracycline eye ointment is equally effective, but sticky and less comfortable. As an inexpensive alternative, betadine (10% solution) can be diluted to a 0.5% solution with 95 ml normal saline from an IV pack and put in a pre-sterilised eye drop bottle.

In viral haemorrhagic conjunctivitis ('Apol-

lo' in W. Africa) it is useful to prescribe topical antibiotics, or betadine 0.5% to prevent patients from using potentially harmful traditional medicines instead.

### VERNAL KERATOCONJUNCTIVITIS (VKC)

A special form of allergic conjunctivitis is vernal keratoconjunctivitis (VKC) (fig. 2 a&b ) common in hot climates and mainly affecting children between 3-16 yrs, especially young boys.

It is a chronic condition, with flare-ups and causes severe bilateral itching, photophobia and burning. Typical for the diagnosis are the flat follicles, also called 'cobblestones', under the upper eye lid. For this, the upper eye lid needs to be everted, as in trachoma. Large raised follicles in a ring around the cornea are also common. The cornea itself may get affected as well and VKC can ultimately lead to permanent visual loss. Treatment is difficult: Cold compresses and sunglasses may give some relief. In addition long term application of mast cell stabilizers (3-

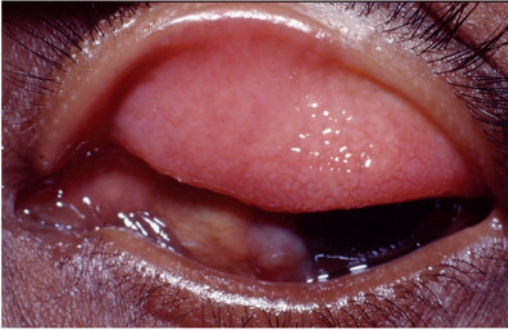

Fig. 2a Vernal keratoconjunctivitis, with cobblestone follicles on the inner side upper eyelid

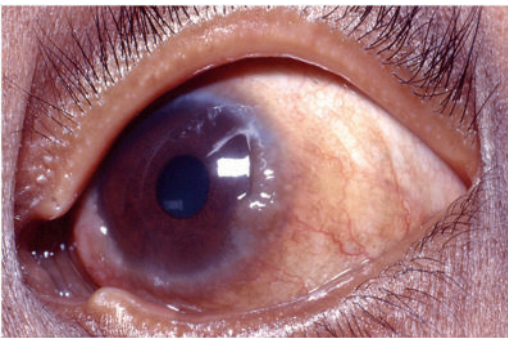


Fig. 2b vernal keratoconjunctivitis, peri-corneal follicles

4x daily), such as cromoglycate 2%, with topical steroids in exacerbations is required. It is sometimes difficult to distinguish between VKC and trachoma, as both have follicles under the upper eye lid and both conditions may also co-exist. Severe cases should be referred to a secondary or tertiary eye department. (For conjunctivitis of the new-born, see *Conjunctivitis of the Newborn*, N.Buisman and others. p. 13. )

### CORNEAL LESIONS

These give rise to a typical red and painful eye. The cause is often a superficial defect, due to trauma, trichiasis or a foreign body (FB), stuck on the cornea. Untreated, these may develop into a corneal ulcer, which either can cause loss of vision due to corneal scarring or even complete loss of the eye as the result of perforation. Correct diagnosis and immediate treatment are therefore of utmost importance.

Corneal abrasion: this is a superficial defect, often sustained during agricultural work, with a 'FB feeling'. It presents as an irregularity on the

corneal surface and is easily made visible with fluorescein. Treatment: antibiotic eye ointment with eye pad for 1-2 days, or until the defect has healed. Immediate treatment of corneal abrasions can prevent almost all corneal ulcers. If the abrasion is caused by inverted eyelashes, epilate these lashes and refer for lid surgery, to evert the lid margin.

Foreign body (FB): a detailed history and careful inspection will confirm the diagnosis. If there is a FB feeling, with excessive pain but without visible FB, evert the upper lid, as a FB may be lodged there and cause pain with every blink.

Treatment: a local anaesthetic drop (tetracaine 1%; alternative: repeated lidocaine 2% for injection) followed by blunt removal of the FB with a moistened cotton stick. If the FB is imbedded, careful removal with a corneal 'spud' or injection needle is required. To accomplish this, one needs adequate light and, in order to prevent sudden head movements, the patient should lay down. A 2.5x magnifying headband loupe will be helpful. Following removal apply an antibiotic eye ointment and eye pad for 1-2 days, or until the defect has healed. In spite of pain and a persistent FB feeling, don't 'treat' with a topical anaesthetic as this is toxic and may irreversibly damage the cornea.

(see also *Traumatic Eye Lesions*, J.Stilma and others. p. 65.)

### CORNEAL ULCER

This is a corneal defect with greyish infiltrate and an intense red and painful eye (fig. 3).

In severe ulceration a hypopyon may form: a collection of pus, visible as horizontal sediment in the anterior chamber. Such ulcers can perforate and must be treated promptly and intensively; administer a loading dose of broad

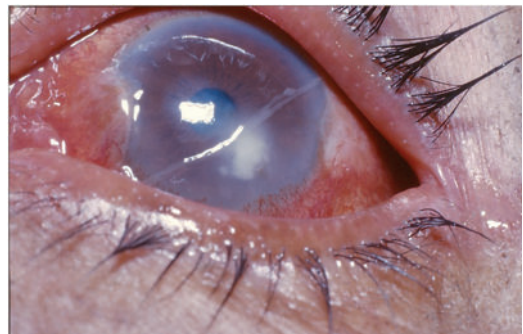


Fig. 3 Corneal ulcer

spectrum antibiotic eye drops every 5 minutes for the first two hours, followed by hourly drops for 48 hrs. Good combinations are Gentamycin/cefalozin or fluoroquinolones. (see also *Corneal ulcers*, v.d. Hoek, p.16)

Often the choice will have to depend on whatever antibiotic is available. In addition, administer atropine 1% 2x daily and analgesics. No eye pad. Systemic antibiotics are not needed because much higher doses of antibiotics can be obtained by 'soaking' the ulcer directly in topical antibiotics. In addition, subconjunctival injections of gentamycine (40mg/ml) can be given once daily. This ensures that sufficient antibiotics are given, but are not necessary if drops are administered with sufficient frequency. Corneal ulcers that do not improve on antibiotics and are due to a trauma by plant material may well be fungal. These are difficult to treat. Therefore immediate treatment with antibiotics of any corneal abrasion is of utmost importance. In children under 5 years of age who have corneal ulcers, it is prudent to give a single dose of vit. A, 500 000 IU, particularly in cases of measles or malnutrition due to a possible relationship with keratomalacia. ( See also *Xerophthalmia: measles and malnutrition*, N.Dekkers and others. p. 74.)

Traditional eye medicines (TEM) can also cause acute red eyes and corneal ulcers. Almost anything can have been put into the eye. Treatment by irrigation, if recently applied, and by frequent topical antibiotics. In addition health education to discourage the use of TEM.

Other causes of red eyes due to corneal conditions are not discussed.

### ACUTE IRITIS

This causes a painful red eye with a decrease in vision and photophobia but no discharge and no history of trauma. The cornea can be slightly hazy and, typically, the pupil is constricted if compared to the unaffected eye (fig. 4a). Roundness of the pupil and reaction to light is sometimes difficult to assess in a dark brown iris. Adhesions between the iris and the lens (posterior synechiae) form quickly and can be demonstrated easily by application of a short acting dilating drop, such as tropicamide or phenylephrine 5% (note: atropine may never be used as a 'diagnostic', because the pupil will remain dilated and accommodation lost for a period as long as two weeks). A clearly irregular

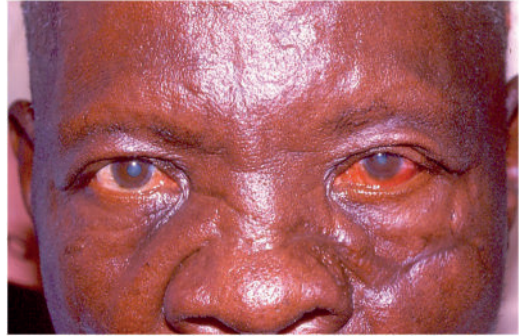

Fig. 4A Acute iritis left eye with constricted pupil in patient with leprosy

pupil confirms the diagnosis: iritis (fig. 4b).

A round and well-dilated pupil makes the diagnosis 'acute iritis' highly unlikely. Reconsider other causes, such as a viral conjunctivitis, which may pose, at times, quite an impressive clinical picture. Acute iritis is comparatively uncommon and the cause is usually unknown. It may be associated with tuberculosis, syphilis, HIV/Aids, onchocerciasis, leprosy, sarcoid, ankylosing spondylitis and many other systemic diseases.

Acute iritis, independently of the cause, is treated with topical atropine 1% 2 x daily and topical steroids drops 6-8 x daily (or 3-4 x daily with steroid eye ointment). Short acting mydriatics can be added temporarily to break the synechiae. There is no indication for systemic prednisolon. If, in severe acute iritis, the intraocular pressure is elevated, acetazolamide 250 mg, 3 x daily can be added for the first 1-2 days. Analgetics and sunglasses increase comfort. The treatment with atropine and steroids can usually be tapered off in 4-6 weeks. Any underlying

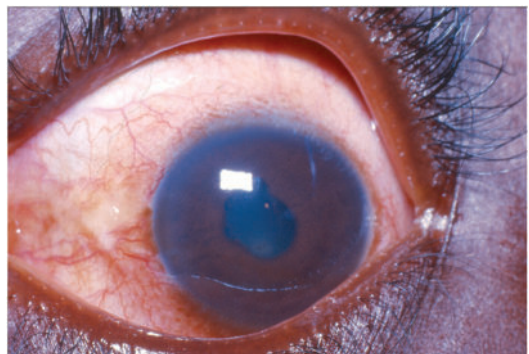


Fig. 4b Acute iritis left eye; after dilatation. Pupil not round due to synechiae posteriores



specific disease should, of course, be treated. In suspicion of acute iritis, patients should preferably be referred to an eye department.

### ACUTE GLAUCOMA

This causes a sudden acute red and very painful eye with severely decreased vision, a diffuse cloudy cornea and a (mid) dilated pupil. The anterior chamber is shallow. The intraocular pressure is very high and the eyeball may feel "stone hard" on digital palpation. The patient may be vomiting. It is typically a disease of the elderly, in particular elderly women. Acute glaucoma is rare in Africa, but not uncommon in Asia. A hypermature cataract, with a swollen lens, can trigger an acute glaucoma attack (fig. 5).

Emergency treatment: 500 mg acetazolamide orally; timolol 0.5% every 10 minutes for the first hour and pilocarpine 2-4% every 30 minutes until the pupil constricts and the pressure normalises. Thereafter referral for a peripheral iridectomy is necessary, to create a permanent opening between the anterior and posterior chamber. A prophylactic iridectomy in the other eye is highly recommended. In lens-induced glaucoma, a cataract extraction should be performed as soon as possible. The correct diagnosis and treatment of the acute red eye can prevent blindness: not every 'red

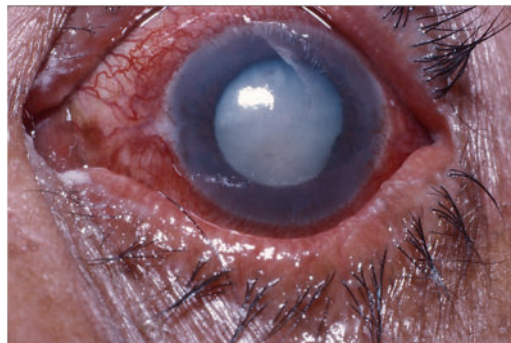


Fig. 5 Lens induced acute glaucoma

eye' is a conjunctivitis. In corneal abrasions and foreign bodies, immediate treatment with topical antibiotics and removal of the FB can prevent corneal ulceration and subsequent corneal scarring. Even the smallest health unit should have antibiotic eye ointment in stock!

If treated early, acute iritis can be cured without sequelae. Acute glaucoma has to be treated immediately, as otherwise the optic nerve will get irreversible damaged by sustained high pressure, resulting in blindness. Applying the correct treatment at the proper time is gratifying as it often leads to quick pain relief and cure!

Table 2 Basic Requirements for examination and treatment of the acute red eye

| Requirements for examination                                                                                                                                                                                                                                                                                                                                                                                                                                                                                                                                                                                                                                                                                                                                                                                                                               |
|------------------------------------------------------------------------------------------------------------------------------------------------------------------------------------------------------------------------------------------------------------------------------------------------------------------------------------------------------------------------------------------------------------------------------------------------------------------------------------------------------------------------------------------------------------------------------------------------------------------------------------------------------------------------------------------------------------------------------------------------------------------------------------------------------------------------------------------------------------|
| Vision chart (letters & illiterate E chart)<br>Penlight or focusable torch<br>2-4x magnifying loupe<br>Fluorescein strips<br>Short-acting dilating eye drops (tropicamide; phenylephrine 2,5-5%)                                                                                                                                                                                                                                                                                                                                                                                                                                                                                                                                                                                                                                                           |
| Requirements for treatment                                                                                                                                                                                                                                                                                                                                                                                                                                                                                                                                                                                                                                                                                                                                                                                                                                 |
| Topical anaesthetic (tetracaine 1%)<br>Cotton stick, corneal spud, injection needle<br>Epilation forceps<br>Antibiotic eye drops (e.g. chloramphenicol 0.5%; gentamycine 0.3-0.5%)<br>Antibiotic eye ointment (e.g. tetracycline e.o.)<br>Atropine 1% e.d./ e.o.<br>Short-acting dilating eye drops (tropicamide; phenylephrine 2,5-5%)<br>Topical steroids (often mixed with antibiotics, as drops or ointment)<br>Sodium cromoglycate 2% (for vernal keratoconjunctivitis)<br>Acetazolamide 250 mg<br>Pressure reducing drops (timolol 0.5%; pilocarpine 2%)<br>Povidone iodine 10% (can be diluted to 0.5% with normal saline, as cheap anti- infectious eye drop)<br>Vit. A 200 000 IU (for children with corneal ulcers)<br>Note: eye ointments have a longer shelf time than drops and are generally cheaper, but drops are more comfortable to use. |

## REFERENCE

1. Red eye: the role of primary care, Community Eye Health Journal, volume 18, Issue 53 March 2005  
<http://www.cehjournal.org/red-eye-the-role-of-primary-care/>



# THE RED REFLEX AND MORE, THE DIRECT HAND HELD OPHTHALMOSCOPE

1. PETER HARDUS , OPHTHALMOLOGIST, PREVIOUSLY DEPARTMENT OF OPHTHALMOLOGY GRONINGEN UNIVERSITY ,NIGERIA, ANGOLA

2. MARGREET HOGEWEG , OPHTHALMOLOGIST CBM S.E.ASIA MEDICAL ADVISOR; PREVIOUSLY DEPARTMENT OF OPHTHALMOLOGY LEIDEN UNIVERSITY

3. COEN KOPPERS, OPHTHALMOLOGIST ,NETHERLANDS TROPICAL COURSE, AMSTERDAM; THE NETHERLANDS SOCIETY FOR TROPICAL MEDICINE AND INTERNATIONAL HEALTH, CAMEROON, TANZANIA

4. JAN GEERT BOLLEMEIJER , OPHTHALMOLOGIST ROTTERDAM EYE HOSPITAL, FORMERLY ZIMBABWE

In circumstances where resources are scarce, one has to use simple methods. These methods are not automatically poor: an example of a simple efficient method is the red reflex examination: if the light of the ophthalmoscope is aligned along the visual axis, the pupillary space will appear as a reddish colour, the so-called red reflex. This is a reflection of the fundus colour, back through the vitreous, lens and cornea (same as red pupils on a photo). The red reflex is observed by holding the ophthalmoscope 30-50 cm. Dial the "wheel" of the ophthalmoscope to get the proper reflex and to focus well: dial the wheel to +2-+3. Any opacity located in the optical pathway will block this bright reflex and appear as a dark spot, or shadow. This shadow can be fixed or mobile: to judge mobility ask the patient to look up and down and then straight again; if there is a moving shadow coming along it must be in a fluid or gel : theoretically also in the anterior chamber, in practice in the vitreous.

If the opacity is stationary it is located in the lens (cataract) or on the cornea (scar, foreign body)

With a shift these days to more posterior segment pathology, including uveitis posterior, this examination is getting more important. If there is a very poor or absent red reflex this is usually due to a dense cataract, or, in rare cases, to a vitreous haemorrhage, retinal detachment or tumour.

When looking with + 10 D when looking at 10 cm (= 1/10 m) the red reflex can be judged

better but there is the risk of pupillary constriction due to more light. In that case, it is best observed after mydriasis with a short acting anticholinergic drug such as tropicamide (do not use atropine because the dilating effect of one drop can last for 14 days). Adding a sympathomimetic drug (such as phenylephrine 2.5%) to stimulate the musculus dilatator can help to get a wider pupil. Realize that in darker people it will be harder to get dilatation.

If dilatation does not result in a wide round pupil there probably will be synechiae posteriores: the iris is attached to the lens, a common clinical feature in uveitis. A trauma of the anterior part of the eye can result in an uveitis with synechiae posteriores but also in synechiae anteriores due to a previous perforation: the iris is plugging the hole in the cornea. Most of the times a corneal scar is then visible.

Inspection with the slit aperture, most of the times present on the ophthalmoscope and a loupe (or spectacles S+3) can help to differentiate. Let the slit come from the side.

Before dilating you will examine the pupillary reflex with the light of the ophthalmoscope. (Pupils Equally Reacting to Light and Accommodation (PERLA)). Just as judging the red reflex this is best done in a semi-dark room.

The ophthalmoscope is meant to see the fundus.(1) Dilatation is necessary because, due to the pupillary reflex, the pupil is contracting and it is hard to see the retina through a small hole. Looking at a fundus of a dark person can

be more difficult than of a Caucasian due to the darker appearance of the retina.

Realize that your refraction and that of the patient together have to be zero in order to get a sharp image.

Take the highest positive value because than the accommodation (of you or the patient) will be minimal. The value that shows a sharp picture of the retina gives you also an indication what the refraction error is.

An ophthalmoscope head is attached to a separate handle for the energy. Most handles, suitable for an ophthalmoscope head can hold an otoscope. So handy for the general practitioner.

The direct ophthalmoscope can also be used as an 'auto refractor': let the patient look through the ophthalmoscope and let him dial the wheel until the E chart is best seen. The chosen number on the wheel is a rough indication of the refractive error, if any.

Two more ophthalmological devices can be added. A retinoscope uses the red reflex to de-

termine the refractive error. This can be learned with a bit of patience.(2)

A special part is available for indirect ophthalmoscopy; together with a 20 dioptre lens one can judge the (peripheral) retina, The direct ophthalmoscope is excellent for judging the central retina.

Recently there is also the possibility to use a special part so that even pictures can be made with an iPhone.(3)

It can also be used as a loupe with illumination not only for eye purposes and even as torch for getting home. So it is an essential instrument for a general doctor in simple circumstances.

## REFERENCE

1. Tutorial direct ophthalmoscopy:  
<http://www.youtube.com/watch?v=leMexvs9HVU>
2. Tutorial retinoscopy (skiascopy):  
<http://www.youtube.com/watch?v=ezOoPKZwNDk>
3. <http://www.welchallyn.com/promotions/iExaminer/index.html>

# THE NEED FOR REFRACTIVE SERVICES IN LOW-INCOME COUNTRIES

G. JANSSEN, OPTOMETRIST, FORMERLY VIETNAM

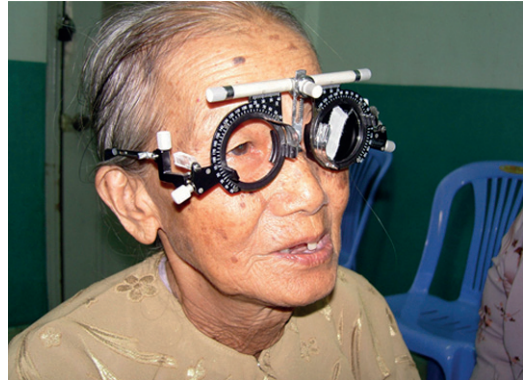Y.P. HENRY, OPHTHALMOLOGIST, FORMERLY PAPUA NEW GUINEA, VIETNAM

The World Health Organisation (WHO) estimates that there are 285 million people visually impaired worldwide: 39 million are blind and 246 million people have low vision. Blindness is, according to the International Statistical Classification of diseases, a visual acuity less than 3/60 in the better eye.

Low vision is visual acuity that does not improve beyond 6/18. Vision 2020 is the global action plan, intended to serve as a roadmap to consolidate joint efforts aimed at working towards universal eye health in the world. Uncorrected refractive error (URE) is the most common cause of vision impairment worldwide and the second most common cause of blindness.<sup>(1,2)</sup> Visual impairment from uncorrected refractive errors can have immediate and long-term consequences in children and adults, such as lost educational and employment opportunities, lost economic gain for individuals, families and societies, and impaired quality of life. Various factors are responsible for refractive errors remaining uncorrected: lack of awareness and recognition of the problem at personal and family level, as well as at community and public health level; non-availability of and/or inability to afford refractive services for testing; insufficient provision of affordable corrective lenses; and cultural disincentives to compliance.

The ideal ratio for the number of clinical refractionists is 1:50 000 specified by WHO and the International Agency for the Prevention of Blindness.

Refraction services can be integrated into existing eye health programs. Refractionists, opticians, ophthalmic assistants and others are deemed suitable to do this work. In some countries ophthalmologists also do also this work, but this decreases the time they can spend doing surgery. When looking at refractive services, eye care staff in most countries can do a subjective refraction by using a system of lenses in a



*Fig. 1 Patient with trial frame*



*Fig. 2 Trial set*

systematic way to determine whether and how vision can be improved. In some countries staff members can also perform an objective refraction, using a retinoscope or an autorefractor to determine the refractive error of the child or adult. This is particularly useful when working with young children and people who are unable to specify whether or not a lens improves their vision and where large numbers of patients are seen.

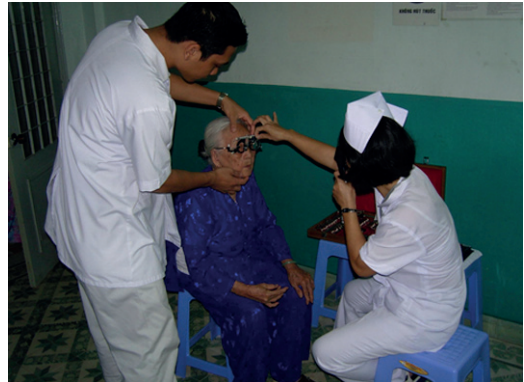Most people can be helped with a prescription of low power + or - lenses. Most of the time the frames and these lenses are locally available.

In remote areas access to glasses may need to be organized. In low income countries they often rely on external help from visiting professionals and non-government organizations. Some have responded with the use of recycled spectacles, universal spectacles, ready-made spectacles or glasses made elsewhere.

Getting recycled spectacles from the donor to the end user involves a number of potentially costly processes. The processes are donation, visual inspection, checking and sorting, cleaning, dispensing and travel costs. The costs of the recycled spectacles are estimated at least 1,5x more expensive than ready-made spectacles.(3) The recipients of the recycled spectacles are also receiving spectacles of variable and questionable quality of style, which are costing the programs involved time and money. A cash donation would be more worthwhile than the time and resources of donors and service groups involved in collecting and sorting recycled spectacles. The U-Specs (a universal spectacle) are based on the Alvarez lens principal (named after the inventor and Nobel Prize laureate, Luis Alvarez). The mechanism used to move the Alvarez lens parts, was invented and patented by VU University, Amsterdam. The power of each lens can be simply adjusted to suit the needs of the user. The spectacles have a dioptric range of - 6 to + 3 diopters. The disadvantage of the U-specs is the cosmetic component, it doesn't allow to correct the cylinders and the spectacles are in one size. The advantage is that the glasses are designed to be cheap, adaptable and easily distributable.(4)

In the age group 5–15 years, uncorrected refractive errors are due to several factors: the lack of screening, and the availability and affordability of refractive corrections are the most important. Screening of children for refractive errors should be conducted at community level and integrated into school health programs, accompanied by education and awareness campaigns to ensure that the corrections are used and cultural barriers to compliance are addressed and removed. Screening is most effective in children above 10 years of age because most myopia starts above the age of 10 years.

Special attention is needed for the people who have had a cataract operation. After a classic extracapsular cataract operation (ECCE) with intraocular lens (IOL) implantation the visual



*Fig. 3 Determining the refraction by skiascopy (retinoscopy)*

acuity can significantly improve if corrected (glasses). Especially with large incisions (ECCE + IOL) the residual astigmatism can be significant and need to be corrected to improve visual acuity. Small incision cataract surgery (SICS, phacoemulsification) with accurate biometry (for IOL calculation) will result in much less residual ametropia and the patient will have a much better uncorrected visual acuity. It is important that patients are examined postoperatively (2 - 3 months) and a refraction is performed in order to prescribe glasses if needed (improved vision).

Many countries have optical shops or workshops at the hospital, but without trained staff. To reduce poor vision and blindness through refractive services, the following conditions need to be attended.

Most importantly, a country or area needs eye care staff trained in refraction (subjective and/or objective), easy access to refraction services and access to affordable glasses. Training and information programs should also be designed for teachers and school health-care workers. Refraction services need to be integrated with eye-care systems and included as a part of cataract surgery services. Impairment from uncorrected refractive errors, provision of refractive services and outcomes of the provisions should be monitored at national level to identify communities in need.

## REFERENCES

1. Resnikoff, Pascolini D, Mariotti S, Pokharel P. Global magnitude of visual impairment caused by uncorrected refractive errors in 2004. *Bull World Health Organ* 2008;86:63-70. doi:10.2471/BLT.07.041210 PMID:18235892
2. Holden BA, Fricke T, Ho S, Wong R, Schlenker G, Cronje S et al. Global vision impairment due to uncorrected presbyopia. *Arch Ophthalmol* 2008;126:1731-9. doi: 10.1001/archophth.126.12.1731 PMID:19064856
3. David A. Wilson, Sonja Cronje, Kevin Frick, and Brien A. Holden. Real Cost of Recycled Spectacles. *Optom Vis Sci* 2012;89:304-309
4. <http://www.u-specs.org/?page=21222>

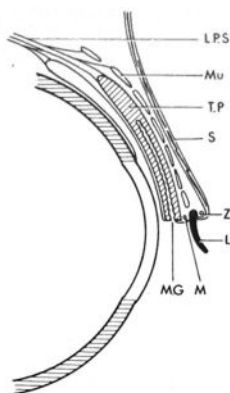


# STYE AND OTHER AFFECTATIONS OF THE EYE LIDS

H.C.KOPPERT, OPHTHALMOLOGIST, NETHERLANDS TROPICAL COURSE, AMSTERDAM; THE NETHERLANDS SOCIETY FOR TROPICAL MEDICINE AND INTERNATIONAL HEALTH

## ANATOMY

Anteriorly the lids are covered by skin and posteriorly by mucous membrane, the conjunctiva tarsi. In between muscle, glands, blood vessels, and nerves are bound together by connective tissue which is dense at the posterior part where it forms a stiff plate, the tarsus.



Vertical section through eyelid:

- |                                    |                              |
|------------------------------------|------------------------------|
| L = lash                           | TP = tarsal plate            |
| LPS = levator palpebrae superioris | Z = sebaceous gland of Zeiss |
| S = skin                           | M = sweat gland of Moll      |
| MU = orbicularis muscle            | MG = Meibomian gland.        |

The hair follicles of the eyelashes are, just as in skin hair, follicles provided with sebaceous glands. In eye lashes they are termed glands of Zeis. Between the follicles the glands of Moll are found.

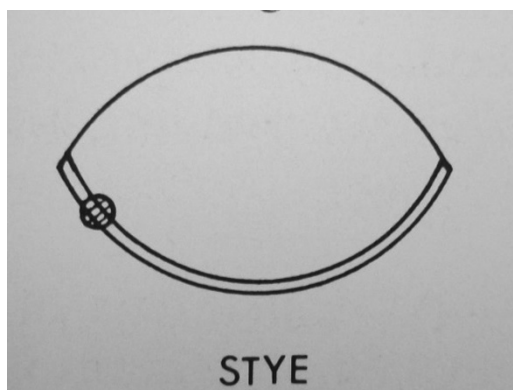
## STYE

(Latin: *hordeolum*, French: *orgelet*, Dutch: *strontje*)

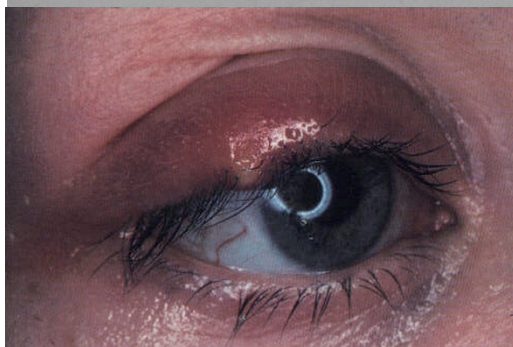
A stye is the result of the infection of either type of gland and of the eyelash follicle itself.

Signs and symptoms: the eyelid becomes swollen (oedematous) and painful. As a result the distance between the eyelids (the palpebral fissure) becomes smaller.

Course: Normally a stye is an innocent infection



STYE

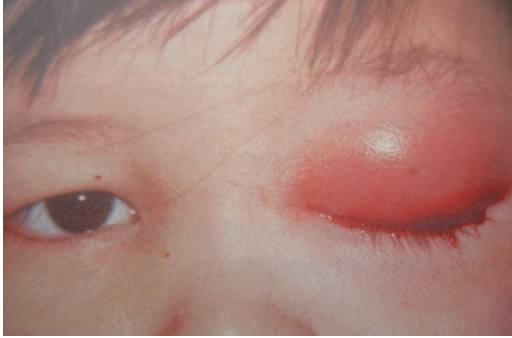

that heals either spontaneously or by a small abscess which discharges itself through the skin or around the base of an eyelash.

## A SERIOUS COMPLICATION: ORBITAL CELLULITIS

In children with a deficient immune system a stye may become a phlegmon (=cellulitis =inflammation of the connective tissue) and the infection may spread to the orbit. If the infection restricts itself to the anterior part of the orbit the term preseptal orbital cellulitis is used. If it spreads posteriorly the term **postseptal orbital cellulitis** is used.

In **preseptal orbital cellulitis** oedema of the eyelid causes **ptosis** (=drooping of the upper eyelid), making it difficult to examine the



*Preseptal orbital cellulitis*

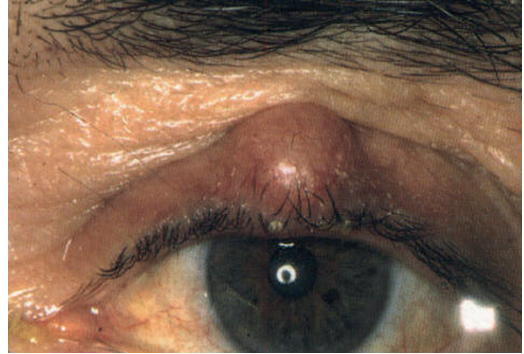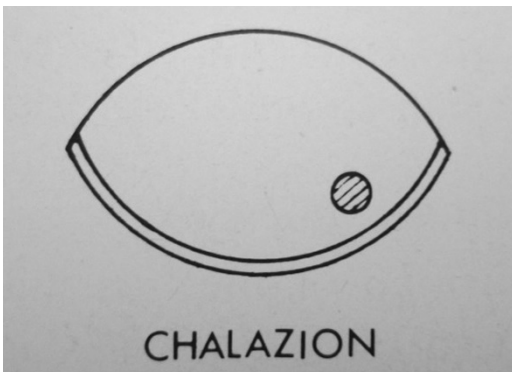
eyeball. A lid retractor is used to examine vision and eye movements, which are usually normal. In **postseptal orbital cellulitis**, which is usually caused by a severe paranasal sinus infection, there is a painful swelling of the eyelids and proptosis (=forward displacement of the eyeball) and restriction of the eye movements. The patient is usually seriously ill.

Treatment: systemic administration of antibiotics is necessary to prevent a life threatening infection from spreading to structures behind the orbit: the meninges and cavernous sinus. The infection may heal by absorption or by forming an abscess.

**CHALAZION, ALSO CALLED TARSAL CYST OR MEIBOMIAN CYST.**

Chalazion is a chronic granuloma of a meibomian gland.

Each eyelid is reinforced with a plate of dense connective tissue, the tarsal plate. In this tough plate the long vertically placed sebaceous glands are embedded, the meibomian glands. Each gland opens at the eyelid margin.

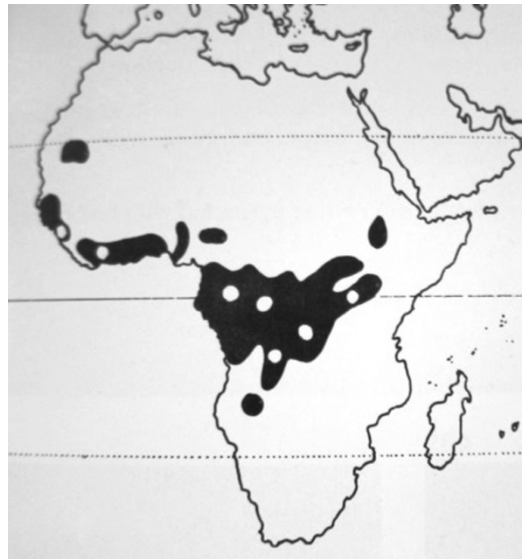


Signs and symptoms: In chalazion the gland becomes swollen, increasing in size gradually, mostly without inflammatory symptoms. The patient seeks advice as a result of disfigurement. Treatment: the chalazion should be incised after local anesthesia and scraped with a special chalazion spoon.

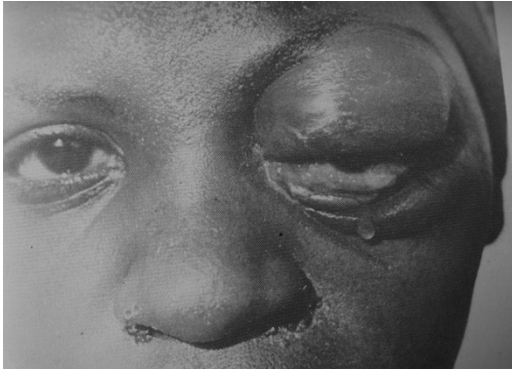Occasionally an acute bacterial infection develops in a meibomian gland and, as in the case of stye, the infection may spread to the orbit. In that case systemic antibiotics should be administered.

**CALABAR SWELLING OF THE ORBIT, LOAIASIS**

In regions where the filarial parasite *Loa loa* is transmitted by the *Chrysops* fly (West-Central Africa), a Calabar swelling in the orbit can imitate a bacterial orbital cellulitis. In loaiasis the patient is not seriously ill. Calabar swellings can also appear elsewhere on the body. Blood



samples show an increased eosinophil count and, perhaps, *Loa loa* microfilariae.

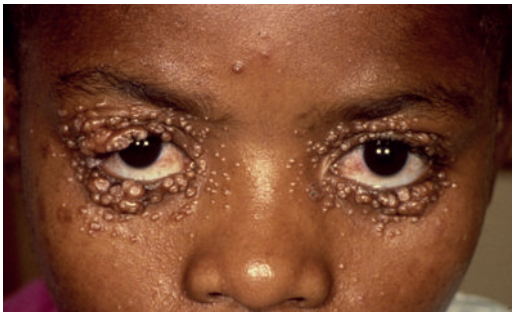

Treatment: mostly the swelling subsides spontaneously; antihistamines, (filaricides). Ivermectin is contraindicated!

### MOLLUSCUM CONTAGIOSUM

Molluscum contagiosum is a skin disease caused by a virus. (molluscus =soft)

Signs and symptoms: marked by small, rounded crateriform papules, containing caseous matter.



(Photo B. Naafs)



If a molluscum contagiosum occurs on the lid margin, virus may be shed into the conjunctiva where they trigger a follicular conjunctivitis. Also the cornea may be involved, showing small superficial infiltrates hardly visible with the

ophthalmoscope.

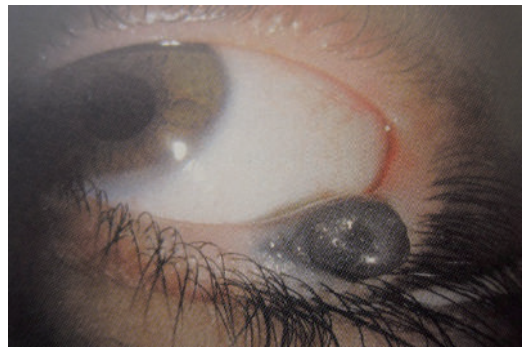Treatment: expectative or removal of the lesion on the lid margin with a small curette after a regional injection of procaine.

Be aware of **HIV/AIDS** in case of multiple lesions of molluscum contagiosum.

### KAPOSI SARCOMA

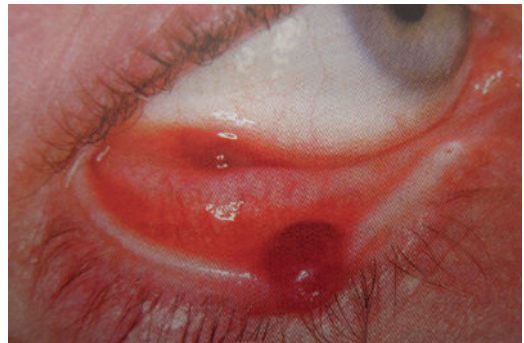**Kaposi sarcoma** occurs in 25% of AIDS patients. Prior to its association with aids, conjunctival Kaposi sarcoma was rarely reported.

Signs and symptoms: It may develop on eyelids, eyelid margins, conjunctiva and, rarely, within the orbit. Appears as a bright red subconjunctival lesion. Early lesions may be mistaken for subconjunctival hemorrhages. Secondary subconjunctival hemorrhages occasionally occur in association with Kaposi sarcoma. The tumor itself never regresses spontaneously. It slowly spreads subconjunctivally but rarely interferes



*Karposi sarcoma*

*Kaposi: Austrian pathologist, sarcoma: often highly malignant tumor, sarkos = flesh*



*Kaposi sarcoma most frequently develops in the inferior fornix of the conjunctiva.*

*Unless the lower lid is pulled down during examination lesions can be missed. Therefore the conjunctiva of any patient with AIDS should be inspected.*



with vision or eyelid function.

On the other hand, eyelid sarcomas can lead to complications. They appear as purple-red nodules, similar in appearance to cutaneous lesions elsewhere on the body. When lesions involve the eyelids they can result in oedema, entropion formation and trichiasis.

Treatment: systemic treatment of Kaposi sarcoma can lead to the remission of the disease.

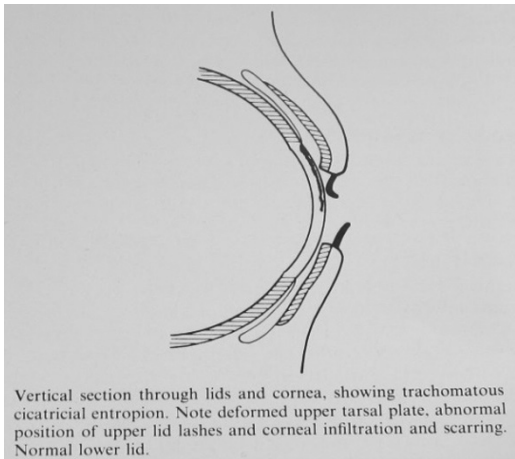
### TRICHIASIS AND ENTROPION

Trichiasis (trix =hair): a condition caused by distortion of the cilia (=eye lashes), so that they are directed backwards and rub against the cornea.

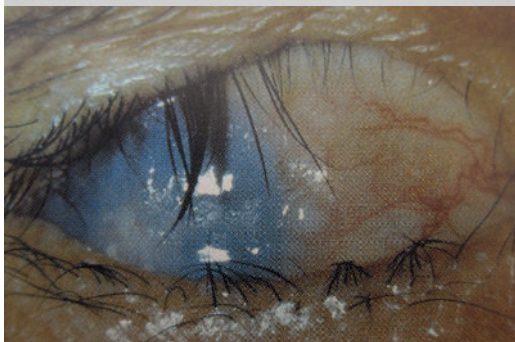Is caused by distortion (=the change in the normal position) of eyelashes and entropion (=inturning of the lid margin).

Symptoms and signs: those of a foreign body in the eye: irritation, pain, conjunctival hyperemia, lacrimation (=the secretion and discharge of tears) and reflex blepharospasm (=tonic spasm of the orbicularis oculi muscle), producing more or less closure of the eyelids.

Treatment: Isolated misdirected cilia can be



Vertical section through lids and cornea, showing trachomatous cicatricial entropion. Note deformed upper tarsal plate, abnormal position of upper lid lashes and corneal infiltration and scarring. Normal lower lid.

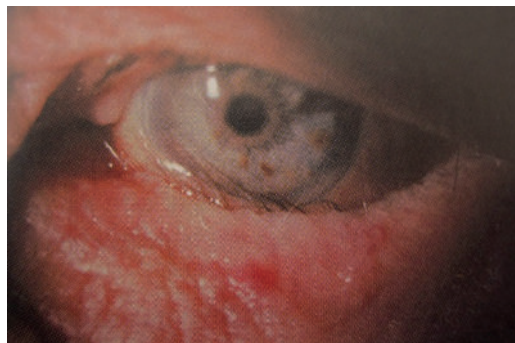


removed by epilation. This must be repeated. Destruction by diathermy is preferable. Excision of a small tuft of ingrowing eyelashes is an alternative to diathermy.

Cutting of the lashes is useless as it makes the eyelash sharper and more dangerous.

### ENTROPION

Etiology: often it is the end-result of a **long-standing trachoma** infection. It is most frequent in middle age. Scarring of the tarsal surface of the upper lid and its subsequent contraction produces a cicatricial entropion.



*Entropion (en = in, tropein = to turn) is an in-turning of the lid margin. It is the commonest lid anomaly in Africa. In the past it was a world-wide condition, related to poor hygienic circumstances.*

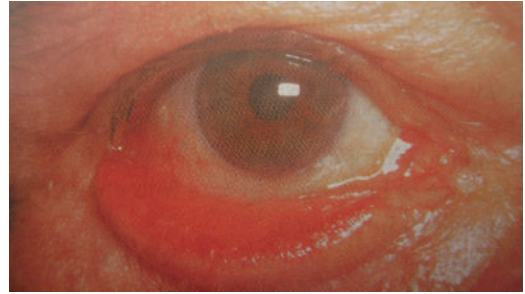
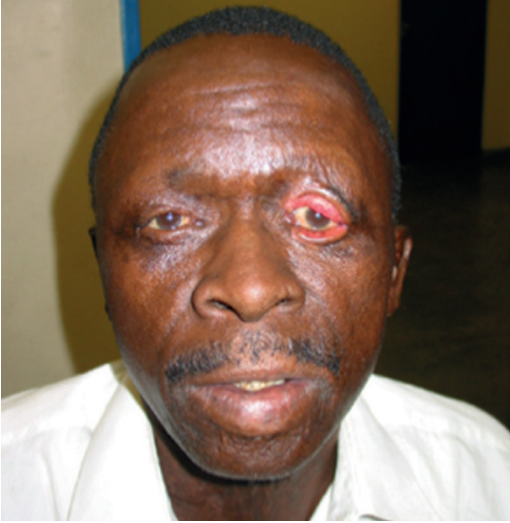Senile entropion, also called atonic entropion, occurs in the lower lid in aged patients. The connective tissue in the lid stretches. When the orbicularis oculi muscle contracts, the lower lid rolls in. Therefore it is also called spastic entropion. Senile entropion is rare in African patients, but is occasionally seen among aged immigrants.

Entropion can also be the result of tight bandaging following a surgical operation, which of course is harmful.

If the entropion is untreated, the inturned lashes damage the cornea, leading to ulceration and scarring of the cornea. There is usually an associated muco-purulent secretion.

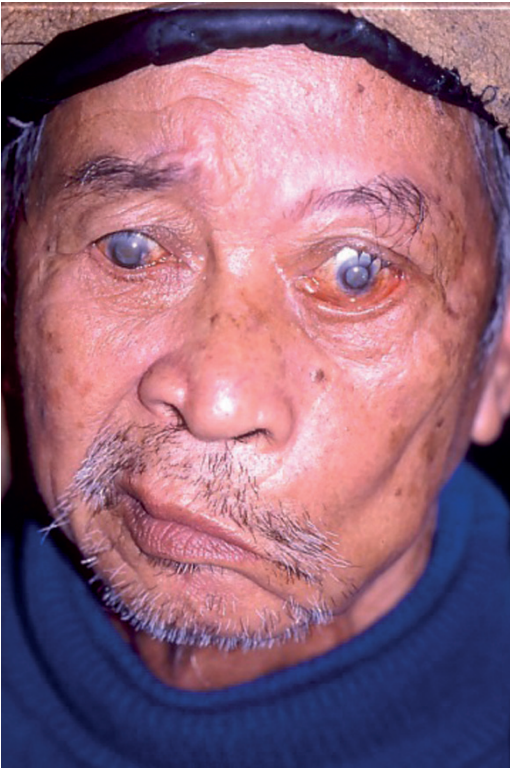Treatment: surgical correction. The surgical correction of upperlid entropion is very important because most of trachoma blindness can be prevented by early surgery.

The correction of senile entropion and trichiasis decreases discomfort and prevents loss of vision.



*Senile ectropion is due to relaxation of the tissues and laxity of the orbicularis muscle in the elderly. Only the lower lid is affected. The chief symptom is tearing (=epiphora), since the lacrimal punctum is not in close apposition to the eyeball and thus tear drainage is hindered. Secondary chronic conjunctivitis can occur.*

*Cicatricial ectropion results from burns or injuries of the face as well as in Herpes zoster infection.*



*Paralytic ectropion results from paralysis of the orbicularis muscle as is seen in leprosy or in Bell's palsy (=facial paralysis due to lesion of the facial nerve, n. VII).*

## ECTROPION

Ectropion is the out-turning of the eye lid. (ek = out)

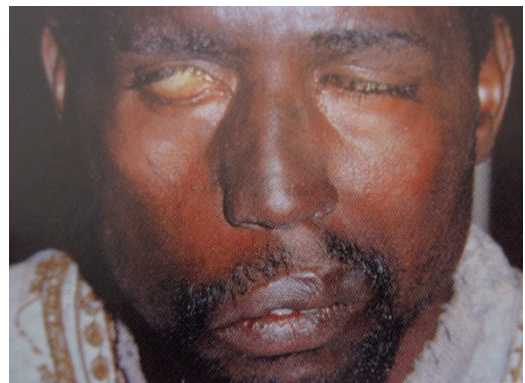Causes may be cicatricial, paralytic or senile.

Treatment: A slight ectropion is merely an annoying phenomenon. Severe ectropion however may lead to **exposure keratitis and corneal ulcer**, due to drying of the ocular surface. The latter requires eyelid surgery.

## LAGOPHTHALMUS

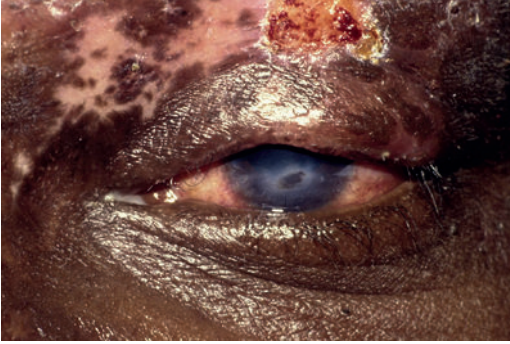
(Lagos = a hare. Hares were supposed to sleep with open eyes.)

Etiology: it may be due to paralysis of the facial nerve, to ectropion, but also to proptosis (= forward displacement of the eye = exophthalmus),



*Lagophthalmus is the condition of incomplete closure of the eyelids when the attempt is made to shut the eyes.*





*Eyes that are insufficiently covered by the lids are in danger. With failure of lid function the cornea remains exposed and the tear film dries. Owing to the drying, the epithelium casts off, leading to infection and ulceration, a condition called exposure keratitis or keratitis e lagophthalmo.*

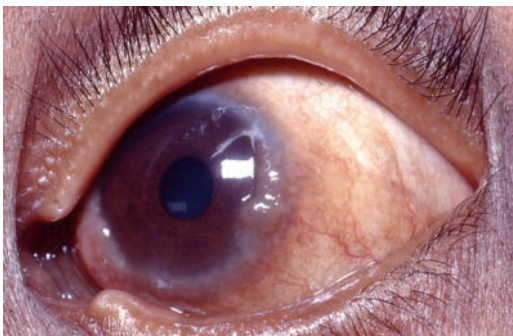
in exophthalmic goitre; also to orbital tumor, or to absence of blinking in people who are in coma or very ill, like in children with measles! Be aware of lagophthalmus in leprosy too. Treatment: consists in preventing drying of the cornea. In short-term cases antibiotic eye ointment or tear substitutes should be used to keep the cornea clear. Mothers of very ill children should be told that the eyes should be closed as much as possible to prevent drying. Surgery (tarsorrhaphy= the operation of suturing together a portion of or closing entirely the palpebral fissure) will restore adequate eye cover for the cornea in expected long-term cases.

#### VERNAL LIMBO-CONJUNCTIVITIS

( = **limbo-conjonctivite tropicale** in franco-phone Africa)

(Vernal, from latin vernum = springtime; however: no spring in tropical countries.)

Most common in children between 3 and 16. A



*pigmented hypertrophy at the limbus*

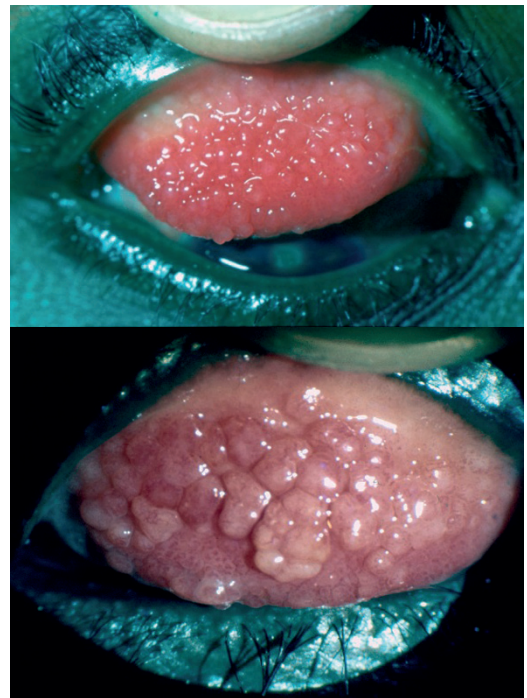
young adult may be susceptible too.

Etiology: the disease is of allergic origin. The specific allergen is not known.

Symptoms and signs: are bilateral, may be seasonal and may persist throughout the year. Itching and irritation, with increased viscous mucus in the tears.

Thickening of the conjunctivae with hypertrophy around the cornea at the limbus and papillae on the innerside of the upper eye lids. This is combined with pigmentation of the limbus and conjunctiva, giving the tissues around the limbus a brownish appearance. The border between cornea and white sclera, so remarkable sharp in healthy young eyes, is not distinct anymore but rather vague and blurred. Note: brownish pigmentation around the limbus is also seen in children with vitamin A deficiency.

After eversion of the eyelid papillae on the upper tarsal conjunctiva are visible. They become larger and may join together to produce giant papillae:



Sometimes the cornea is affected, starting with punctate keratitis that can be complicated by a corneal ulcer, as showed in the upper picture. Mostly the ulcer remains shallow and can heal with the right treatment, leaving a scar with

thin vessels.

Treatment: cromoglycate drops 4 times a day prevent the release of histamine and other toxins of the mast cells. If it is used regularly it will prevent the symptoms becoming too severe. It has the big advantage of having few side effects.

More effective in serious cases is local steroid drops under good supervision, e.g. prednisolone 4 times a day for 1-2 week; followed by twice daily, to maintain the relief. ( J. Sandfort-Smith: "Many patients find that by using cromoglycate they can either reduce or even stop any local steroid treatment".)

Vernal limbo-conjunctivitis demands patience and good care.

#### REFERENCES:

1. Sandfort-Smith J. Eye Diseases in hot climates, Butterworth- Heinemann, Oxford
2. Schwab L. Pratique de l'Ophthalmologie avec des ressources limitées, Arnette, Paris, France
3. Eyelid surgery: well described in Eye Surgery in Hot Climates by John Stanford Smith and David Hughes, F.A.Thorpe Limited.
4. Enquires to International Centre of Eye Health, Institute of Ophthalmology, 11-43 Bath street, London ECV9EL, England.

# THE SHIFT IN POTENTIALLY BLINDING EYE DISEASE BEFORE AND DURING THE AIDS PANDEMIC IN CAMEROON

H.C.KOPPERT, OPHTHALMOLOGIST, NETHERLANDS TROPICAL COURSE, AMSTERDAM; THE NETHERLANDS SOCIETY FOR TROPICAL MEDICINE AND INTERNATIONAL HEALTH

“Leave your clinical impressions in the cloakroom”. This I learned at the DTM&H course in Liverpool. Facts, numbers, statistics are of importance. However, to illustrate what happened to eye diseases in tropical environment, I will compare my clinical impressions in the seventies, before the AIDS-era, as general tropical doctor in Cameroon, with impressions in the present time as ophthalmologist in the same region.

In 1970, when I started as general practitioner in the hospital of Ndoungué - in the south-western part of Cameroon- only one ophthalmologist was active in the country. This meant that general tropical doctors had to cope with eye diseases. After a short and intensive period of training at the Rotterdam Eye Hospital and equipped with basic optic instruments, I was able to examine and treat eyes. A growing number of eye patients found their way to Ndoungué, located in a region hyperendemic for onchocerciasis, also called river blindness in cases where eyes are involved. Onchocerciasis is caused by the parasite *Onchocerca volvulus*, a nematode worm that is spread by the bite of an infected *Simulium* fly. The fly needs rivers for its life cycle.

In 1976 skin snips taken at the outer canthus of the eye, to detect the microfilariae (larvae) of the *O. volvulus*, were positive in 458 out of 4832 eye patients (10,5%) (1). The density of the microfilariae escaping from the skin snip at the outer canthus of the eye correlates with ocular involvement (2). Nowadays onchocerciasis in Cameroon is decreasing, due to the annual treatment with ivermectin supported by the African Program of Onchocerciasis Control (APOC).

In the seventies measles and malnutrition were also serious public health problems in Cameroon. In 1976, 49 children with severe keratomalacia (necrosis of the cornea in measles) were hospitalised in Ndoungué(1).

Due to the successful measles immunisation corneal blindness in children is no longer a public health problem. The same is true for malnutrition, in the seventies not a rare finding but thanks to under-five clinics and nutrition education it has disappeared largely.

In 1978, after returning to the Netherlands I specialised in ophthalmology. Regular visits to Cameroon and Tanzania, keep me involved in tropical ophthalmology.

During recent visits to the Manna Eye Clinic in Nkongsamba, nearby Ndoungué, I rarely observe ocular signs of onchocerciasis in young people. Skin snips in this clinic are no longer done, due to the risk of HIV transmission.

*Nevertheless, I recently saw an 18 years old man who had optic neuritis in both eyes and many microfilariae in the anterior chambers. He came from a region where annual ivermectin distribution is active. He must have missed his treatment.*

*On the other hand: In 1978, in Mangamba, a nearby village, nearly all the children in the 10-12 age group had a form of ocular onchocerciasis (3). Now there was a ten years old boy from Mangamba who didn't have any sign of onchocerciasis in skin or eyes: at present this village is involved in onchocerciasis control activities.*

Success in onchocerciasis control is obvious, but elderly people with ocular scars in the cornea and retina will still visit eye clinics, also in the regions declared free from *O. volvulus* transmission.

Nowadays it is remarkable to see the number of patients with intraocular inflammation, notably uveitis.

*In October 2013 at the Manna Eye Clinic the number of uveitis cases during 8 days were registered, new cases and controls. In this short period 470 eye patients were examined, among them 235 new patients; 29 of the new patients had uveitis; 12 were female, 17 male, age between 20-75 years. One of the severe uveitis patients,*

a man of 36 years, was receiving antiretroviral therapy and could be a case of Immune Recovery Uveitis (4). (see article *Immune Recovery Uveitis*, Meenken and others. p.25.) The HIV status of other new patients was not known. This observation of 29 new uveitis patients among 235 new patients -12%- during 8 working days in 2013 may represent an increase compared with the 6% of new patients who had uveitis in the same region in 1976 (1).

Another observation is that in the pre-HIV era of the seventies in Ndoungué examination of the fundus of the eye (retina, choroid and optic nerve) was rarely obscured by opacities in the vitreous. But at present fundus examination in the same region is quite often hindered by dense vitreous opacities caused by vitritis associated with uveitis and possibly also with AIDS and opportunistic infections.

In her thesis "Uveitis in Africa" (1996), M. Ronday (5) postulates that intraocular inflammation should be added to the list of principal causes leading to blindness on the WHO Eye Examination Record used in blindness surveys. HIV/AIDS, opportunistic eye infections and immune recovery uveitis are not mentioned in blindness surveys in the analysis of causes of vision loss world wide 1990-2010 by RRA Bourne (6). They must be hidden in the sector "undetermined": in West, Central and Southern Africa about 35% of the causes of blindness(6).

At times in the Manna Eye Clinic a patient, not yet aware of being infected with HIV, asks for medical care because of eye complaints. Equally eye patients are not always open about

having AIDS. In a busy clinic a trustworthy person should talk with the patient alone in a confidential setting to emphasize the need for HIV testing and for regular medication and controls. In resource-poor circumstances of low income countries the training of physicians, nurses and laboratory personal in order to create a multidisciplinary approach of ocular disease in AIDS, will be extremely difficult. A step forward would be the easy availability of a quick and reliable HIV-test adapted to simple circumstances. Moreover it is of great value to increase the awareness and the knowledge of blinding uveitis and possible AIDS involvement in eye pathology among physicians and nurses confronted with eye complaints.

Conclusion: during the last three decades the main causes of blindness as measured in population-based surveys may not have changed due to HIV/AIDS, but the pathology presented to the ophthalmologist in eye clinics in South West Cameroon certainly has.

#### REFERENCES:

1. Koppert HC Ogen in het ziekenhuis van N'Doungué, Kameroen. Ned.T.Geneesk. 1978 122 1148-1149
2. Fuglsang H Anderson J The concentration of microfilariae in the skin near the eye as a simple measure of the severity of onchocerciasis in a community and as a indicator of danger to the eye. Tropenmed Parasit 1977 28 63-64
3. Koppert HC Hellems AC Schoolchildren and ocular onchocerciasis in the rain forest of Cameroon Documenta Ophthalmologica 1986 61 211-217
4. Van den Horn GJ Meenken C. Ocular disease during HAART-induced immune reconstitution Tijdschr Infect 2009 4 3-10
5. Ronday MJH et al. Blindness from uveitis in a hospital population in Sierra Leone West Africa British Journal of Ophthalmology 1994 78 690-693
6. Bourne RRA et al. A systematic analysis of causes of vision loss world wide, 1990-2010. Lancet Glob Health 2013 1 e339-49

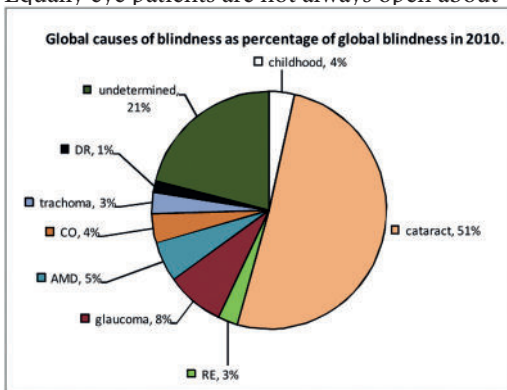


Fig. 1 S.P. Mariotti, WHO  
DR: diabetic retinopathy, CO: corneal opacities, AMD: age related macular degeneration, RE: refractive error



# TRACHOMA

DANNY HADDAD, MD, DIRECTOR INTERNATIONAL TRACHOMA INITIATIVE 2009-2013  
EMORY EYE CENTER, ATLANTA, GA, USA

## INTRODUCTION

Trachoma is the leading infectious cause of blindness in the world. It is caused by an infection of *Chlamydia trachomatis* of the conjunctiva with the upper eyelid being mostly affected. The active infection starts in young children, with repeated infections ultimately leading to scar tissue on the inner side of the eyelid, making the eyelid turn inwards (entropion) and the eyelashes touching the cornea (trichiasis).

The history of trachoma is very old, with evidence in Egypt going back more than 3,500 years. It was introduced in Europe through Napoleon's troops coming back from war in Egypt. In most of Europe and in the US it caused much blindness. In the late 19th and early 20th century, all immigrants to the US were screened for trachoma at Ellis Island, resulting in many immigrants being deported.

## EPIDEMIOLOGY

Nowadays, trachoma is a disease of poverty, being mostly prevalent in poor communities in dry, dusty environments with poor hygiene and overcrowding. Transmission of the bacteria takes place through the eye and nasal discharge. Current estimates of the World Health Organisation (WHO) are that there are 53 countries that are endemic for trachoma with 230 million people living in trachoma endemic areas and 21 million affected by active disease, with 2.2 million people visually impaired out of whom 1.2 million are irreversibly blind. An additional 7.3 million people have trichiasis and are at risk of developing blindness. (1)

In 2011 the trachoma atlas ([www.trachomaatlas.org](http://www.trachomaatlas.org)), an open access site that shows district prevalence level in programmatic grouping, was developed to assist in programmatic decision-making. (2) This tool shows all available prevalence data on trachoma.

## CLINICAL PICTURE

The clinical picture of trachoma depends on the duration, severity and degree of re-infection with the chlamydial agent. The acute phase, with an acute purulent conjunctivitis, is especially seen in young children with a peak from the third to the fifth years of life. The inflammation is usually bilateral and is most pronounced in the superior tarsal conjunctiva and over the superior part of the globe. It begins with redness and swelling of the conjunctiva and papillae. Later, follicles will appear (Fig.1).

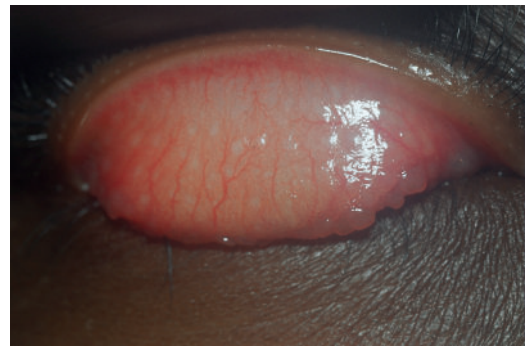

Fig. 1 TF. Trachomatous inflammation - Follicular

These are small yellow-white round or bean-shaped globes that are located deeply in the conjunctiva. They consist of a concentration of plasma cells. The presence of follicles is related to an active chlamydial infection. They are predominantly found in the superior tarsal conjunctiva. Chlamydial infection of the corneal epithelium can cause blood vessels to grow over the superior cornea (pannus). Small scars can develop there. Following a longer period of inflammation, scars may slowly develop in the superior tarsal conjunctiva.

Severe scarring of the tarsal conjunctiva causes the retraction of the tarsal plate leading to an inward rotation of the eyelid (entropion) and eyelashes touching the eyeball (trichiasis).



This causes chronic irritation of the cornea, which results in ulceration, bacterial superinfection and scarring of the cornea. Entropion/trichiasis and corneal scars are three times more prevalent in women than in men. This is most likely caused by women having a higher likelihood of reinfections, as they are the primary caretakers of children.

## DIAGNOSIS

There have been several different grading schemes developed for trachoma. In 1987, the WHO developed the simplified grading scheme for trachoma, allowing for a rapid assessment of prevalence and severity of disease within a population. The simplified system was designed to be performed by non-specialists (e.g. eye nurses).<sup>(3)</sup> This grading system is now in use by most programmes for population-based surveys. It focuses on the presence or absence of five key clinical signs of the disease, each of the signs needing to be scored independently. The assessment is performed with using a 2.5x loupe and with good light (daylight or torch).

1. Trachomatous inflammation - Follicular (TF): there are five or more follicles in the upper tarsal conjunctiva (follicles must be at least 0.5 mm in diameter) (fig. 1).
2. Trachomatous inflammation - Intense (TI): pronounced inflammatory thickening on the tarsal conjunctiva that obscures half of the normal deep tarsal vessels.
3. Trachomatous Scarring (TS): the presence of easily visible scars in the tarsal conjunctiva (fig. 2).

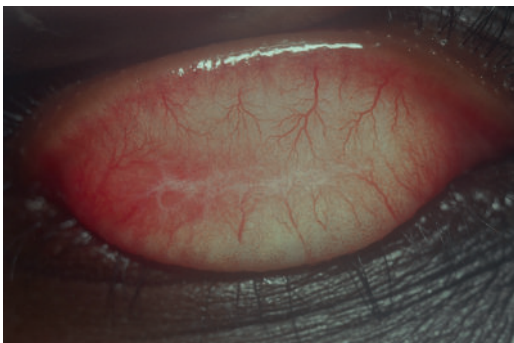


Fig. 2 Trachomatous Scarring (TS)

4. Trachomatous Trichiasis (TT): at least one eyelash rubs on the eyeball (Fig. 3). Evidence of recent removal of inturned eyelashes is also graded as trichiasis.

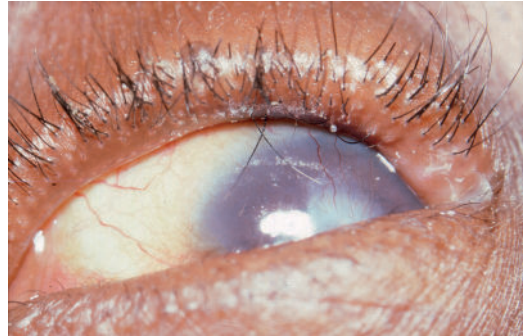


Fig 3 Trachomatous Scarring (TS)

Also corneal scarring present.

Corneal Opacity (CO): white spot with vessels growing in due to the irritation of the eyelashes.

5. Corneal Opacity (CO): the easily visible corneal opacity present over the pupil.

With trachoma being a clinical diagnosis, there is currently no place for laboratory diagnosis in the field. Laboratory techniques are available for detection of *C. trachomatis*, but these are either expensive, time consuming or require specialised equipment.

## TREATMENT

The World Health Organisation's Global Alliance for the Elimination of Blinding Trachoma by the year 2020 (GET 2020) is well on target to eliminate blindness from trachoma as a disease of public health importance. Since trachoma is a disease that impacts larger geographical areas, the global goals are set to the district level:

1. To reduce TF in children 1-9 years to <5% at district level.
2. To reduce TT in population to less than 1 per 1000.<sup>(4)</sup>

The WHO endorsed strategy is the so called SAFE strategy, where the S stands for surgery, the A for antibiotic distribution, the F for facial cleanliness and the E for environmental improvements.

## SURGERY

The treatment of entropion and trichiasis is performed through surgical procedure. The WHO recommends programmes that are establishing new trichiasis surgical services to use the Bilamellar Tarsal Rotation Procedure (BTRP). Since people with trichiasis are at risk of becoming blind, trichiasis surgery is an essential part of

the prevention of blindness from trachoma.(5) Recurrence rates within the first three years of surgery remain high and have been reported between 8-60%, with factors including the severity of trichiasis and surgical skills. The WHO is recommending the treatment with a single dose of azithromycin post-surgery to reduce the recurrence rate.

The WHO reported 160,000 surgeries performed in the year 2012. With an estimated 7.3 million backlog the number of surgeries will need to be increased drastically in order to reach the GET 2020 goal.

Epilation of eyelashes that are touching the cornea is a customary practice in many communities. The challenge is usually the quality of the forceps used. A trial showed that, with using high quality forceps and good training in epilation technique, two-year outcomes with patients with minor TT found no difference in CO, compared to lid surgery. (6)

#### ANTIBIOTICS

The mass drug administration (MDA) of antibiotics to complete districts has as goal to treat and prevent the infection by reducing the reservoir and reduce transmission of the bacteria. The WHO recommendation is to provide districts with a baseline prevalence of more than 10% TF in children 1-9 years with an annual single dose of azithromycin (20mg/kg up to 1g). Current recommendations are that in districts with a baseline prevalence of TF in children 1-9 years between 10 – 29% treatment continues for three years before implementing an impact assessment and if baseline prevalence of TF is above 30% to continue for five years. The target coverage of the district population should be 100%. For children less the 6 months of age, treatment should be with tetracycline eye ointment twice per day for six weeks. In case azithromycin is not available, individual patients should also be treated with tetracycline 1% eye ointment twice daily for 6 weeks. The use of azithromycin in pregnant women has shown to have a positive birth outcome, but the decision to include pregnant women lies with the national ministry of health.

The azithromycin for the prevention of blinding trachoma is being donated by Pfizer Inc. though the International Trachoma Initiative. During the year 2012 over 48 million people have been

treated in 23 countries.

#### FACIAL CLEANLINESS AND ENVIRONMENTAL CHANGE

The definition of a clean face for trachoma is the absence of ocular and nasal discharge. A dirty face is in many studies associated with trachoma. A clean face reduces transmission and is less attractive to flies. The F&E components focus on education of the importance of facial cleanliness, improved access to water and use of latrines, as the fly involved in transmission, the *Musca sorbens*, breeds predominantly in human faeces, but not in latrines.

Most of the western world has been able to rid trachoma by improvements in hygiene and sanitation. Trachoma prides itself of being one of the few diseases that actually have a comprehensive strategy in place that includes these elements. Over the past year much progress has been made to increase the collaboration with the water and sanitation sector to ensure a multi-sectorial approach to trachoma. A major challenge with the F&E components is that it requires behaviour change, which usually requires time. However, without the changes to the environment, it remains questionable if we will be able to make a lasting impact on the elimination of blinding trachoma.

#### DISCUSSION

With only seven years left to reach the goal of elimination of blinding trachoma by the year 2020, there is a need for a more concerted effort to reach this goal. With the need for at least five years of intervention in the high endemic areas, 2015 will be the last year that these areas should be starting their implementation in order to be able to complete the cycle. In 2011, the International Coalition for Trachoma Control (ICTC), a coalition of organisations committed to trachoma control, developed a global roadmap: 2020 INSight, the end in sight.

(<http://www.trachomacoalition.org/node/713>). This document lays out the actions to take and the milestones to meet in order to achieve the global elimination of blinding trachoma by the year 2020. National ministries of health will need to be empowered to take charge of the elimination of blinding trachoma in their countries. However, non-governmental organisations play a crucial role in the funding, technical assistance and innovation to reach

these goals. The ICTC has developed several documents that describe preferred practices, building on the experiences of well-established programmes. (7)

One of the main challenges identified in 2020 INSight was the lack of completion of baseline prevalence surveys, in order to understand where implementation is necessary or not. In order to address this, The Global Mapping for Trachoma Project, funded through a grant from the UK Department of International Development (DFID), has developed standardised training methods and an android based recording system to enable the completion of baseline prevalence surveys by March 2015.

Recently, many organisations and donors have supported integration of interventions with other Neglected Tropical Diseases (NTDs), especially those that have a similar MDA component, like onchocerciasis and lymphatic filariasis. Through the support of the US Agency for International Development (USAID), integrated NTD programmes made it possible to scale up the azithromycin distribution.

Major support has been received from DFID and the Queens Diamond Jubilee Trust to implement the full SAFE strategy in priority countries. This provides the ICTC the opportunity to scale up support to national programmes to reach their goals. This major scale up will require expansion to many new districts where developing the capacity to implement quality will be essential. The documents produced on preferred practice will help tremendously for these new programmes, to put us on the path to elimination by the year 2020.

## REFERENCES:

1. World Health Organization. Weekly Epidemiological Record (WER) 2013. Available from: <http://www.who.int/entity/wer/2013/wer8824.pdf>. Smith JL, Flueckiger RM, Hooper PJ, Polack S, Cromwell EA, Palmer SL, Emerson
2. PM, Mabey DC, Solomon AW, Haddad D, Brooker SJ. The geographical distribution and burden of trachoma in Africa. *PLoS Negl Trop Dis*. 2013 Aug 8;7(8):e2359.
3. Thylefors B, Dawson CR, Jones BR, West SK, Taylor HR. A simple system for the assessment of trachoma and its complications. *Bull World Health Organ*. 1987;65:477-83.
4. World Health Organization. Report of the 3rd Global Scientific meeting on trachoma elimination Baltimore, USA2010 [cited 2013 August]. Available from: <http://www.who.int/blindness/publications/3RDGLOBALSCIENTIFICMEETINGONTRACHOMA.pdf>.
5. DVD on trachoma surgery: <https://www.iceh.org.uk/display/WEB/ICEH+Publications+List#ICEHPublicationsList-CDs%26DVDs> <http://www.talcuk.org/videos-and-dvds/trachomatous-trichiasis-surgery-training-dvd.htm> [http://www.trachomacoalition.org/sites/default/files/uploads/resources/Moshi\\_TTSWR\\_English\\_2013.4.19.pdf](http://www.trachomacoalition.org/sites/default/files/uploads/resources/Moshi_TTSWR_English_2013.4.19.pdf)
6. Epilation for trachomatous trichiasis and the risk of corneal opacification. Authors: Rajak SN, Habtamu E, Weiss HA, Bedri A, Gebre T, Genet A, Khaw PT, Bailey RL, Mabey DC, Gilbert CE, Emerson PM, Burton MJ. *Ophthalmology*. 2012 Jan;119(1):84-9. Epub 2011 Oct 5.
7. [http://www.trachomacoalition.org/sites/default/files/uploads/resources/ICTC\\_MDAToolkitEN.pdf](http://www.trachomacoalition.org/sites/default/files/uploads/resources/ICTC_MDAToolkitEN.pdf)

# TRAUMATIC EYE LESIONS

JAN S. STILMA, EMERITUS PROFESSOR OPHTHALMOLOGY; HONORARY CONSULTANT  
SIERRA LEONE; EX ZIMBABWE, SIERRA LEONE, CAMEROON

JAN GEERT BOLLEMEIJER MD, OPHTHALMOLOGIST, ROTTERDAM EYE HOSPITAL,  
FORMERLY ZIMBABWE

Traumatic Eye Lesions (TELs) do not appear at the top of the list of causes of blindness, as most TELs are unilateral. TELs are responsible, however, for a considerable proportion of disability and they often affect young working people. Eye problems due to accidents occur more frequently in low income countries due to the high level of manual labour in the field or forest, the absence of protective eye glasses and a lack of industrial safety measures. Limited developed primary and secondary health care system are responsible for a delay in treatment.

## CAUSES OF TEL'S ARE

- Mechanical: blunt trauma due to branches, a fist or a stick; sharp injury (i.e. glass from a car's front windshield, knife wounds or landmine accidents, thorns);
- Chemical: strong detergents; acid from car batteries;
- Thermal: burns from fire; scalding by hot water or oil; lava;
- Electric: contact with broken high voltage cables;
- Radiation: X-ray exposure, welding torch exposure; direct sun and snow exposure; defective nuclear power installations;
- Fire work trauma in the Middle East and Asia.

## CLASSIFICATION

Kuhn et al introduced a classified system of eye injuries in 1996. (1) They distinguish the following traumatic eye lesions:

Closed globe: (blunt injuries)

1. Contusion,
2. Lamellar laceration.

Open globe:

1. Rupture (injury by a blunt object),
2. Penetrating injury (simple wound),
3. Perforation (double wound front and rear),
4. Intraocular foreign body.

## EPIDEMIOLOGY

The statistics concerning TELs often reflect cases that are presented to eye clinics. They therefore do not reflect the true incidence of TELs.(2) Bizarre cases are reported (i.e. a fish hook through an eyelid and a screwdriver through the eye.). A complete review of the impact of TELs in the world is provided by the WHO .(3)

TELs are the cause of disability at an incidence rate of 900/1.000.000; in 400/1.000 they lead to a clinical intervention and in 13/100.000 to a hospital admission. Children are affected too. (4)

## CLINICAL PICTURE

Small TELs present with the triad of pain, photophobia and tears. For example a corneal abrasion. Large TELs show, apart from the above named triad, impaired vision, a distorted pupil and blood around the eye. The intra ocular presence of a foreign body should be suspected when there is a history of the use of a hammer and chisel, hammer on stone, the use of steel wire and following landmine explosion.

## DIAGNOSIS

The investigation of the eye is made easier with the use of a drop of local anaesthetic, a good source of light and a magnifying glass or an ophthalmoscope.

## BLINDNESS

Blindness can occur following bilateral injury, as is the case in mine explosions, fire and chemical accidents. Sympathetic ophthalmia, an inflammatory reaction of the healthy eye following an injury of the other eye, occurs more often if the initial trauma is not well treated; this often occurs in developing countries where early suturing and appropriate antibiotics are often not available.

## TREATMENT

The treatment of eye injuries in low income countries does not really differ from what is done in The Netherlands. One can refer to standard textbooks for this subject.

Chemical injuries must be treated on the spot by rinsing with lots of water for at least 15 minutes prior to referral to a clinic.

## PROGNOSIS

The outcome of an eye injury is usually less favourable in developing countries due to:

- Delay in treatment of the injury; a simple rice grain on the cornea can develop into an ulcer and hypopyon within a couple of days. A sharp penetration of the eye can lead to endophthalmitis with loss of the eye. The risk of endophthalmitis in the Netherlands following an operation for cataract is 0.1%; for a sharp injury in low income countries the risk is 5-10%.
- Penetrating injury by organic material; this occurs more frequently in low income countries and often results in fierce infections.
- Lack of preventative and protective measures; safety glasses are not used in risky work environments (stone quarries, cutting stones, [jobs often done by women]), the use of car safety belts and the absence of security glass in cars.
- Firework injuries; these are responsible for 5% of penetrating eye injuries in the United States; figures from low income are lacking.
- The shortage of eye doctors, which decreases the chances of obtaining appropriate treatment in case of acute eye problems. In Africa, there is on average 1 eye doctor for 500.000 people; in The Netherlands this figure is 1:30.000.

## PREVENTION

Educating nurses and village health workers in the prevention of eye injury and the early treatment of small and larger injuries, by utilizing

topical antibiotics, can result in fewer serious and permanent injuries. The use of anaesthetic eye drops is very helpful for the removal of small foreign bodies. Often someone in the village is already skilled in the removal of a foreign body with the help of a cotton wool swab, a piece of cigarette paper or a soft piece of material. Nurses can be taught to remove a foreign body using a wet cotton wool swab, sterile needle or another instrument. Timely recognition of a perforation of the cornea may result in earlier presentation at the hospital for surgical repair. Education concerning the use of car safety belts can be promoted: i.e. don't drive unless all those in the car are in safety belts. The (mis-)use of alcohol, a common cause of injury, should be actively prevented. International and national actions against the use of landmines should be supported. Fireworks should only be used when there is expert supervision. The best prevention of ocular fire work trauma is the installation of restrictive laws on personal use of fireworks in combination with firework presented by professionals.<sup>(5)</sup> The Dutch and European Ophthalmological Society are in favour of this strategy.

## REFERENCES

1. Kuhn FA, Morris R, Witherspoon D, Heimann K, Jeffers JB, Treister G. A standardized classification of ocular trauma. *Ophthalmology* 1996; 103:240-3
2. Negrel AD. An approach to the epidemiology of eye injuries. In: GJ Johnson. *The epidemiology of eye injuries*. 1998
3. Negrel AD, Thylefors B. The global impact of trauma. *Ophthalmology epidemiology* 1998; 5:143-69
4. Ilhan HD, Bilgin AB, Cetinkaya A, Unal M, Yuçel I. Epidemiological and clinical features of paediatric open globe injuries in southwestern Turkey. *Int J Ophthalmol*. 2013 Dec 18;6(6):855-60. doi: 10.3980/j.issn.2222-3959.2013.06.20.
5. Wisse RPL, Bijlsma WR, Stilma JS Ocular firework trauma: a systematic review on incidence, severity, outcome and prevention. *Br J Ophthalmol* 2010;94:1586e1591. doi:10.1136/bjo.2009.168419



# TUMOURS OF THE BULBAR CONJUNCTIVA

JAN GEERT BOLLEMEIJER MD, OPHTHALMOLOGIST, ROTTERDAM EYE HOSPITAL, FORMERLY ZIMBABWE

Irregular lesions and tumours of the bulbar conjunctiva are extremely common in the tropics. They are specially present in the interpalpebral bulbar conjunctiva.

Accurate identification of the lesion and if necessary prompt treatment has become more important now than ever with the spreading of the AIDS pandemic. In this short overview only the characteristics of the pinguecula, the pterygium and the HIV associated conjunctival neoplasm will be discussed in detail. Congenital tumours like limbal dermoid and dermolipoma, the vitamin A deficiency associated Bitot spots and rare tumours of one of the conjunctival elements are not discussed here.

## PINGUECULA AND PTERYGIUM.

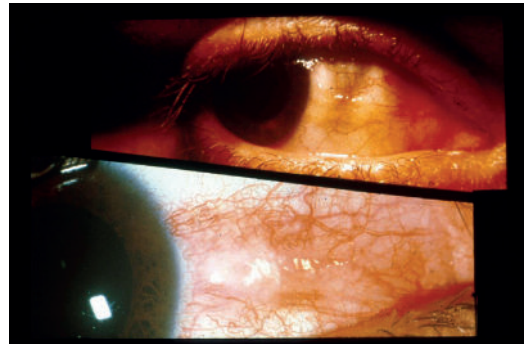
A pinguecula appears as a slightly raised, cream coloured or white irregularity of the conjunctiva in the interpalpebral fissure adjacent to the limbus. It never involves the cornea.(fig.1)

Contrary to a pinguecula a pterygium is a triangular shaped fibrovascular extension of bulbar conjunctiva onto the cornea in the interpalpebral fissure (fig. 2). It has a smooth surface. The visible bloodvessels are parallelly arranged and point to the apex of the triangle.

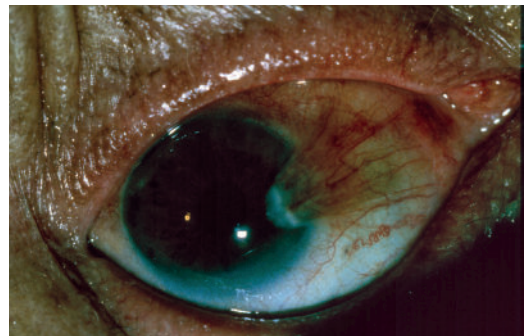
Both pinguecula and pterygium consist of elastotic degeneration of the deeper conjunctival layers. Their position in the interpalpebral fissure suggests a strong relation to high ultraviolet light exposure and chronic irritation from environmental factors. Both lesions are extremely common especially in the equatorial regions.

A pinguecula usually does not cause any complaints, but it may become inflamed in which case the lesion is heavily injected and may cause a lot of irritation (pingueculitis).

The pterygium may be quiet for years or progress slowly to the centre of the cornea. In the latter case it interferes with vision as it ob-



*Fig. 1 Pinguecula  
It is at the 3 or/and 9 o' clock position*



*Fig. 2 Pterygium  
Grows over the cornea*

scures the visual axis and induces astigmatism. For this reasons a growing pterygium should be surgically removed before visual acuity is affected. Combining excision with a form of conjunctiva plasty is mandatory because recurrences occur in up to 40 % of cases when only a bare sclera technique is used.

In case of an irritated pinguecula or pterygium treatment consists of protection of the eye with (sun) glasses and application of artificial tears and a mild vasoconstrictor. In severe cases a mild topical steroid and/or nonsteroidal anti-inflammatory medication may be applied for a short time.

## CARCINOMA IN SITU AND SQUAMOUS CELL CARCINOMA

The HIV pandemic has strongly influenced the pattern of diseases seen in developing countries. Well known is the early manifestation of skin disorders like seborrhoeic dermatitis and herpes zoster in HIV infected but otherwise apparently healthy individuals. In later stages of the disease wasting, chronic diarrhoea and fever dominate the clinical picture and opportunistic infections such as tuberculosis, cerebral toxoplasmosis and cryptococcal meningitis appear. Oncogenic human herpes virus type 8 is now known to be the cause of Kaposi sarcoma. KS and HIV-related lymphoma can be found in the orbital region. Less well known and documented is the strong rise in the incidence of carcinoma in situ and squamous cell carcinoma of the conjunctiva in relatively young HIV-infected Africans aged 20-50 years. A causal relationship with human papilloma virus infection (as in cervical neoplasia) in these tumours is suspected but as yet not proven. Interestingly, the tumour is occurring commonly in Africa, but not in Asia.

Like the pinguecula and the pterygium the slightly elevated lesion always starts in the interpalpebral fissure on the nasal or temporal side of the cornea at the limbus. The first signs are usually hyper- and parakeratosis, which give the lesion a somewhat dry and pearly or foamy appearance. Pigmentation may vary. The tumour grows rather rapidly and usually one or more feeder vessels on the conjunctiva can be noticed. Because of the speed of growth the relatively young patient is usually worried and seeks medical advice. (see article *Eye Diseases in HIV/AIDS*, JG Bollemeijer. p. 2.)

Complete excision is indicated preferably with application of cryotherapy. In early stages removal of the tumour from the cornea and conjunctiva is easy as in this stage it does not penetrate Bowman's membrane and the sclera, but with delayed treatment local recurrences appear within a few months. Metastasis to the pre-auricular and submental lymphnodes may occur.

## OTHER CONJUNCTIVAL TUMOURS

The cells of the conjunctival epithelium, the connective tissue, bloodvessels, nerves and melanocytes can all form different types of tumours. Most of them are rare or very rare. They may be congenital or acquired. Some tumours

are an entity on their own like naevi or a foreign body granuloma, some tumours are part of a disease which has affected tissue elsewhere as well like a phlyctena associated with TB or a granuloma in vernal conjunctivitis. Careful history taking and examination should lead to the right diagnosis and treatment.

If there is still any doubt about the diagnosis the tumour might be excised and send in for histology.

## REFERENCES

1. Wills Eye Hospital
2. Lewallen S, Courtright P, HIV and AIDS in the eye in developing countries, Arch Ophthalmol, vol 15, Oct 1997, 1291-95
3. Ateenyi-Agaba C, Conjunctival squamous-cell carcinoma associated with HIV infection in Kampala, Uganda, Lancet vol 345, march 18, 1995 695-96.
4. Fogla R, Biswas ), Krishna Kumar S, et al, Squamous cell carcinoma of the conjunctiva as initial presenting sign in a patient with acquired immunodeficiency syndrome (AIDS) due to human immunodeficiency virus type-2, Eye, Apr 14, 2000, 246-7
5. Chisi SK, Kollmann MK, Karimurio J. Conjunctival squamous cell carcinoma in patients with human immunodeficiency virus infection seen at two hospitals in Kenya. East Afr Med J. 2006;83: 267-270

# VISION 2020, THE RIGHT TO SIGHT: WHAT CAN A GENERAL MEDICAL OFFICER DO?

MARGREET HOGEWEG, OPHTHALMOLOGIST,

CBM S.E.ASIA MEDICAL ADVISOR; PREVIOUSLY DEP. OPHTHALMOLOGY LEIDEN UNIVERSITY.

This article focuses on what a general medical officer can contribute to VISION 2020 in a low-income country.

VISION 2020: the Right to Sight initiative, was launched in 1999 by the eye care INGO's, and endorsed by WHO. The ultimate goal is that by the year 2020 all "avoidable blindness" will be eliminated, through prevention or treatment. 20/20 stands for full visual acuity of 6/6 or 1,0.

The action plan has four essential pillars:

- Intervention strategies for most common eye conditions that cause avoidable blindness;
- Human resource development with emphasis on mid-level eye care personnel;
- Adequate supply of infrastructure, equipment and instruments;
- Advocacy

The following five eye conditions were selected as priorities:

- Cataract;
- Trachoma;
- Onchocerciasis;
- Childhood blindness;
- Refractive errors and Low Vision.

These conditions are essentially bilateral and can be successfully and cost-effectively prevented or treated. Glaucoma and diabetic retinopathy are not on the priority list, because these are more difficult to diagnose and to treat, especially in less developed countries. Trauma, although often resulting in blindness in the affected eye, is not on the list either, because most traumas are unilateral and therefore do not cause blindness in a person.

## **CATARACT**

Every survey shows that about 50% of all blind-

ness is due to age-related cataract. Surgery for cataract is one of the most successful medical interventions. It can rehabilitate an elderly blind person or secure jobs for people with early cataract in just 30 minutes surgery time.

What you can do:

Visit the nearest facility for cataract surgery, get to know the conditions and costs of surgery and make arrangements.

There are two options. Firstly, a team can visit regularly as part of their outreach work and take patients with them for surgery at their base. This removes the important barrier of long travelling for the elderly. Secondly, surgery can be done as an "eye camp" at your hospital. The team will usually carry all necessary equipment, consumables and IOLs, so that you only have to offer an examination room, OT, sterilization, beds for 1-2 nights, some laboratory facilities, and some supporting staff. Depending on the population in your area, the capacity of your hospital and the capacity of the surgical team, a visit once or twice/year may be sufficient. Best are fixed timings, taking the farming seasons and local festivities into account. The criteria for patient selection are to be discussed with the surgical team. Good publicity through various channels is of utmost importance. Follow-up will usually be done through your hospital. It is important to monitor the outcome of cataract surgery: WHO suggests as one of the guidelines after six weeks: an uncorrected poor outcome (VA of  $< 0.1$  ( $< 6/60$ ) in  $< 5\%$  of the operated eyes with age related cataract. Poor outcome under field conditions is in reality often 10-15% but should not be higher.

Cost of surgery may be subsidized through Service Clubs, such as Lions, local business people or philanthropists. Sometimes the surgical team has funding, or the health insurance will



Fig. 1 Eyecamp Nepal

pay. Some contribution by the patient should be encouraged.

As cataract develops slowly and patients gradually get used to impaired vision, they will not present at the OPD by themselves, so the problem of cataract blindness is underestimated. However, after good publicity, the attendance for a cataract surgical camp can be overwhelming.

In health education programmes, do give attention to "painless and gradual loss of vision in the elderly", as surveys show that, in remote areas, many elderly blind and their relatives are not aware that cataract blindness can be "cured". Display posters with pictures of happily smiling patients after cataract surgery.

Ideally you should have a small eye clinic with a trained eye nurse.

### TRACHOMA

Trachoma is common in the dry and dusty areas of Sub-Saharan Africa (SSA). The aim is to achieve elimination of blinding trachoma as a public health problem by 2020. The SAFE

strategy of Surgery, Antibiotics, Facial cleanliness and Environmental changes is driving this. In some countries mass azithromycin distribution and water and sanitation programmes are carried out through GET 2020 (Global Elimination of Blinding Trachoma). As a result, the numbers of new infections have considerably decreased. In absence of a mass distribution programme, individual patients, often young children, should be treated with tetracycline eye ointment, twice daily for 6 weeks.

Meanwhile, more patients with trichiasis, -eyelashes scratching on the cornea-, are identified. Trichiasis is the late result of repeated *Chlamydia* infections. Women are more affected than men.

In case of trichiasis / entropion there are two options:

1. Eyelid surgery, to evert the inwards-turned lashes and lid margin. This can be learned through the excellent surgery training DVD (English & French; through TALC) (1). Trained eye nurses often do trichiasis surgery.
2. Epilation of the eyelashes as soon as they are felt, either self or by a close family member



(2). This has to be done life-long! In areas where trichiasis is common, the tweezers are often locally made. Provided epilation is done well, it protects the cornea from scarring.

### ONCHOCERCIASIS

APOC (African Programme of Onchocerciasis Control) runs a successful programme ‘community directed treatment with ivermectin’ (CDTI), in oncho-affected regions. The number of people developing vision loss due to onchocerciasis has already markedly decreased. Community distributors, who hand out the ivermectin -once or twice /year-, can sometimes be involved in other interventions as well.

### CHILDHOOD BLINDNESS

In the past, corneal blindness was the main cause of blindness in children in poor countries. This was due to vitamin A deficiency, often triggered by measles, and made worse by traditional eye medicines. Wider coverage of measles vaccination, and better nutritional status, with/without high dose vitamin A mass distribution to under-fives, have greatly reduced corneal blindness. Main causes of blindness in children today are retinal diseases, often hereditary and untreatable, and congenital or developmental cataract.

Children with cataract should be referred as soon as they are diagnosed, preferably to a tertiary paediatric eye department, as treatment in children is much more complicated than in adults (see the article *Childhood blindness and vision loss in Africa* by Courtright p.8).

### REFRACTIVE ERRORS AND LOW VISION

Uncorrected refractive error (URE) is the most common cause of visual impairment worldwide. Do try to provide simple refraction and prescription of glasses. Studies show that children in rural areas, in SSA in particular, will have only few refractive errors (3). In Asia myopia is more common, especially in cities and among students from middle class families. School screening programmes are most effective if carried out among urban lower high school students (10-15 yrs).

However, there is often a high demand for reading glasses in people aged over 40 and sale of standard reading glasses may be a great service

and can also create some income to the hospital. Prescription goes by age, with a simple reading test (e.g. news paper or threading a needle). Guidelines for reading glasses:

|           |              |
|-----------|--------------|
| 40-45 yrs | S+ 1.25      |
| 45-50 yrs | S+ 1.5       |
| 50-55 yrs | S+ 2.0       |
| > 55 yrs  | S+ 2.5 – S+3 |

If there is a blind school nearby, be aware that often half of the children or more are not “blind” but rather “low vision”. Many students can greatly improve with proper refraction and strong reading glasses or loupes, in order to read print rather than Braille (see article LOW VISION CARE van Dijk).

**In 2013 The World Health Assembly (WHA) has passed a resolution that in 2019 visual impairment should have decreased by 25% from the baseline in 2010. Particular focus should be on cataract surgery and correction of refractive errors, as these constitute 75% of all visual impairment!**

In conclusion: at a local level

- 1) arranging cataract surgery,
- 2) providing antibiotic treatment and lid surgery for trachoma,
- 3) creating awareness to refer any blind or severely visually impaired child, whatever the cause, to a paediatric eye unit and,
- 4) providing a refractive service or at least standard reading glasses will contribute greatly to the success of VISION 2020.

With a torch, an ophthalmoscope, a vision chart and a trial lens set, you can diagnose and act on most of the VISION 2020 priority conditions.

### REFERENCES:

1. <http://www.talcuk.org/videos-and-dvds/trachomatous-trichiasis-surgery-training-dvd.htm> French: <http://www.talcuk.org/videos-and-dvds/dvd-de-formation-pour-chirurgie-du-trichiasis-trachomateux.htm>
2. Saul N. Rajak, PhD, MRCOphth, 1 Esmael Habtamu, BSc, 2 Helen A. Weiss, PhD, at al. Epilation for Trachomatous Trichiasis and the Risk of Corneal Opacification, *Ophthalmology* 2012;119:84–89 2012
3. Wedner S, Masanja H, Bowman R, Todd J, at al. Two strategies for correcting refractive errors in school students in



Tanzania: randomised comparison, with implications for screening programmes. *Br J Ophthalmol*. 2008 Jan;92(1):19-24.

**FURTHER READING:**

<http://www.cehjournal.org/changing-patterns-in-global-blindness-1988-2008/>  
<http://www.who.int/blindness/GLOBALDATAFINALfor-web.pdf>

# WHAT TO DO WITH A PATIENT WHO HAS EYE PROBLEMS?

FIRST OF ALL, YOU WILL TAKE A **HISTORY**

THERE ARE FIVE IMPORTANT QUESTIONS THAT YOU SHOULD ALWAYS ASK:

1. WHAT IS YOUR EYE **PROBLEM**?
2. **WHICH** EYE IS AFFECTED?
3. **WHEN** DID IT START?
4. IS THERE A HISTORY OF **INJURY**?
5. WHICH **MEDICINES** HAVE YOU USED?

AFTER THAT, YOU WILL DO YOUR **EXAMINATION**

THERE ARE FIVE IMPORTANT ITEMS THAT YOU SHOULD ALWAYS CHECK:

1. THE **VISION** MUST BE GOOD.
2. THE **CORNEA** MUST BE CLEAR.
3. THE **PUPIL** MUST BE BLACK.
4. THE **WHITE** MUST BE WHITE.
- 5.. THE **LIDS** MUST BE NORMAL.

ESSENTIAL TOOLS ARE A **VISUAL ACUITY CHART** AND A TORCH.

ON THE BASIS OF THE PATIENT'S **HISTORY** AND YOUR FINDINGS ON **EXAMINATION**

IT IS POSSIBLE TO DECIDE WHAT TO DO.

IN CASE THE EYES ARE **NORMAL**: **REASSURE** THE PATIENT.

IN CASE THE EYES HAVE A DISEASE THAT YOU CAN **DIAGNOSE**: **ACT** ACCORDINGLY.

IN CASE THE EYES HAVE A DISEASE THAT YOU **CANNOT** DIAGNOSE: **REFER**.

SHARPEN YOUR SKILLS AND BECOME A VALUABLE **PRIMARY EYE CARE** WORKER.

# XEROPHTHALMIA, MEASLES AND MALNUTRITION

NICO W.H.M. DEKKERS, OPHTHALMOLOGIST EX-KENYA, TANZANIA, VIETNAM

REVISION P. HARDUS, OPHTHALMOLOGIST

Due to successful vitamin A supplementation and measles immunization programmes in many countries, corneal blindness has reduced significantly. The content of the original article of Dekkers is still valid to explain the background and clinical signs of xerophthalmia. At the end of the article the actions which have helped to reduce this health problem are summarised.

## VITAMIN A DEFICIENCY, VAD

### *Physiology of Vitamin A*

Vitamin A belongs, together with K, D and E, to the fat-soluble vitamins. As a vitamin it is present in liver, eggs, and milk. The pro-vitamin, beta-carotene is abundant in vegetable food: yellow or red fruits, dark-green leafy vegetables and their products. A good example is the red palm oil that is in common use in West Africa. After restoration from the intestinal tract the vitamin A is bound to protein and transported to the liver. The amount of vitamin stored in the liver is normally sufficient for half a year.

### *Epidemiology of Vitamin A Deficiency, VAD*

The recommended daily uptake of retinol is 300-1200 micrograms. Even a moderately balanced diet contains this amount of vitamin A or the pro vitamin, so essentially every child should have a sufficient liver-store. Problems arise when the diet is insufficient. In childhood the most important reasons for this insufficiency are:

1. The quality is OK, but the quantity is insufficient.
2. The quality is not OK, e.g. breastfeeding by mothers having a vitamin A deficiency, highly diluted commercial milk products, maize only.
3. Increased demands due to rapid growth,

intercurrent infections. Measles is notorious in this respect. In older age groups the incidence of VAD can be significant when large groups of people have to share a single kitchen: prisons, orphanages, soup kitchens, refugee camps.

### *Signs and symptoms of Vitamin A deficiency*

Vitamin A plays an important role in the normal function of the retina, epithelium and in the defence mechanism against infections. Children with VAD have more, and more severe, infections. The same applies to children with a lack of iron and general malnutrition.

The eye-signs of VAD are designated as XN, X1A B, X2, X3A-B and XS, where X stands for xerophthalmia (Xeros =dry and Ophthalmia= eye disease). This subdivision in stages suggests a characteristic course of the disease, but a definite warning is needed here: severe, irreparable damage can occur very rapidly, without any previous signs of VAD.

### *XN Night blindness*

Healthy people use their dark-adaptation to adjust to the diminished quantity of light when it grows dark. This mechanism is absent in VAD. Children with XN cannot find their way after dusk sets in; they sit down in the corner of the hut. Night blindness as a spontaneous complaint is an important sign of VAD; however, keep the possibility of a retinitis pigmentosa in mind. When a population survey is done, night blindness is a very unreliable guide for the detection of VAD. Night blindness caused by VAD vanishes with a single dose of vitamin A.

### *X1A Xerosis of the conjunctiva*

Epithelium is by nature water-repellent, non wetttable. In order to make contact with tears an intermediate molecule is needed with both

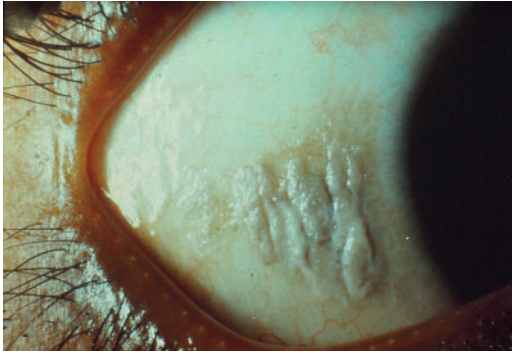


Fig. 1 X1B Bitot's spot

fatty and hydrophilic properties. This mucine is produced by the goblet cells in the conjunctiva. In VAD the production of mucine is diminished or absent and the eye will stay dry. This xerosis will vanish with a single dose of vitamin A.

The Bitot's spot (named after Bitot, doctor in a French orphanage, 1863) has a characteristic triangular form, with a foamy surface. The underground can be folded and pigmented. Bitot's spots are - especially in young children - characteristic for the presence of VAD and are therefore important indicators in epidemiological studies.

### X2, X3A, X3B Corneal involvement

VAD can also cause a xerosis of the corneal epithelium. This sign of VAD exists only for a very short time before corneal necrosis occurs. When this necrosis involves the whole thickness of the cornea a hole is formed, usually at the 6 o'clock position (fig. 2), but the whole cornea can melt away.

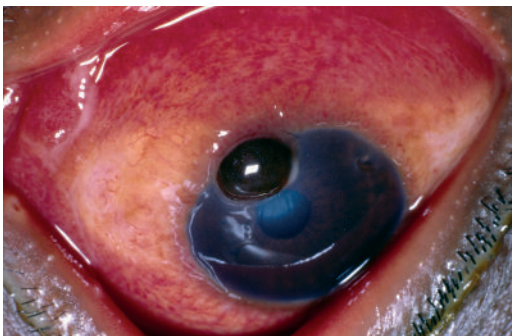


Fig 2. Iris prolapse due to melting of the cornea

(Small defects can be filled with the protruding iris, giving rise to a scar: the leucoma adhaerens). The function of the eye is usually diminished. When the total cornea melts away, the eye is lost due to extrusion of the contents of the eye and, usually, a subsequent infection: panophthalmia. The end result is a phthisis bulbi: a shrunken eye. When only the stroma of the cornea is lost, Descemet's membrane bulges out, giving rise to a descemetocoele; the eye is lost functionally.

Two circumstances have to be kept in mind: the later stages of VAD can occur very rapidly, without any warning signs. Moreover, corneal necrosis doesn't occur with VAD alone. Other factors need to be present: PEM, measles, exposure and traditional eye medicines.

### XS Corneal scarring

A leucoma adhaerens can occur after any perforation of the cornea (e.g. a puncture by sharp stick or thorn) and is in itself not proof of previous VAD. This means that epidemiological data based on XS need careful interpretation.

### Protein Energy Malnutrition, PEM

PEM occurs in two clinical forms. In marasmus the children are severely malnourished and underweight, vulnerable, apathetic and prone to infections; this is most probably due to lack of iron and vitamin A. The biochemical parameters (mainly proteins) are still normal. In the first stages of kwashiorkor ("the disease you get when your younger brother is born") the children may have a better prognosis but they are more open to infections and have severe biochemical disturbances. The prognosis is poor. Usually there is an acute reason for the transition from marasmus to kwashiorkor: weaning or an intercurrent infection. Measles is highly notorious in this respect.

### PEM and the cause of corneal necrosis

For several reasons PEM is involved in the occurrence of corneal necrosis:

1. Every type of malnutrition interferes with the absorption of vitamin A. In PEM there is always VAD.
2. Kwashiorkor in particular destabilises the structural proteins like collagen. The main constituent of the corneal stroma is collagen. In PEM the cornea is therefore far more vulnerable than in well-nourished children.

3. In severe malnutrition the immune defence mechanisms function at a low level. Malnourished children are therefore far more open to infections: measles! Moreover, the rash of measles is an immune phenomenon; in malnourished children the diagnosis measles can easily be missed due to the absence of the pathognomonic rash. However, these children do have all the possible viral (!) complications of measles.

### *Measles*

Measles is caused by infection with a paramyxovirus that is transported by droplets. The incubation time is 10-14 days. The disease starts with a "cold", coughing, fever, and general illness. After 3-4 days the fever drops and the outbreak of the characteristic rash occurs. In well-nourished children the disease runs a mild course, with only minimal morbidity and mortality.

In underprivileged conditions the situation is quite different. The disease occurs at a much younger age, the morbidity is much higher due to complications such as pneumonia and gastro-enteritis and the morbidity can be as high as 10% in a hospital population. An Arabic proverb states: count your children after the measles.

### *Measles and malnutrition*

It has been mentioned earlier: measles has a far higher morbidity and mortality in malnourished children. The reverse is also true: a measles infection is frequently the cause of the transition from marasmus into kwashiorkor. Measles and malnutrition go hand in hand.

### *Measles and the cornea*

Conjunctivitis is a common sign in the prodromal stage. More or less concomitant with the outbreak of the rash nearly all children with measles have a superficial, strictly epithelial, self-limiting viral keratitis. This keratitis as a sign of measles can last up to 10 days after the outbreak of the rash and explains the usual photophobia in children with measles. Corneal complications are caused by exposure, application of traditional eye medicines, malnutrition or- more commonly- a combination of these factors.

### *Exposure*

Severely ill children sometimes have problems with complete closure of the eyelids; a small slit of cornea is not covered and is continuously exposed to the surrounding air. At this place the cornea dries, an ulcer is formed and perforation follows. This process is not typical for children with measles, but can also occur in patients in an intensive care unit. In my opinion this is a possible explanation for the occurrence of the leucoma adhaerens in its usual 6 o'clock position.

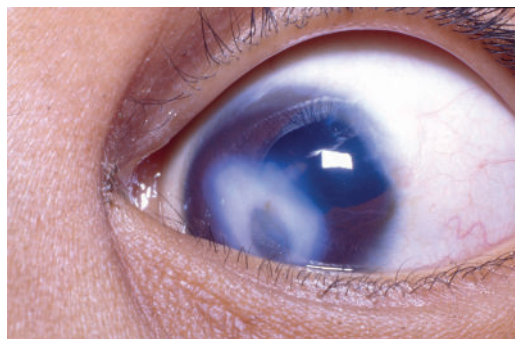
### *Traditional Eye Medicine, TEM*

1% of all children with measles become blind as a result of this disease. TEM contributes to this percentage. Occasionally these preparations are useful, but the majority of them do a lot of harm. This is caused by the material used (plants, powders, urine), the preparation (sterility, pH, concentration), contamination, the dosage and the method of application.

TEM can be quite corrosive and may harbour many bacteria, which are a source of collagenase. One should realise that these medicines are applied to a cornea which is already (very) vulnerable due to the possible presence of VAD, measles keratitis, exposure ulcer and - most important- a PEM weakened stromal collagen.

### *Improving vision*

When a corneal scar is in a central position (cause is not important) a part of the iris can be removed so that clear peripheral cornea can be



*Fig. 3 Optical iridectomy*

*Central corneal scar; iris removed so that clear cornea is used for peripheral seeing*

used for seeing: of course, this will not give a good vision but can improve independency of a patient greatly (fig 3).



### *What has helped to reduce this corneal blindness*

Ten key activities for primary health care workers (1)

1. Clean the eyes immediately after birth and instill topical antibiotic eye ointment or topical antiseptic eye drops.
2. Give the mother 200,000 international units (IU) of vitamin A immediately after delivery.
3. Promote breastfeeding and good nutrition.
4. Immunize children against measles at nine months and give vitamin A 100,000 IU. Encourage second immunization for extra protection.
5. Recommended treatment of children with any of the eye signs of vitamin A deficiency (2)

| Age of the child | Dose of vitamin A (IU) | Frequency               |
|------------------|------------------------|-------------------------|
| <6 months        | 50,000                 | Day 1, day 2 and day 14 |
| 6-12 months      | 100,000                | Day 1, day 2 and day 14 |
| >12 months       | 200,000                | Day 1, day 2 and day 14 |

IU = International units of retinyl palmitate

6. Keep children's faces clean.
7. Refer any child who cannot see well to an eye care worker as soon as possible.
8. Urgently refer any child with a white pupil or other obvious abnormality to an eye care worker.
9. Refer any child with a serious eye injury or a red eye to an eye care worker immediately.
10. Do not put traditional medicines in the eyes.

### REFERENCES

1. Chandna A, Gilbert C. When your eye patient is a child. *Comm. Eye Health* Vol. 23 No. 72 2010 pp 01 - 03. <http://www.cehjournal.org/article/when-your-eye-patient-is-a-child/>
2. *Comm Eye Health* Vol. 26 No. 84 2013. Published online 20 December, 2013 Do vitamin A deficiency and undernutrition still matter? 2013 <http://www.cehjournal.org/do-vitamin-a-deficiency-and-undernutrition-still-ma>

**We are grateful for the support of the Prof.Dr.H.J.M.Weve Stichting  
and Uitgeverij Luiten**

**Produced by Uitgeverij Luiten ([www.uitgeverijluiten.nl](http://www.uitgeverijluiten.nl))** 